

## Pyogenic granuloma: a rare case of an infantile intraoral lesion

Safak Karacay<sup>a</sup>, Işın Dogan Ekici<sup>b</sup>, Güler Ciler Erdag<sup>c</sup>, Sevgi Bilgen<sup>d</sup>, Selami Sozubir<sup>a</sup> and Ayca Vitrinel<sup>c</sup>

Pyogenic granuloma (PG) is a non-neoplastic inflammatory hyperplasia that may be encountered in any part of the body including the oral mucosa. The onset of symptoms is mostly observed at adolescence in children. In this presentation, the second youngest case of gingival PG in the literature is reported to provide an insight into early neonatal gingival masses, which may be a stress factor for both the parents and the physician. A 4-month-old male baby was referred to our clinic with the complaint of erythema and swelling at the upper gingival floor, which was first observed 2 months ago by his mother before his admission. At physical examination, a soft, hyperemic mucosal lesion was observed that protruded from the upper gingival floor. After the excision, granulomatous-type PG was diagnosed. The excision site healed and the postoperative period was uneventful. The gingiva is the most common intraoral site of PG as in our case,

### Introduction

Pyogenic granuloma (PG) is a non-neoplastic inflammatory hyperplasia that occurs in response to various stimuli such as chronic local irritation, trauma, hormonal alterations, bone marrow transplant, and graft reactions [1,2]. A case of an early lesion observed at infancy is reported.

### Case presentation

A 4-month-old male baby was referred to our clinic with the complaint of erythema and swelling at the gingival level, which was first encountered 2 months ago before his admission. He was followed up by a pediatrician for 2 months, but the mass continued to grow. There was no history of bleeding or difficulty in feeding and the patient was normal in terms of growth parameters. During physical examination, a soft, hyperemic mucosal lesion was observed that protruded from the upper gingival floor (Fig. 1).

The patient was prepared for an excisional biopsy after the examination, which indicated no additional problems. Routine blood count and other biochemical parameters were found to be normal. The mass was excised completely and the baby was taken to the postoperative room after bleeding was controlled. The specimen was a 1.5 × 1 × 0.5 cm, regular contoured smooth mass with a glistening surface. On histopathologic examination, closely packed blood vessels of capillary size with open lumens were detected within a collagen-rich matrix beneath an intact mucosal layer. The lumens of these capillaries contained erythrocytes and were lined with endothelial cells and pericytes in peripheral areas. Capillary lumens were dilated. Lobulated proliferation of capillaries with intervening fibrous septa was the basic histological pattern of this lesion (Figs 2 and 3). These fibrous septa and matrix were found to be collagen rich when stained

but this localization is specific for the older age group rather than in infants. Intraoral lesions of neonatal period are unfamiliar to the parents resulting in their anxiety. The PG is a benign lesion that can be healed completely, with good cosmetic results. *Ann Pediatr Surg* 8:93–94 © 2012 Annals of Pediatric Surgery.

*Annals of Pediatric Surgery* 2012, 8:93–94

**Keywords:** gingiva, infant, intraoral, pyogenic granuloma

Departments of <sup>a</sup>Pediatric Surgery and Pediatric Urology, <sup>b</sup>Pathology, <sup>c</sup>Pediatrics and <sup>d</sup>Anesthesia, Yeditepe University Faculty of Medicine, Istanbul, Turkey

Correspondence to Selami Sozubir, MD, Department of Pediatric Surgery and Pediatric Urology, Yeditepe University Faculty of Medicine, Istanbul, Turkey  
Tel: +90 216 578 4824; fax: +90 216 578 4959;  
e-mail: ssozubir@yeditepe.edu.tr

Received 13 August 2011 accepted 9 May 2012

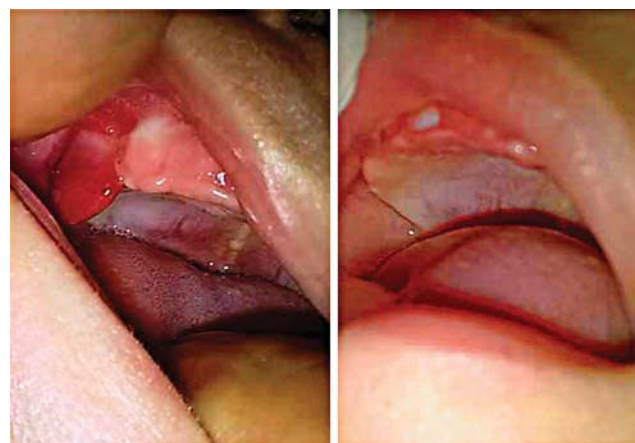
with Masson's trichrome stain. Granulomatous-type PG was diagnosed.

During the follow-up of 6 months, the infant continued to breastfeed well, with normal growth parameters. The excision site healed (Fig. 1) and the postoperative period was uneventful.

### Discussion

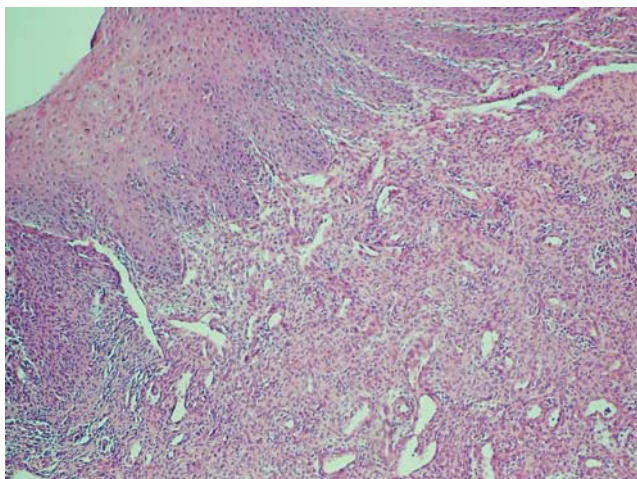
PG is a benign, acquired, vascular neoplasm of the skin and mucous membranes. PG, or the current histopathological name, lobular capillary hemangioma, occurs during infancy, typically as a single polypoid nodule that bleeds easily on palpation [1,2]. Lesions are divided histologically into

**Fig. 1**



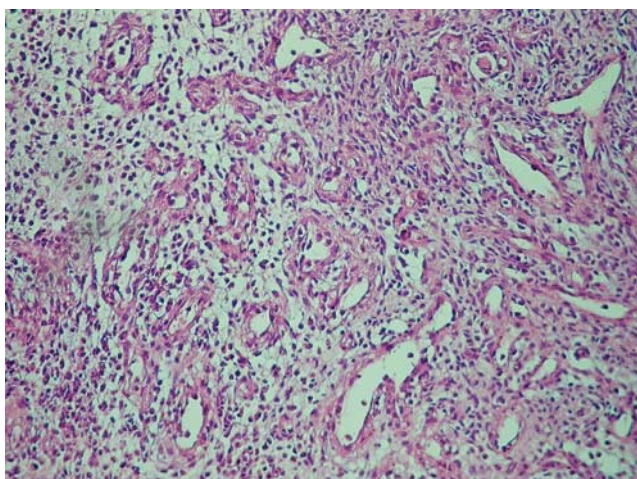
Hyperemic gingival mucosal lesion before operation and during postoperative follow-up of the base of excision and repair zone.

Fig. 2



In the submucosal area, closely packed blood vessels of capillary size with open lumens can be seen within a collagen-rich matrix beneath an intact mucosal layer composed of multilayered squamous cells (H&E, × 40). H&E, Hematoxylin and eosin.

Fig. 3



Lobulated proliferation of capillaries with intervening fibrous septa within a collagen-rich matrix (H&E, × 100). H&E, Hematoxylin and eosin.

three groups: granulomatous, fibromatous, and giant cell. It is usually painless, develops rapidly, and may range in size from a few millimeters to a few centimeters. It is currently believed that this lesion represents a benign neoplasm, a form of capillary hemangioma, rather than a reactive infectious or traumatic process [3]. PG has a diagnostic, lobular arrangement of capillaries at its base. The lobules are composed of discrete clusters of endothelial cells, and the lumina vary from indistinct to prominent. The surface of the lesion may undergo secondary, nonspecific changes that include stromal edema, capillary dilation, inflammation, and a granulation tissue reaction [3].

The gingiva is the most common intraoral site as in our case, but this localization is specific for the older age group rather than among infants. Among the intraoral PG-like lesions, hemangiomas are the most common soft tissue masses found in newborns, occurring in ~2% of

neonates and 10% of infants [4]. The most frequently encountered pediatric oral mucosal benign lesions are hemangiomas. They may appear singly or as multiple lesions, as in infantile hemangiomatosis.

Some may regress spontaneously; however, others may require removal by cryosurgery, sclerosing agents, or laser. Other gingival conditions that should be considered in the differential diagnosis are Epstein pearls, which consist of cystic lesions with stratified epithelium, viral enanthem presenting as vesicular masses, congenital epulis as pedunculated solid firm masses with lobulated surfaces, gingival cysts as nodular cystic lesions of the enamel organ, and reparative giant cell granuloma as a red-brown nodule with fibroblasts and giant cells [4,5]. In most of the lesions, conservative treatment results in spontaneous resolution, but PG and reparative giant cell granuloma require surgical excision. The correct differential diagnosis is necessary to reduce unnecessary additional examinations and invasive tests, and for the patient to receive the most effective and precise treatment in each case.

The treatment of PG is total excision or laser treatment, both of which produce good results. Although there are various reports indicating that laser treatment is a more esthetic and easy procedure in children, including both skin and mucosal PGs [5–9], we prefer excision because of both the effectiveness and the diagnostic benefits in gingival lesions. Despite the possible bleeding during the early postoperative period, which appears to be a minor complication, biopsy is the method of choice for the adequate diagnosis of oral lesions and complete cure with one intervention. In this case, an excisional biopsy was performed for the diagnosis and treatment.

## Conclusion

Intraoral lesions of neonatal period are unfamiliar to the parents resulting in their anxiety. Among these lesions, the intraoral PG is benign, for which complete healing can be achieved, with good cosmetic results with appropriate surgical treatment.

## Acknowledgements

### Conflicts of interest

There are no conflicts of interest.

## References

- Mueller BU, Mulliken JB. The infant with a vascular tumor. *Semin Perinatol* 1999; **23**:332–340.
- Isaacs H Jr. *Tumors of the fetus and newborn*. Philadelphia, PA: Saunders; 1997.
- Mills SE, Cooper PH, Fechner RE. Lobular capillary hemangioma: the underlying lesion of pyogenic granuloma. A study of 73 cases from the oral and nasal mucous membranes. *Am J Surg Pathol* 1980; **4**:471–479.
- Willies Jacobo LJ, Isaacs H Jr., Stein MT. Pyogenic granuloma presenting as a congenital epulis. *Arch Pediatr Adolesc Med* 2000; **154**:603–605.
- Umut AM, Yalçiner EG, İşin DA. Pyogenic granuloma (lobular capillary hemangioma) of the tongue. *Int J Pediatr Otorhinolaryngol* 2001; **58**:239–241.
- Sud AR, Tan ST. Pyogenic granuloma-treatment by shave-excision and/or pulsed-dye laser. *J Plast Reconstr Aesthet Surg* 2010; **63**:1364–1368.
- Raulin C, Petzoldt D, Werner S. Pyogenic granuloma: removal with the CO<sub>2</sub> laser. *Hautarzt* 1997; **48**:402–405.
- Tay YK, Weston WL, Morelli JG. Treatment of pyogenic granuloma in children with the flashlamp-pumped pulsed dye laser. *Pediatrics* 1997; **99**:368–370.
- Goldberg DJ, Sciales CW. Pyogenic granuloma in children: treatment with the flashlamp-pumped pulsed dye laser. *J Dermatol Surg Oncol* 1991; **17**:960–962.