

# Perinatal testicular torsion: literature review and local experience

Ibrahim Ashraf<sup>a</sup>, Ashraf H.M. Ibrahim<sup>b</sup>, Mohamed F. Bazeed<sup>c</sup>, Hamad A. Hader<sup>b</sup> and Ibrahim M. Abdul Raheem<sup>b</sup>

**Introduction** Perinatal testicular torsion includes intrauterine testicular torsion (IUTT) and postnatal testicular torsion (PTT). IUTT includes cases of vanished testis and testicular mass presenting at birth. Controversies exist regarding the need for urgent exploration and contralateral orchiopexy. The aim of this study is to review our local experience in the management of these cases.

**Patients and methods** From May 2000 to May 2010, all files of patients with perinatal testicular torsion and operated cases of undescended testes (UDT) were reviewed retrospectively.

**Results** Seven patients presented with a unilateral nonacute testicular mass at birth. Six of these patients required elective inguinal exploration and orchiectomy, whereas one was treated conservatively. All patients underwent urgent radiological investigations. None of the cases had synchronous or asynchronous contralateral involvement. Two patients with PTT presented acutely and required immediate bilateral scrotal exploration and testicular fixation without preoperative radiological investigations. Of 450 patients with UDT, there were 13 vanished testes (2.9%). Thirteen patients with torsion

of the undescended testes (TUDT) presented acutely and required immediate inguinal exploration. Most of the TUDT cases (85%) presented between 5 weeks and 6 months. None of them could be saved.

**Conclusion** Patients with IUTT did not present acutely, whereas patients with PTT presented acutely and required immediate bilateral scrotal exploration and fixation. The prognosis in TUDT is guarded and contralateral fixation was not practiced, except in a 5-week-old infant. Early orchiopexy at 3–6 months is recommended. Cooperation between surgeons, neonatologists, and parents is mandatory to avoid time delay. *Ann Pediatr Surg* 8:86–89 © 2012 Annals of Pediatric Surgery.

*Annals of Pediatric Surgery* 2012, 8:86–89

**Keywords:** intrauterine testicular torsion, postnatal testicular torsion, torsion of undescended testis

<sup>a</sup>Ain Shams University Hospitals, Cairo, Egypt, <sup>b</sup>Department of Pediatric Surgery and <sup>c</sup>Department of Radiology, Armed Forces Hospital Southern Region, Saudi Arabia

Correspondence to Ashraf H.M. Ibrahim, MD, FRCSI, Department of Pediatric Surgery, King Faisal Military City, PO Box 5062, Khams Mushait, Saudi Arabia  
Tel: +966 507 636 820; fax: +0096672511180; e-mail: ash\_ib@hotmail.com

Received 14 October 2011 accepted 27 April 2012

## Introduction

Testicular torsion is a serious disease that may result in anorchia and sterility. Neonatal testicular torsion is an incorrect nomenclature because torsion of the testis may occur prenatally and also beyond the age of 30 days [1]. Perinatal testicular torsion is a better term and includes prenatal or intrauterine testicular torsion (IUTT), postnatal testicular torsion (PTT), and torsion of the undescended testis (TUDT) [2]. These different categories have many controversial aspects of management that may affect the outcome. The aim of this retrospective study is to document the frequency, management, and outcomes of perinatal testicular torsion in Asir region, Saudi Arabia, over a 10-year period.

## Patients and methods

The authors reviewed files of the patients with IUTT who presented with a testicular mass at birth. Patients of IUTT presenting with vanished testes were identified by reviewing the files of operated cases of undescended testis (UDT) and proved by histopathology of the nubbin. The files of patients with PTT in cases with previously normal testes or cases with UDT were also reviewed. Files were reviewed for age, laterality, clinical picture, and investigations. The operative approach, operative findings, procedure, contralateral fixation, and outcomes were documented. To minimize the drawbacks of a retrospective

study, the senior surgeon (A.I.) followed a standardized management protocol throughout this study: patients with IUTT with no acute signs were to be subjected to Doppler ultrasound, elective exploration through an inguinal incision, and orchiectomy. No contralateral orchiopexy was to be performed unless the other side showed clinical and/or radiological involvement. Parents were to be instructed to examine the testis each time they changed the diaper. All patients of PTT with acute surgical signs underwent no radiological investigations and were subjected to immediate bilateral scrotal exploration and fixation. Patients with TUDT did not undergo trials of detorsion or manual reduction and no radiological investigations. All these patients were to be subjected to emergent inguinal exploration of the affected side with no contralateral orchiopexy, except if the patient was 6 weeks or younger.

## Results

There were seven patients presenting with a history of testicular mass at birth. Five of these were left sided and two were right sided. The age at presentation ranged from 7 days to 3 months (mean 22 days). All patients were full term and generally well. The testes were large, firm, and not tender, except one, which was firm, not tender, and smaller than the normal side (Fig. 1). Malignancy was a differential diagnosis. Doppler ultrasonography indicated absent blood flow and heterogeneity in the affected side

and normal findings in the contralateral side (Fig. 2). The smaller testis was treated conservatively and resulted in atrophy. The other six were subjected to orchiectomy after inguinal exploration. Histopathology showed a post-torsion state. None of the contralateral testes was fixed because there was no clinical or radiological involvement. The contralateral testes functioned normally for a follow-up period of 6 months to 9 years.

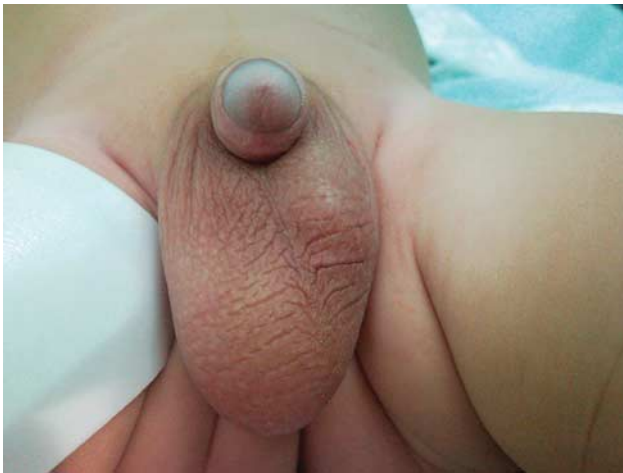Of 450 undescended testes, 13 (2.9%) were vanished. Eight were left sided and five were right sided. Six cases

were in the scrotum and seven were intracanalicular or abdominal. Histopathology of the nubbin confirmed the diagnosis of vanished testes in 12 cases. The remaining patient was diagnosed by laparoscopy.

Two patients with previously normal testes had PTT at 3 and 5 weeks of age. Patients were generally sick with an elevated, enlarged tender testis and discolored edematous overlying skin. Immediate bilateral scrotal exploration and fixation was performed without radiological investigations. Both patients had normal testes at 2 and 4 years, respectively.

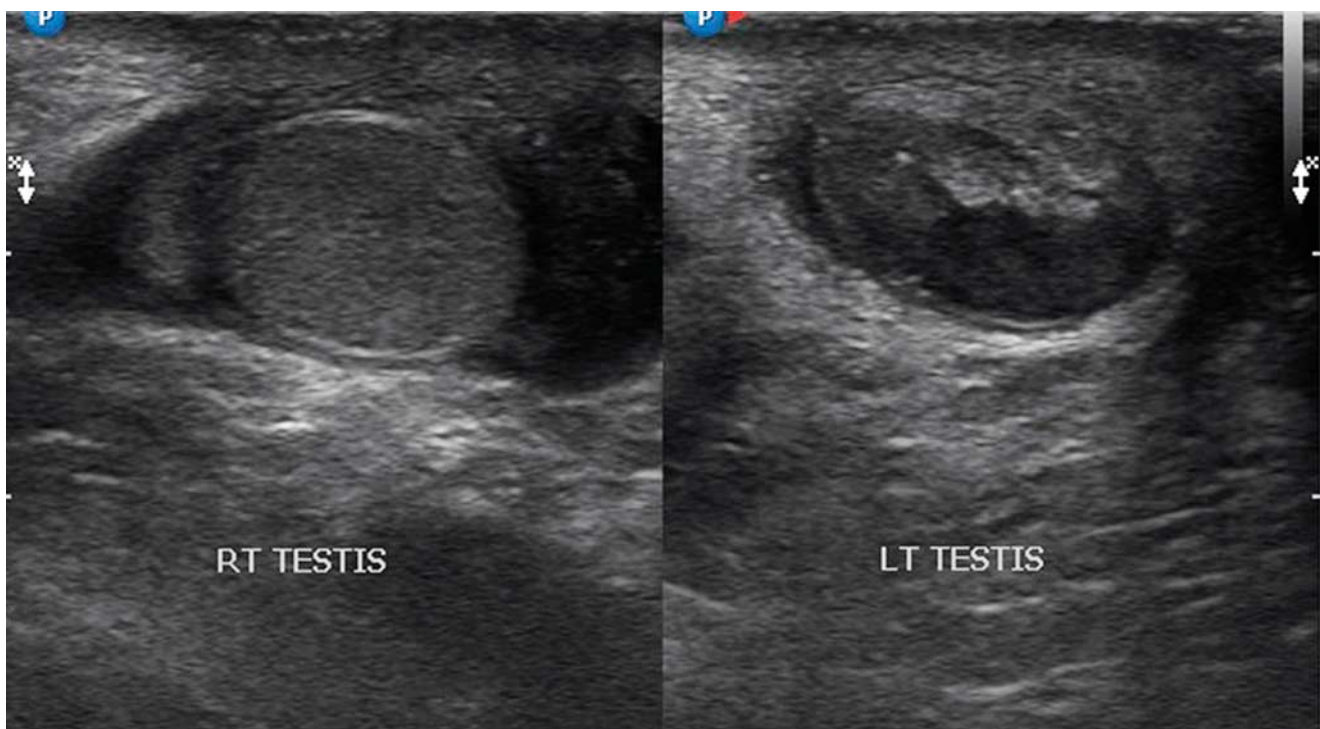
Of 450 patients with UDT, 13 patients (2.9%) underwent emergency surgery because of acute torsion of the UDT in the inguinal canal. Interestingly, this incidence is equal to that of the vanished testes. All patients had presented for the first time. Eleven patients had a history of empty hemiscrotum since birth. There was a time delay from 10 to 36 h. Most patients (11) presented between 5 weeks and 6 months (mean age 2 months). Ten cases were left sided and three were right sided. Generally, all patients were sick, with typical local signs of acute testicular torsion. Incarcerated inguinal hernia with the UDT was the main differential diagnosis. Manual reduction, detorsion, and radiological investigations were not performed. Immediate exploration through an inguinal incision was carried out. Contralateral fixation was performed only for patients who were younger than 6 weeks of age. All affected testes were found in the inguinal canal with extravaginal torsion (Fig. 3). Ten testes were frankly gangrenous and required orchiectomy. Three cases were of doubtful viability and had orchiopexy, but atrophy occurred in all of them subsequently. To date,

Fig. 1



Patient with intrauterine testicular torsion with painless mass in the left hemiscrotum.

Fig. 2



A patient with intrauterine testicular torsion, scrotal ultrasonography showed heterogeneity of left testis. Note that the other side is normally isogenic.

unfixed contralateral testes are normal after 1–9 years of follow-up.

## Discussion

The frequency of testicular torsion is considered to be bimodal, with one peak in the perinatal period and another at puberty [3]. Perinatal testicular torsion is a better term than neonatal torsion because torsion can occur prenatally and well beyond the age of 30 days [1]. Djahangirian *et al.* [4] have reported cases of neonatal torsion up to 6 months of age. Most cases of torsion of the UDT occur before 6 months of age [2]. In this study, 85% of cases of TUDT occurred between 5 weeks and 6 months (a mean of 2 months). It is, therefore, logical to include cases of TUDT in those of PTT. It is claimed that IUTT is more common than PTT (72–81 vs. 28–19%, respectively) [1,5]. This may not be true if we include TUDT in the postnatal period and vanished testes in the prenatal period. In this study, we had 13 cases of vanished testes and seven cases presenting with a mass at birth (a total of 20 cases with prenatal torsion). Postnatally, we had two cases with acute torsion of previously normal testes and 13 cases of TUDT (total of 15 cases). The precise incidence would be 57% for prenatal versus 43% for PTT.

Perinatal testicular torsion including that of the UDT is extravaginal [2,5]. The spermatic cord twists two to four times outside the tunica vaginalis. Complicated pregnancies and vaginal deliveries may predispose to IUTT [5]. Torsion occurs because of hypermobility and elasticity of the testicular tissue, which will only be fixed in the scrotum during the first several days of life [6]. It takes several weeks to be securely attached in the scrotum [7,8]. The UDT will never be fixed to the scrotum and will remain hypermobile and susceptible to torsion as long as it is not fixed surgically in the scrotum [2].

A new classification has been proposed. Perinatal testicular torsion includes IUTT (including vanished testes) and PTT (torsion of previously normal testes as well as

UDT). This classification is based on the time of presentation to determine the potential for testicular salvage. Antenatal ultrasonography is not sensitive for the detection of cases of vanished testes and those presenting with testicular mass at birth [9–11].

A vanished testis can be found in the scrotum (torsion of a normally descended testis), intracanalicular or abdominal (torsion of UDT). This is usually established by exploration and histopathological examination of the nubbin. In this study, 13 patients of 450 patients with UDT had unilateral vanished testes (2.9%). Six were scrotal in position and seven were intracanalicular or abdominal. None of these patients was subjected to contralateral orchiopexy, which is well accepted in the literature [10].

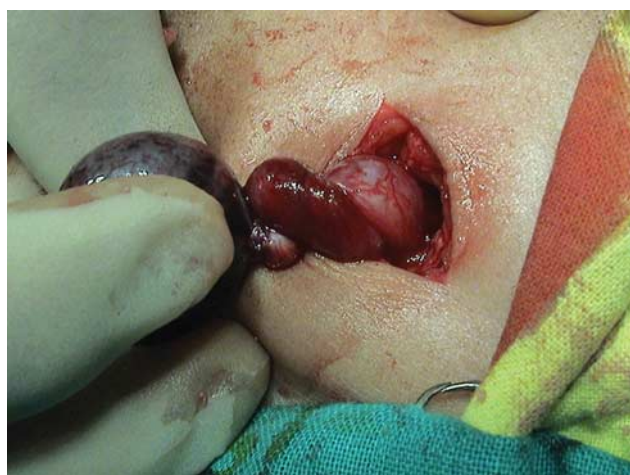IUTT presenting with a mass at birth is marked by minimal to no discomfort and highly localized findings. The affected testis is large, firm, and not tender. The affected hemiscrotum may be discolored, with no systemic symptoms or signs [1]. The diagnosis is confirmed by ultrasonography. The testis is heterogenous with a hypoechoic necrotic center and a hyperechoic thickened tunica albuginia with an associated reactive hydrocele [12]. Doppler enhancement shows disordered blood flow. Preoperative ultrasonography showing a heterogenous testis is universally predictive of organ loss and requires no emergent exploration. However, isogenicity with altered blood flow requires emergent operation [13]. In this study, the authors did not encounter this situation because emergent surgery without radiological investigations was performed under acute conditions. It is important to compare both sides as contralateral IUTT may not be evident clinically [14]. It may be difficult to exclude malignancy especially if the patient is not a neonate. Clinical and ultrasonographic distinction is difficult and exploration may be mandatory [1].

A few cases of IUTT are acute surgical emergencies if torsion occurs just before, during, or soon after delivery. There are acute local signs and Doppler ultrasonography, if done, shows isogenicity of the testis with altered blood flow [13,15]. There is an increasing trend for conservative management with gain of experience in nonacute cases and if the diagnosis is confirmed by Doppler ultrasonography [16]. The aim is to avoid the risks of anesthesia and operative complications [4].

In contrast to IUTT, postnatal torsions require emergent surgery. A salvageable rate of 40–50% has been reported [4,17]. In our study, the two cases could be saved after emergent bilateral scrotal exploration without any investigations. Bilateral scrotal exploration was performed because both patients were younger than 6 weeks of age with weak testicular attachment to the scrotum.

Torsion of an UDT presents with symptoms and signs of acute abdomen with a tender mass in the inguinal region and an empty ipsilateral hemiscrotum. Color Doppler ultrasonography has been claimed to be the best imaging modality as it can assess the anatomy as well as the blood flow to the testes [18]. The authors believe that

Fig. 3



A case of extravaginal testicular torsion showing twist of the spermatic cord.

radiologic investigations in TUDT are difficult to perform because of the small size of the gonads, which lie independently in the inguinal canal. Hence, these investigations were considered unnecessary [2,17]. The differential diagnosis of TUDT is mainly strangulated inguinal hernia. The differentiation between these two conditions is difficult and unnecessary. Manual reduction or detorsion plays no role. Immediate inguinal exploration of the affected testis is mandatory. Contralateral orchiopexy is performed only if the patient is 6 weeks of age or younger [2]. In this study, unfixed contralateral testes remain normal after 1–9 years of follow-up. However, the outcome of the affected testis is poor [2,19].

The time of presentation may be the greatest determinant of success to salvage the testis. Our patients presented with a time delay of 10–36 h, with a salvage rate of 0%. However, TUDT, unlike cases of IUTT, remain salvageable if there is full cooperation and understanding between neonatologists, surgeons, and parents to avoid time delay and to improve the outcomes. Also, orchiopexy can be performed safely and effectively in patients as young as 2 months of age [2,20]. Therefore, earlier orchiopexy at 3–6 months is advised to improve the outcomes of TUDT. However, this will not nullify the risk of loss of the gonad if torsion occurs before the recommended age.

Recently, there has been a long debate on observation versus prompt surgical exploration in cases of perinatal torsion [10,21]. It was our policy in this study not to operate emergently on cases of IUTT with no acute signs. We are aware that in the literature, there are cases of IUTT who presented acutely [13,15]. However, we did not encounter this problem. If there is acute pain on touching the hemiscrotum with overlying edema and erythema, immediate bilateral exploration and fixation is justified [10]. In our institution, no preoperative radiological investigations are required. However, for nonacute cases, elective inguinal exploration was performed simply because radiological investigations could not exclude malignancy. In one case, we were able to rule out malignancy confidently because the testis was already showing atrophy. Retrospectively, and with counseling with the parents, we could have treated all the patients conservatively with close observation, again, to avoid anesthetic and operative risks. Medicolegal legal concerns should never drive clinical medicine [10].

The incidence of bilateral perinatal testicular torsion ranges between 5 and 22% [4,14]. Some investigators, including us, believe that the incidence is on the lower side [10,22]. Fortunately, we did not encounter any patient with bilateral involvement. For cases with synchronous bilateral involvement with no acute signs, urgent radiological evaluation is mandatory. Contralateral involvement may be discovered with no clinical evidence. In any case, whether synchronous or asynchronous, acute signs require immediate surgical exploration. Extravaginal torsion can occur asynchronously up to the age of 6 weeks. Parents are advised to examine the scrotum at each diaper change [10]. In the present study, however, we fixed the contralateral testis if the patient presented acutely, requiring emergent surgery, and if the patient was 6 weeks of age or younger.

## Conclusion

Cases of TUDT were included with those of PTT because 85% of them occurred between 5 weeks and 6 months. This addition altered the incidence to 57% for IUTT versus 47% for PTT. Most cases of IUTT present at birth with a nontender testicular mass. Radiological evaluation is essential. It seems that there is a significant role for conservative management if malignancy can be excluded. The authors recommend immediate exploration in all acute cases of IUTT, PTT, and TUDT, with no need for radiological investigations. The contralateral testis should be fixed if the patient is 6 weeks of age or younger. The authors recommend early orchiopexy at 3–6 months to avoid the risk of torsion. TUDT remains potentially salvageable despite the poor outcome in this study.

## Acknowledgements

### Conflicts of interest

There are no conflicts of interest.

## References

- 1 Das S, Singer A. Controversies of perinatal torsion of the spermatic cord: a review, survey and recommendations. *J Urol* 1990; **143**:231–233.
- 2 Ibrahim AHM, Al Malki TA, Ghali AM, Musalam AO. Undescended testes: do we need to fix them earlier? *Ann Pediatr Surg* 2005; **1**:21–25.
- 3 Melekos MD, Asbach HW, Markou SA. Etiology of acute scrotum in 100 boys with regard to age distribution. *J Urol* 1988; **139**:1023–1025.
- 4 Djahangirian O, Ouimet A, Saint Vil D. Timing and surgical management of neonatal testicular torsions. *J Pediatr Surg* 2010; **45**:1012–1015.
- 5 Kaye JD, Levitt SB, Friedman SC, Franco I, Gitlin J, Palmer LS. Neonatal torsion: a 14-year experience and proposed algorithm for management. *J Urol* 2008; **179**:2377–2383.
- 6 Sheridan WG, Davies DGL. Extravaginal testicular torsion. *Br J Clin Pract* 1988; **42**:128–130.
- 7 Kaplan GW, Retick A, Snyder HM. *Neonatal torsion: immediate surgical exploration versus conservative management*. San Francisco, CA: American Urologic Association; 2004.
- 8 Driver CP, Losty PD. Neonatal testicular torsion. *Br J Urol* 1998; **82**: 855–858.
- 9 Duckett JW. Routine contra-lateral exploration and fixation is unjustified. *Dial Pediatr Urol* 1991; **14**:5–7.
- 10 Snyder HM, Diamond DA. In utero/neonatal torsion: observation versus prompt exploration. *J Urol* 2010; **183**:1675–1677.
- 11 Guerra LA, Wiesenthal J, Pike J, Leonard MP. Management of neonatal testicular torsion: which way to turn? *J Can Urol Assoc* 2008; **2**: 376–379.
- 12 Van der Sluijs JW, den Hollander JC, Lequin MH, Nijman RM, Robben SGF. Prenatal testicular torsion: diagnosis and natural course. An ultrasonographic study. *Eur Radiol* 2004; **14**:250–255.
- 13 Ahmed SJ, Kaplan GW, DeCambre ME. Perinatal testicular torsion: preoperative radiological findings and the argument for urgent surgical exploration. *J Pediatr Surg* 2008; **43**:1563–1565.
- 14 Yerkes EB, Robertson FM, Gitlin J, Kaefer M, Cain MP, Rink RC. Management of perinatal torsion: today, tomorrow or never? *J Urol* 2005; **174**:1579–1583.
- 15 Al Salem AH. Intrauterine testicular torsion: a surgical emergency. *J Pediatr Surg*. 2007; **42**:1887–1891.
- 16 Stone KT, Kass EJ, Cacciarelli AA. Management of suspected antenatal torsion: what is the best strategy? *J Urol* 1995; **152**: 782–784.
- 17 Sorensen MD, Galansky SH, Striegl AM, Mevorach R, Koyle MA. Perinatal extravaginal torsion of the testis in the first month of life is a salvageable event. *Urology* 2003; **62**:132–134.
- 18 Burks DD, Markey BJ, Burkhard TK, Balsara ZN, Haluszka MM, Canning DA. Suspected testicular torsion and ischemia: evaluation with color Doppler sonography. *Radiology* 1990; **175**:815–821.
- 19 Candocia FJ, Sack Solomon K. An infant with testicular torsion in the inguinal canal. *Pediatr Radiol* 2003; **33**:722–724.
- 20 Kogan SJ, Tennenbaum S, Gill B, Reda E, Levitt SB. Efficacy of orchiopexy by patient age 1 year for cryptorchidism. *J Urol* 1990; **144**:508–509.
- 21 Snyder HM, Diamond DA. In utero/neonatal torsion: observation versus prompt exploration. *J Urol* 2010; **183**:1675–1677.
- 22 Baglaj M, Carachi R. Neonatal bilateral testicular torsion: a plea for emergency exploration. *J Urol* 2007; **177**:2296–2299.