

Transverse testicular ectopia with persistent Mullerian duct syndrome

Mohamed Amin El-Gohary

The aim of the study was to report on three patients who had transverse testicular ectopia (TTE) with persistent Mullerian duct syndrome (PMDS). Three cases of transverse testicular ectopia and persistent Mullerian duct syndrome were managed at our institution between 2000 and 2009. They presented with right-sided inguinal hernia and left nonpalpable testes. The diagnosis was established during diagnostic laparoscopy. The Mullerian structure was divided in the midline laparoscopically in two patients and by open technique in the third. Good length could be obtained to bring the crossed ectopic testis into the ipsilateral scrotal sac in all cases. Awareness of this anomaly and understanding of the embryological process of testicular descent and its associated aberration are

Introduction

Transverse testicular ectopia (TTE) associated with persistent Mullerian duct syndrome (PMDS) is a rare anomaly that can be encountered during laparoscopy for nonpalpable testis or during exploration for groin hernias. About 100 cases of TTE have been reported in published studies. The initial finding at laparoscopy may give the impression of a unilateral absent testis if one is not aware of the possible testicular crossing to the contralateral side. Such cases are likely to be missed without the usage of diagnostic laparoscopy in all cases of impalpable testes.

Case report

Case 1

A 7-month-old boy presented with right inguinal hernia and left impalpable testis. Laparoscopy revealed an absent left testis with a closed internal ring. However, on inspecting the right side, we encountered a testis lying above the opened internal ring (Fig. 1). Pulling on that testis revealed another testis that was attached to the crossed testis by a remnant of a Mullerian tube (Figs 2 and 3). The uterus and cervix were split in the midline laparoscopically, and both testes with a rim of Mullerian tissue were sited in their ipsilateral hemiscrotum. He had a brother with persistent Mullerian syndrome, who presented with right impalpable testis and left inguinal hernia at the age of 2 years.

Case 2

A 6-month-old boy presented with right inguinal hernia and left impalpable testis. Laparoscopy revealed an absent testis on the left side and two testes on the right attached to Mullerian remnants. Through right groin incision, the uterus and cervix were split in the midline, and the left testis was brought to the ipsilateral scrotal sac laparoscopically through a direct route. He had a brother with persistent Mullerian syndrome who presented at the age of 9 months with right impalpable testis and left inguinal hernia.

prerequisites for the proper management of this rare anomaly. These findings highlight the importance of diagnostic laparoscopy in all patients presented with nonpalpable testes. *Ann Pediatr Surg* 8:62–63 © 2012 Annals of Pediatric Surgery.

Annals of Pediatric Surgery 2012, 8:62–63

Keywords: crossed testicular ectopia, persistent Mullerian duct syndrome, transverse testicular ectopia

Al-Noor Hospital, United Arab Emirates

Correspondence to Mohamed Amin El-Gohary, Al-Noor Hospital, P.O Box 8481, Abu Dhabi, United Arab Emirates
Tel: +971 506 225 532; fax: +97126264440;
e-mail: amingoh@gmail.com

Received 30 September 2011 accepted 12 February 2012

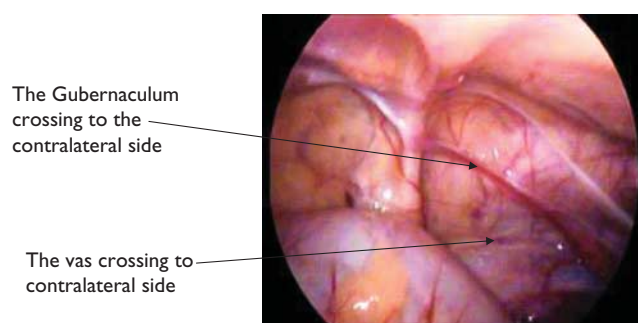
Case 3

An 8-month-old baby presented with right-sided inguinal hernia and nonpalpable left testis with penoscrotal hypospadias. His karyotype was 46,XY. The laparoscopic findings were that of crossed testicular ectopia and persistent Mullerian remnants. Fallopian tubes were present, but the uterus was less muscular than that of previous cases. The uterus split the midline laparoscopically, bringing both testes to the ipsilateral side through a direct approach medial to the internal ring.

Discussion

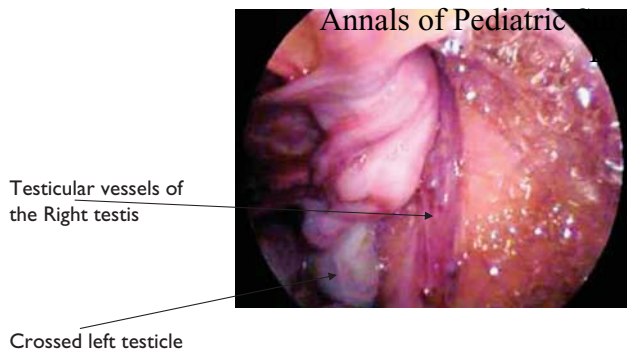
TTE is a rare form of testicular ectopia. It was first reported by Von Lenhossek in 1886 [1]. The finding of PMDS with TTE is a clinically rare anomaly that can be encountered during laparoscopy for nonpalpable testis or during exploration for groin hernias. The anomaly combines defects in regression of fetal Mullerian structures with aberrant testicular descent. The hypotheses for PMDS causation include failure of synthesis or release of Mullerian inhibiting substance (MIS), failure of end

Fig. 1



Initial laparoscopic findings of an absent left testis and vas deferens crossing to the right side.

Fig. 2

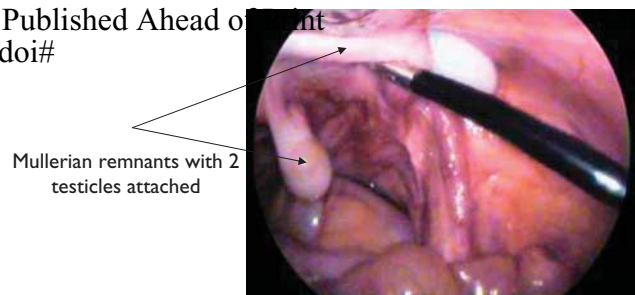


The crossed left testis with the testicular vessels of the right side entering the opened internal ring.

organs to respond to MIS, or a defect in the timing of the release of MIS [2]. TTE was found to occur in animal models when the testicular aspect of the gubernaculum was detached from the testis. In these animal models, the detached testis crosses the midline to descend into the contralateral scrotum. Hence, it could be postulated that defective ipsilateral gubernacular development might predispose to TTE [2]. Several other hypotheses have been reported that could explain the genesis of TTE, which include the emergence of both vasa deferentia from one side [3], the development of both testicles from the same germinal ridge [4], and defective implantation of the gubernaculum testis or obstruction to the inguinal ring [5].

The relationship between PMDS and TTE is less clear. The transabdominal phase of testicular descent is thought to be controlled by MIS, which is secreted locally by each testis (paracrine effect). Fusion of the Mullerian ducts to form a uterus occurs embryologically at the same time as development of the vas deferens [6]. We postulate that an earlier development of one ipsilateral Mullerian structure may pull the contralateral testis toward the developed Mullerian side. The familial incidence of TTE in brothers and twins suggests the likelihood of autosomal recessive inheritance [7]. The initial findings at laparoscopy of no testicular tissues with no evidence of testicular vessels or vas deferens give the impression of an absent testis. It is therefore essential to explore the pelvis and the course of testicular descent before labeling the case as an absent testis. The most commonly described technique for TTE is the modified Omberdan technique in which the ectopic testis is placed in the correct hemiscrotum through a window in the scrotal septum. However, laparoscopy has been reported to aid in placing the ectopic testis with the attached rim of Mullerian structures through a direct route medial to the internal ring in the ipsilateral hemiscrotum [8,9]. One should be careful during the splitting of the uterine remnants to avoid injuring the vas deferens and its blood supply at the base of the Mullerian remnants as both vasa deferentia lie very close to each other. In two of our cases the Mullerian structures were fully

Fig. 3



The two testes attached to the Mullerian remnant.

developed, and in one case the Mullerian structures were hypoplastic. We suggest splitting the uterine tissue leaving about 1 cm above the base of the uterus and use the direct route to place the testis into the ipsilateral hemiscrotum. As malignancy has never been reported in the retained Mullerian ducts, there is no need for its removal as this may endanger the blood supply to the testes [10]. Six cases of testicular tumor in TTE have been reported in adults in which the status of the Mullerian remnant has not been specified. Histology revealed seminoma in five and mixed tumor in one [11]. The relatively high incidence of testicular tumors in such a rare entity of testicular descent necessitates the need for close follow-up of such cases.

Conclusion

TTE with PMDS might be encountered during laparoscopy for impalpable testes or during groin exploration for inguinal hernia. Awareness of this anomaly and understanding of the embryological process of testicular descent and its associated aberration are prerequisites for the proper management of this rare phenomenon.

Acknowledgements

Conflicts of interest

There are no conflicts of interest.

References

- 1 Von Lenhossek M. Ectopia testis transversa. *Anat Anz* 1886; 1:376.
- 2 Açikalin MF, Paşaoğlu O, Tokar B, Ilgici D, İlhan H. Persistent müllerian duct syndrome with transverse testicular ectopia: a case report with literature review. *Turk J Med. Sci* 2004; 34:333–336.
- 3 Frey HL, Rajfer J. Role of the gubernaculum and intraabdominal pressure in the process of testicular descent. *J Urol* 1984; 131:574–579.
- 4 Kimura T. Transverse ectopy of the testis with masculine uterus. *Ann Surg* 1918; 68:420–425.
- 5 Berg AA. Transverse ectopy of the testis. *Ann Surg* 1904; 40:223–224.
- 6 Platii NP. Transversal ectopia of the testis associated with pseudohermaphroditism. *Urol Nefrol* 1965; 30:63.
- 7 Fourcroy JL, Belman AB. Transverse testicular ectopia with persistent Mullerian duct. *Urology* 1982; 19:536–538.
- 8 Wuerstle M, Lesser T, Hurwitz R, Applebaum H, Lee SL. Persistent Mullerian duct syndrome and transverse testicular ectopia: embryology, presentation and management. *J Pediatr Surg* 2007; 42:2116–2119.
- 9 Evans K, Desai A. Total laparoscopic correction of transverse testicular ectopia. *J Pediatr Urol* 2008; 4:245–246.
- 10 El Gohary MA. Laparoscopic management of persistent Müllerian duct syndrome. *Pediatr Surg Int* 2003; 19:533–536.
- 11 Fujita J. Transverse testicular ectopia. *Urology* 1980; 16:400–402.