

# Sacroccocygeal teratoma: 10-year experience in upper Egypt

Mohamed A. Osman and Ibrahim A. Ibrahim

**Purpose** To evaluate our experience with 45 patients with sacroccocygeal teratoma (SCT) in our community (upper Egypt) over a period of 10 years between 2001 and 2011 and determine the outcome of the management and recommendations for treatment strategies.

**Patients and methods** A retrospective study was conducted at our Pediatric Surgical Unit, Assiut University Hospital. The medical records were reviewed for age at presentation, clinical manifestations and investigations, time of surgical approach, histopathology, recurrences, bladder and anorectal function, and cosmetic outcome.

**Results** Forty-five patients with SCT were referred to the Pediatric Surgical Unit. The time of referral was as follows: immediately after birth in the case of five patients; during the first week for 17 patients (four of them died before surgery because of hemodynamic instability and other associated congenital anomalies and were excluded from the study); later in infancy for 22 patients; and at one and half years of age for one child. The lesion was excised in the case of 41 patients. Teratomas were of type I ( $n=9$ ), type II ( $n=20$ ), type III ( $n=11$ ), and type IV ( $n=1$ ) (Altman's classification). The age of patients at surgery ranged from 2 days to 1.5 years. Histological analysis of results revealed mature teratoma ( $n=27$ ), immature teratoma ( $n=9$ ), and malignant teratoma ( $n=5$ ). The coccyx was not removed

in two cases during the early period of the study. The follow-up period ranged from 3 months to 10 years. Recurrence occurred in five (12%) cases, wound infection in four (9.7%), and diarrhea in two (4.8%) cases. The  $\alpha$ -fetoprotein level was high in 35 cases and was normal in two patients; it decreased after excision. Fetal diagnosis was made in five cases by means of a prenatal sonographic scan.

**Conclusion** Prenatal diagnosis of SCT is very important and it is recommended to save the baby from obstructed labor. Early diagnosis allows early surgical intervention and avoids malignant transformation. The coccyx should be excised to decrease the risk of recurrence. Skin flap modification is feasible for large teratomas with healthy skin. *Ann Pediatr Surg* 8:45–48 © 2012 Annals of Pediatric Surgery.

*Annals of Pediatric Surgery* 2012, 8:45–48

**Keywords:** infants, neonates, sacroccocygeal teratoma

Pediatric Surgical Unit, Department of General Surgical, Faculty of Medicine, Assiut University, Assiut, Egypt

Correspondence to Mohamed A. Osman, MD, Pediatric Surgical Unit, Department of General Surgical, Faculty of Medicine, Assiut University 71515, Assiut, Egypt  
Tel: +20 122 743 2276; e-mail: dr.osman@ymail.com

Received 6 September 2011 accepted 12 February 2012

## Introduction

Sacroccocygeal teratomas (SCTs) are the most common type of germ cell tumors and represent a group of both benign and malignant tumor [1]. SCTs are diagnosed in neonates, infants, and children younger than 4 years. SCTs occur more often in girls than in boys; ratios of 3:1 and 4:1 have been reported [2]. SCT is seen in one in every 35 000 live births [3,4]. Their embryological origin is from pluripotent cells in Hensen's node of primitive streak, and they contain components from the three layers: endoderm, mesoderm, and ectoderm. Their mid-line distribution can be explained by arrest or aberrant migration of primordial germ cells [5].

Such pluripotent cells can differentiate into embryonic (mature and immature teratoma) and extraembryonic (choriocarcinoma or yolk sac teratoma), with the latter associated with increased risk for malignant transformation [6]. Metastatic spread is rare and is found in the regional and abdominal lymph nodes, liver, lungs, and very infrequently in the vertebrae and bone marrow. The most common site for extragonadal teratomas is the sacral region, followed by the anterior mediastinum, retroperitoneum, neck, stomach, and vagina [7]. Neonatal SCT tends to be histologically benign, and patients have excellent prognosis after appropriate surgical treatment [8].

Following the Gonzalez–Crussi system, SCTs are graded histologically from 0 to 3. Grade 0 tumors contain only mature tissue. Grades 1–3 SCTs have an immature component, with grade 1 containing rare foci of immature tissue, grade 2 containing moderate quantities, and grade 3 containing large quantities of immature tissue with or without malignant yolk sac elements [9].

The recurrence rate after resection varies from 2 to 35%. This may result from incomplete surgical excision, with the presence of microscopic residues, nonresection of the entire coccyx, and/or tumor spillage [1].

In recent years, the practice of performing a routine prenatal ultrasound scan has led to a significant increase in the number of SCTs diagnosed *in utero* [10]. The newborn with SCT has an excellent prognosis depending on the ease of surgical resection, timing of diagnosis, and malignant potential of the tumors [11–13].

The purpose of this study was designed to determine the different types, clinical presentation, surgical approaches, and outcome of patients with SCTs treated in our community.

## Patients and methods

A retrospective analysis of medical records and follow-up visits of neonates, infants, and children presenting with

SCTs between 2001 and 2011 at our Pediatric Surgery Unit, Assiut University Hospital, was carried out. Data on clinical presentation, age at diagnosis, age at surgery, extent of resection, operative complications, pathology, hormonal study, recurrences, bladder and anorectal function, and cosmetic outcome were collected, studied, and analyzed.

## Results

Forty-five children presented with SCT during the study period. Four out of 45 cases died because of hemodynamic instability and were excluded from our study. Thirty-four of 45 patients were female (75.5% female to 24.5% male). Five out of 41 patients (12%) were referred to us immediately after birth for prenatal diagnosis; three of them were delivered by cesarean section because of obstetric or fetal indication. Those five patients were documented during the recent period of the study. Seventeen patients were referred at ages ranging from the third to seventh day after delivery (this variation in age referral for this group might have been because of differences in distance between referring centers and our hospital); four of the 17 cases died before surgery because of hemodynamic instability and other associated congenital anomalies and were excluded from the study; four of the remaining 13 were referred at 3 days of age, five of 13 at 5 days of age, and four of 13 patients at 7 days of age. Twenty-two of 41 (53.7%) patients were referred later in infancy, and one patient at one and a half years of age. The lesion was excised in 41 patients. The main presentation was a huge mass as shown in Fig. 1; two of them (two of 22) were presented with external bleeding, for which simple suturing of the bleeding site under mask anesthesia was carried out. Four of 22 cases were presented with skin atrophy and multiple ulcers. One patient out of 41 (2.4%) was presented with difficult micturition, urine retention, and constipation at one and a half years of age; pelvic sonography revealed a presacral cystic mass, which was diagnosed as SCT. All patients

were subjected to full physical examination and laboratory investigations such as analysis of complete blood count, prothrombin time and concentration, and  $\alpha$ -fetoprotein (AFP) levels. Diagnosis of all patients was identified clinically and confirmed radically either by ultrasonography and/or by computed tomography to evaluate the pelvic and abdominal extension of the tumor.

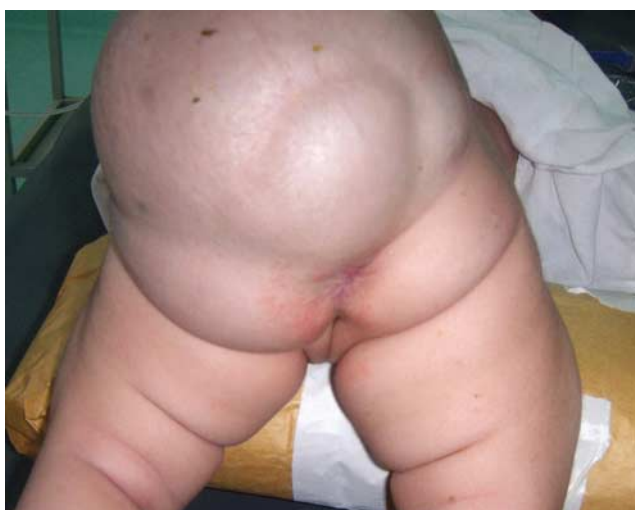According to Altman's classification, our study had nine (22%) patients falling under Altman type I, 20 (48.8%) patients under Altman type II, 11 (27%) patients under Altman type III, and one (2.4%) patient of Altman type IV.

AFP level was determined for 37 patients; it was found to be elevated preoperatively in 35 (94.5%) patients and was normal in two; data on AFP level were deficient for four patients. AFP estimation was made after 3 and 6 months postoperatively for most cases and/or when there was a suspicion of recurrence. It was re-elevated in all recurrent cases.

Surgical intervention was carried out once the baby was fit for surgery. The time taken before surgery ranged from 1 to 4 days for most cases. All patients were subjected to endotracheal intubation anesthesia in prone position. A rectal tube was inserted into the anus to determine the anorectal anatomy during dissection. Chevron incision was the most common way to gain access to the tumor in most cases, and total excision of the tumor was carried out. Skin flap modification was carried out in four cases for a large tumor with healthy skin; it showed good cosmetic results as seen Fig. 2. Regarding coccyx excision, nine patients (in the early period of the study) did not have data on coccyx; hence, 30 patients were considered to have coccygectomy (73%).

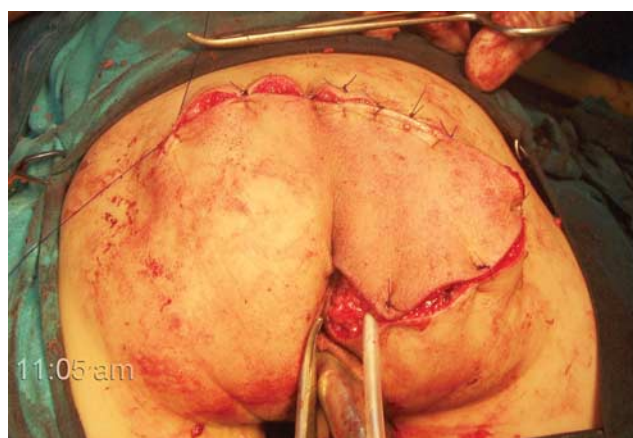
No major complications were encountered during dissection despite the occurrence of bleeding in some cases, which may have been from middle sacral vessels that were controlled during the procedure. The rectum was injured during dissection in one patient and was repaired immediately but the patient developed discharge from the wound after recovery; colostomy was performed after 1 week and was reclosed after 2 months.

Fig. 1



Large sacrococcygeal teratoma.

Fig. 2



Skin after refashioning and closure.

Wound infection occurred in five cases; two of them healed by conservative treatment, whereas the remaining three patients developed skin sloughing and hence debridement and refashioning had to be carried out. Two children developed diarrhea more than 10 times per day without any obvious cause for a long period of time despite conservative treatment; their condition improved with time; but we do not have an explanation for this improvement.

With regard to pathology, 36 of 41 (87.8%) patients presented with benign disease. Mature teratoma was found in 27 patients (65.8%), immature teratoma in nine (21%), and endodermal sinus tumors in five (12%) patients.

With regard to recurrence, the total number of recurrences in our study was five (12%) patients. Three of them were from the early period of the study, two of three had undergone coccyx preservation surgery, and the third one had no data confirming the preservation of the coccyx. Recurrence was found in two patients (40%) from the malignant teratoma group, in two patients (7.4%) from the mature teratoma group, and in one patient (11%) from the immature teratoma group. The histology of recurrence was malignant teratoma in three cases, immature teratoma in one patient, and mature teratoma in one patient from the immature teratoma group. One of the two cases (with coccyx preservation) developed a presacral mass after 3 months postoperatively, and his AFP level did not return to baseline after surgery. Other recurrences developed at ages ranging from 8 to 18 months.

A second surgical intervention was carried out on three patients who had no primary malignant lesion or metastasis. Another two patients received chemotherapy in the oncology department, and two of them died from metastatic lesion to the chest and bone.

From medical records and visits, anorectal evaluation revealed soiling in three patients and gas incontinence in one patient. Physical therapy was given, and reassurance was provided to the parents. Urinary incontinence was present in two children. One patient had weakness of the lower limbs secondary to sciatic nerve palsy.

The patients who underwent the skin flap procedure had an appreciable cosmetic scar. Thirteen of 41 patients had a poor cosmetic scar in the form of an ugly scar in eight cases and a dog-ear in one or both sides in five cases. These patients were subjected to refashioning of the skin on request from parents.

## Discussion

SCT is the most common neonatal neoplasm. It is composed of diverse tissues foreign to the region and is believed to originate from embryological pluripotent cells during embryogenesis [14]. Our study confirmed a female predominance, at a ratio of 3 : 1; which is almost similar to that noted by Aly *et al.* [15] (in the delta sector of Egypt) and was also consistent with that of other published series [2,3,14]. The preoperative death in four patients (8.8%), who were excluded from the study, indicates other associated anomalies that may be incompatible with life; this number is less than that of Gabra *et al.*'s study [16]. In reality, we could determine the main cause

of preoperative death. However, we prefer the explanation given by Hashish *et al.* [1] that most of the tumor-related mortalities are due to the hyperdynamic state caused by the arteriovenous shunting within extremely vascular tumors, which results in high-output cardiac failure.

Because our hospital is a tertiary referral center for a large territory, there was some delay in presentation. In cases of prenatal diagnosis, the mothers were referred to gynecological and obstetric departments so that they and their babies could be cared for better. Our study revealed that 22 of 41 patients were presented late at the age of infancy or childhood, which might have been because of the socioeconomic status (came from poor families and/or had low level of education) of the parents or because of personal beliefs that an abnormal child should be allowed to die in peace. However, some cases of SCT may show no external mass, which could make the diagnosis difficult, as seen in one case in our current study.

A significant increase in the numbers of prenatally diagnosed cases of SCT was noted in the late period of our study because of routine ultrasonic scans of pregnant women, which was in accordance with the results of the study by Lakhoo [17]. In 2005, Galili and Mogilner reported that SCT could be detected prenatally by ultrasound as a caudal mass with or without an intra-abdominal mass; nevertheless, type IV is sometimes difficult to diagnose clearly.

Some cases may present with bleeding from the tumor mass, and this propelled some colleagues such as Smithers *et al.* [18] to perform procedures such as damage control for massive bleeding tumors. In our study, we merely performed simple suturing under mask anesthesia for bleeding, and definitive surgery was postponed until the general condition had been stabilized. A large mass may present with ulceration of skin; our series had four cases with multiple ulcers, which might have been due to late presentation in infancy.

Altman *et al.* [12] in the survey of Surgical Section of the American Academy of pediatrics classified SCT according to pelvic extension into type I (46.7%), type II (34.7%), type III (8.8%), and type IV (9.8%). Our study had nine (22%) patients of Altman type I, 20 (48.8%) patients of Altman type II, 11 (27%) patients of Altman type III, and one (2.4%) patient of Altman type IV. This small difference may have been because of geographical distribution because it agrees with the results found in other studies [4]. The pathological study of our group revealed more than 87% of benign tumors and agrees with that of the study by Rescorla *et al.* [2].

Our study showed increased AFP level preoperatively in 95% of cases, and this concurred with that of other studies [15]. The level of AFP returned to normal in all of our patients except one, in which it remained above normal. The patient developed recurrence within the first 3 months of surgery. His coccyx had not been removed in the first operation, and this may have been the cause of the high level of AFP. The patient was subjected to a second operation and the coccyx was

removed, following which the level of AFP decreased to almost normal after 1 month. This indicates the importance of coccygeal removal. The reevaluation of serum AFP in all recurrent cases made the significance of using AFP as an indicator for recurrence.

With regard to the surgical procedure, chevron incision was carried out in our patients, which has been commonly used in most studies and has yielded reliable results. In our study the incision was modified to the skin flap technique in four cases in which the tumors were large with healthy skin; this yielded an appreciable cosmetic scar without dog-ear deformities. Some colleagues developed another modification [19]. During the early period of our study, sufficient data were available regarding coccyx excision in seven cases; data pertaining to the late period revealed three cases with an intact coccyx. The three patients and the seven patients in addition to another three patients developed recurrence (31.7%). This result highlights the importance of coccyx removal during surgery even if there is a sensation of complete separation of the tumor from the coccyx. Recurrence developed in all malignant varieties of SCTs, in 55% of immature teratomas, and in 11% of mature teratomas. Recurrence was mainly found to be malignant on pathological analysis, except in one case that showed mature tissue, with the original tumor being immature teratoma. This agrees with the results reported by Rescorla *et al.* [2].

In this study, more than 90% of cases had normal anorectal functions; four of 41 patients showed soiling and gas incontinence. However, bladder function in this study was good with urine incontinence in only two cases; this result agrees with the study by Bittmann and Bittmann [20].

The cosmetic results of our study showed 32% of cases with a poor cosmetic scar and this concurred with that of other studies; however, with our modification, the patients had an appreciable scar without dog-ears. The scar can be refashioned at any time and depends on parental request.

We recommend early resection of SCT in the first week of life to decrease the possibility of malignant transformation of the tumor. However, this can be achieved by encouraging antenatal care. It is mandatory to excise the coccyx to decrease the risk of recurrence. We also

recommend the use of skin flap modification to minimize the poor cosmetic results of conventional incisions.

## Acknowledgements

### Conflicts of interest

There are no conflicts of interest.

## References

- 1 Hashish AA, Fayad H, El Attar AA, Radwan MM, Ismael K, Ashour MHM, *et al.* Sacrococcygeal teratoma: management and outcomes. *Ann Pediatr Surg* 2009; **5**:119–125.
- 2 Rescorla FJ, Sawin RS, Coran AG, Dillon PW, Azizkhan RG. Long-term outcome for infants and children with sacrococcygeal teratoma: a report from the Childrens Cancer Group. *J Pediatr Surg* 1998; **33**:171–176.
- 3 Killen DA, Jackson LM. Sacrococcygeal teratoma in the adult. *Arch Surg* 1964; **88**:425–433.
- 4 Makin EC, Hyett J, Ade Ajayi N, Patel S, Nicolaidis K, Davenport M. Outcome of antenatally diagnosed sacrococcygeal teratomas: single-center experience (1993–2004). *J Pediatr Surg* 2006; **41**:388–393.
- 5 Teilmann G. Classification of endodermal sinus tumour (mesoblastoma vitellinum) and so-called "embryonal carcinoma" of the ovary. *Acta Pathol Microbiol Scand* 1965; **64**:407–429.
- 6 Pantanowitz L, Jamieson T, Beavon I. Pathobiology of sacrococcygeal teratomas. *South Afr J Surg* 2001; **39**:56–62.
- 7 Brown NJ. Teratomas and yolk sac tumors. *J Clin Pathol* 1976; **29**:1021–1025.
- 8 Valdiserri RO, Yunis EJ. Sacrococcygeal teratomas: a review of 68 cases. *Cancer* 1981; **48**:217–221.
- 9 Gonzalez Crussi F, Winkler RF, Mirkin DL. Sacrococcygeal teratomas in infants and children. Relationship of histology and prognosis in 40 cases. *Arch Pathol Lab Med* 1978; **102**:420–425.
- 10 Flake AW. Fetal sacrococcygeal teratoma. *Semin Pediatr Surg* 1993; **2**:113–120.
- 11 Hedrick HL, Flake AW, Crombleholme TM, Howell LJ, Johnson MP, Wilson RD, *et al.* Sacrococcygeal teratoma: prenatal assessment, fetal intervention and outcome. *J Pediatr Surg* 2004; **39**:430–438.
- 12 Altman RP, Randolph JG, Lilly JR. Sacrococcygeal teratoma: American Academy of Pediatrics Surgical Section Survey 1973. *J Pediatr Surg* 1974; **9**:389–398.
- 13 Grosfeld JL, Ballantine TVN, Lowe DRL. Benign and malignant teratomas in children: analysis of 85 patients. *Surgery* 1976; **80**:297–305.
- 14 Derikx JPM, De Backer A, van de Schoot L, Aronson DC, de Langen ZJ, van den Hoonaard TL, *et al.* Long-term functional sequelae of sacrococcygeal teratoma: a national study in the Netherlands. *J Pediatr Surg* 2007; **42**:1122–1126.
- 15 Aly KA, Shoier M, Badrawy T. Sacrococcygeal teratoma: a neonatal surgical problem. *Ann Pediatr Surg* 2006; **2**:106–111.
- 16 Gabra HO, Jesudason EC, McDowell HP, Pizer BL, Losty PD. Sacrococcygeal teratoma—a 25-year experience in a UK regional center. *J Pediatr Surg* 2006; **41**:1513–1516.
- 17 Lakhoo K. Neonatal teratomas. *Early Hum Dev* 2010; **86**:643–647.
- 18 Smithers CJ, Javid PJ, Turner CG, Klein JD, Jennings RW. Damage control operation for massive sacrococcygeal teratoma. *J Pediatr Surg* 2011; **46**:566–569.
- 19 Fishman SJ, Jennings RW, Johnson SM, Kim HB, Peña A. Contouring buttock reconstruction after sacrococcygeal teratoma resection. *J Pediatr Surg* 2004; **39**:439–441.
- 20 Bittmann S, Bittmann V. Surgical experience and cosmetic outcomes in children with sacrococcygeal teratoma. *Curr Surg* 2006; **63**:51–54.