

# Retrocaval ureter: a report on two neonates

Ibrahim E. Bassiouny, Tariq O. Abbas and Ayman Mosleh

**Retrocaval ureter is a relatively rare anomaly that usually manifests in the third or the fourth decade of life. Its symptoms are because of ureteric obstruction, caused extrinsically by an abnormal inferior vena cava, intrinsically by ureteric hypoplasia, or both. Surgery is needed for symptomatic patients and involves transection and relocation of the ureter anterior to the inferior vena cava. We report here two neonates as might be very early diagnosed who needed surgery to correct a retrocaval ureter. *Ann Pediatr Surg* 9:40–44 © 2013 Annals of Pediatric Surgery.**

## Introduction

Retrocaval ureter is a relatively rare anomaly, with a reported incidence of one in 1000 [1]. It is three times more common in males than in females, more common on the right than on the left side, and may be associated with other inferior vena cava (IVC) and renal anomalies.

Symptoms are because of obstruction of the ureter and are usually present during the third or the fourth decade of life. However, it may also be present in children. Here, we describe two neonates who presented with a retrocaval ureter.

## Case report

### Patient 1

Patient 1 was a male newborn baby with no dysmorphism and antenatally detected bilateral hydronephrosis. A complete laboratory evaluation was carried out. The hematological profile was within normal limits; the serum electrolytes were normal and so were his blood urea nitrogen and creatinine values. Then, creatinine started to increase by the third day to 270  $\mu\text{mol/l}$ . Abdominal ultrasonography showed severe hydronephrosis in the right side and a left multicystic kidney with radiological features suggestive of a posterior urethral valve. Urethral catheterization failed to improve the renal profile and creatinine continued to increase. Abdominal ultrasonography showed a slightly dilated upper calyx measuring 9 mm noted in the right side (Fig. 1).

We performed a percutaneous nephrostomy, which resulted in an improvement in serum creatinine concentrations.

Subsequently, the serum electrolytes result was as follows: urea 5.4 mmol/l, creatinine 235  $\mu\text{mol/l}$ , Cl 104 mmol/l, Na 141 mmol/l, K 5 mmol/l, and  $\text{CO}_2$  28 mmHg. Then, it was concluded that the patient requires renal replacement therapy and pyelostomy was performed through a posterior approach.

Then, the creatinine decreased gradually. On 9 November 2006, the pyelostomy was closed and left nephrectomy was performed.

*Annals of Pediatric Surgery* 2013, 9:40–44

**Keywords:** hydronephrosis, retrocaval ureter, neonates

Department of Pediatric Surgery, Hamad General Hospital, Doha, Qatar

Correspondence to Tariq O. Abbas, MRCS, Department of Pediatric Surgery, Hamad General Hospital, Al Rayyan St, Doha 3050, Qatar  
Tel: +974 550 93651; fax: +009 744 439 1842; e-mail: tariq2c@hotmail.com

Received 10 February 2012 accepted 28 October 2012

Thereafter, voiding cystourethrography showed a grade IV right vesicoureteric reflux with failure of the contrast to reach the pelvis of the kidney (Fig. 2). The patients creatinine started to increase again, for which another percutaneous nephrostomy was performed (Fig. 3).

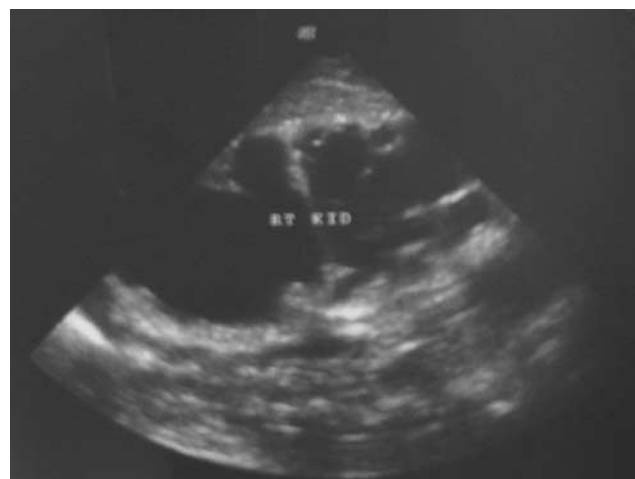Creatinine started to improve again. Contrast-enhanced computed tomography (CT) of the abdomen showed a 'reverse J'-shaped right ureter curving upward and medially (Fig. 4).

The patient was re-explored and a retrocaval ureter was discovered (Fig. 5). He underwent a ureteral mobilization with a ureteroureterostomy. His postoperative period was unremarkable.

### Patient 2

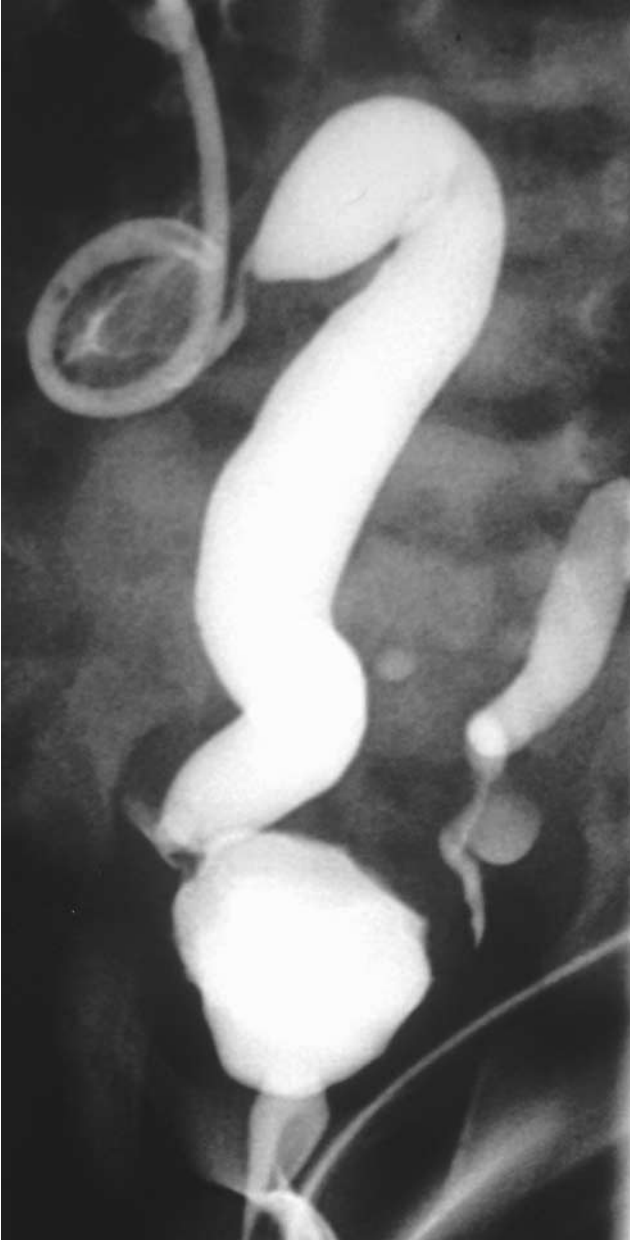
A female neonate had been diagnosed antenatally to have a right hydronephrosis (15 mm). At birth, after 36 weeks of gestation, she was diagnosed with a tracheoesophageal

**Fig. 1**



Abdominal ultrasonography of patient 1 showing severe hydronephrosis of the right kidney.

Fig. 2



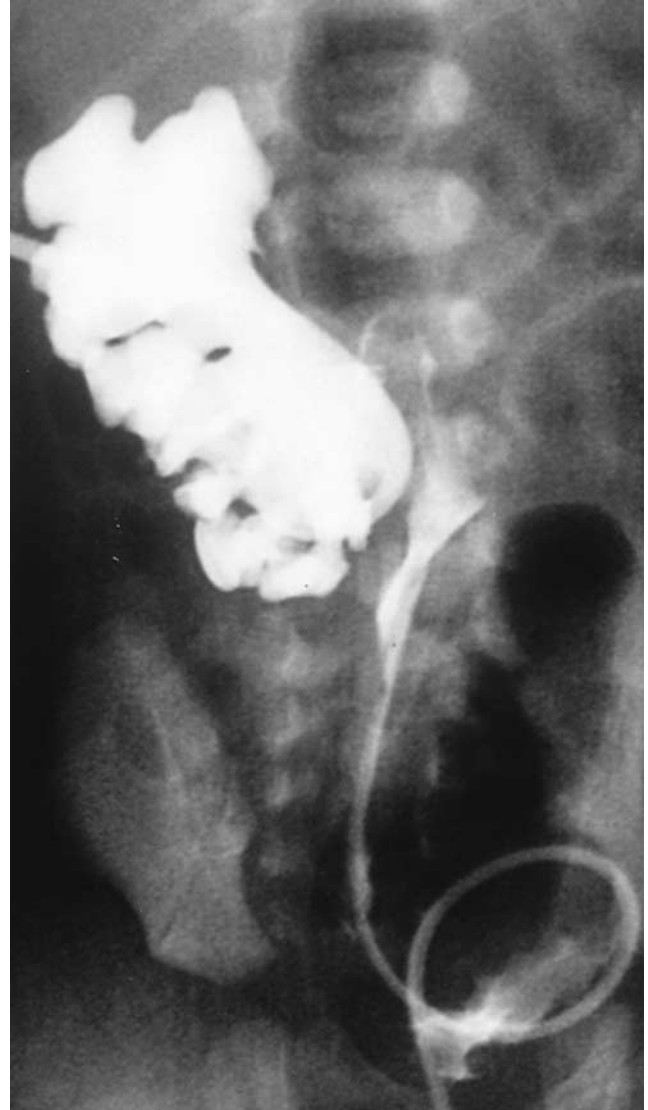Voiding cystourethrography of patient 1, showing a grade IV vesicoureteric reflux on the right side.

fistula, duodenal obstruction, annular pancreas, Meckel's diverticulum, and vulvar anus. The tracheoesophageal fistula was repaired and a duodenoduodenostomy was performed, followed by a posterior sagittal anorectoplasty for the anorectal malformation (Fig. 6a and b).

Postnatal voiding cystourethrography indicated a grade IV right vesicoureteric reflux with a high suspicion of a retrocaval ureter. Intravenous urography (IVU) was performed to determine the presence of a nonobstructed retrocaval ureter and showed a 'reverse J'-shaped right ureter curving upward and medially.

The patient developed recurrent urinary tract infections and renal scarring, for which she received a deflux

Fig. 3



Percutaneous pyelostography showed an obstruction at the pelviureteral junction level.

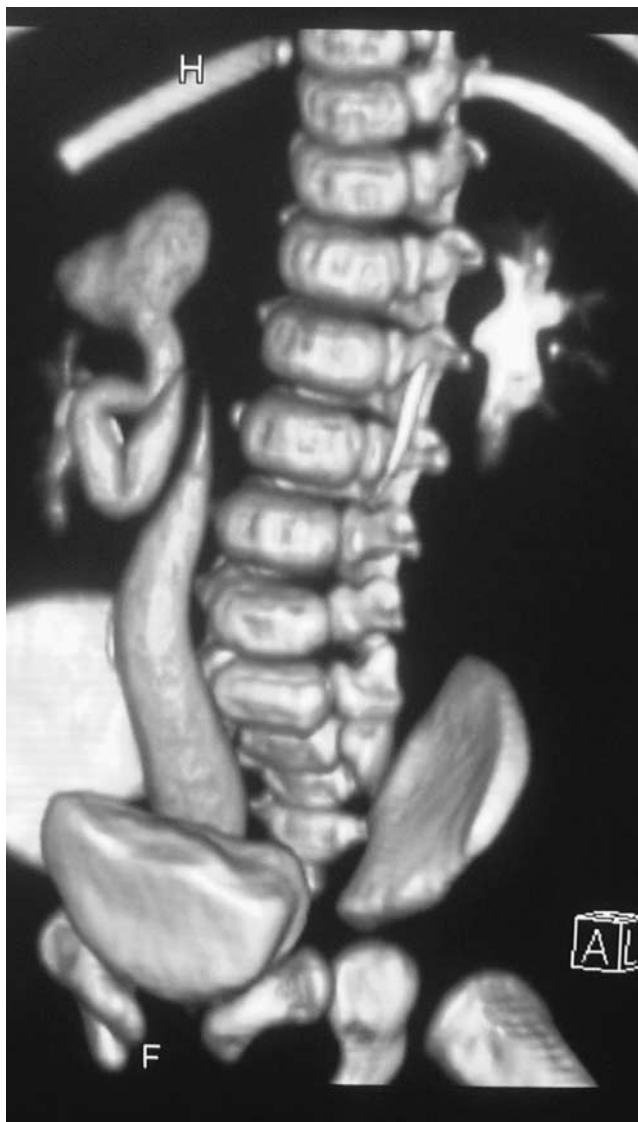injection. The patient had an uneventful postoperative period and was followed up in the outpatient clinic for more than 3 years.

### Discussion

Retrocaval ureter is a developmental anomaly of the IVC, where the ureter passes behind the abnormal IVC. Embryologically, the infrarenal IVC in patients with retrocaval ureter is formed by the subcardinal rather than the supracardinal vein [2]. This disorder involves the right ureter, which usually deviates medially behind the IVC, winding about and crossing its anterior aspect from a medial to a lateral direction, thereafter resuming a normal iliopelvic course, distally, to the bladder. The renal pelvis and upper ureter are typically elongated and dilated in a J or a fishhook shape before passing behind the IVC. However, the collecting system is not always obstructed.

Initially, the venous retroperitoneal pathways consist of symmetrically placed vessels, both central and dorsal.

Fig. 4



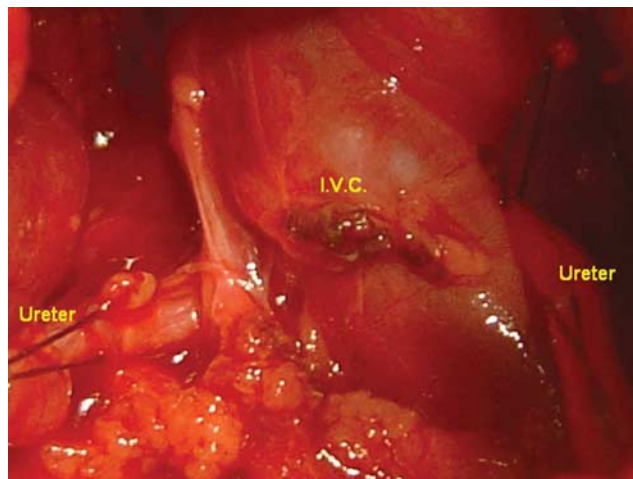
Contrast-enhanced computed tomography image of the abdomen of patient 1, showing a 'reverse J'-shaped right retrocaval ureter curving upward and medially.

The posterior cardinal and supracardinal veins lie dorsally, and the subcardinal veins lie ventrally. These channels, with their anastomoses, form a collar on each side through which the ascending kidneys pass. Normally, the IVC is formed suprenally from the right subcardinal vein and infrarenally from the right supracardinal vein, dorsal to the ureter. The subcardinal–supracardinal anastomosis forms its renal segment, the left supracardinal vein and the lumbar portion of the right posterior cardinal vein atrophy, and the subcardinal veins become the internal spermatic veins.

The incidence of retrocaval ureter is not easy to determine. A postmortem study has reported an incidence of one per 1500 [3], whereas the incidence of circumcaval ureter was estimated to be one in 1000 live births [1,4].

In most cases, retrocaval ureters are asymptomatic and are detected only during imaging. Symptoms, when they

Fig. 5



Intraoperative view of patient 1 showing the confluence of the ureter and the inferior vena cava (IVC).

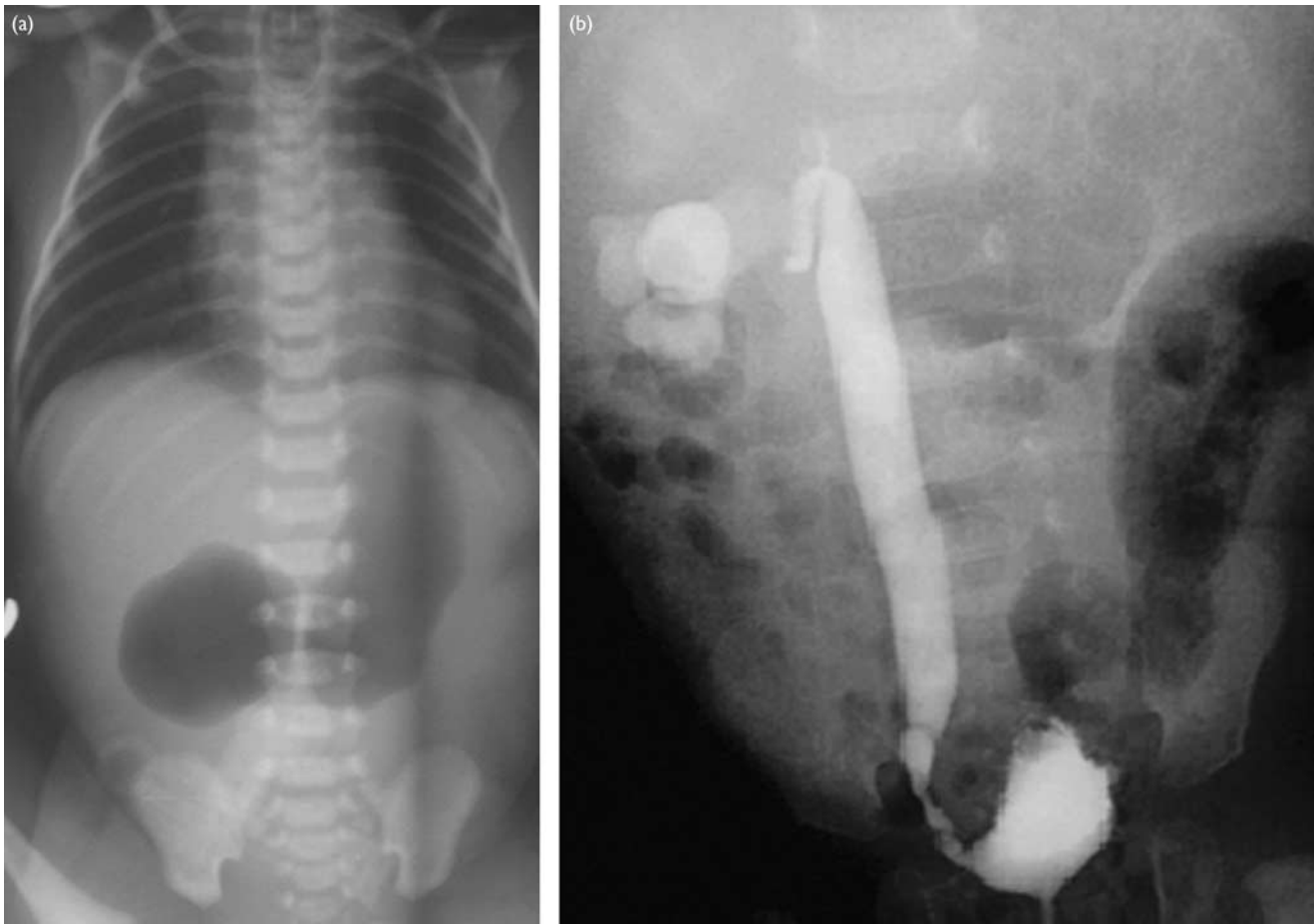
occur, are because of ureteric obstruction, caused extrinsically by an abnormal IVC, intrinsically by ureteral hypoplasia, or both. It is essential to look for a ureteric stenosis during exploration and excise this segment if it is present. The usual symptoms of a retrocaval ureter are abdominal pain, hematuria, infection, and/or urolithiasis. Despite being a congenital condition, symptoms usually arise during the third or the fourth decade of life and result from the compressive effect exerted by the IVC on the ureter, with consequent proximal ureterohydronephrosis. In one patient, the diagnosis was not made until the time of surgery.

The retrocaval portion of the ureter is usually obstructed, but this is not a constant finding [5,6]. The main causes of hydronephrosis are compression by the psoas muscle, spinal column, and IVC itself [5,7]. Classifications are based on radiographic appearance and the site of narrowing of the ureter (Table 1) [5]. Of 162 patients with circumcaval ureters analyzed, ~93% could be classified as type I and the remainder as type II [6,7].

The condition is usually diagnosed by the presence, on IVU or retrograde pyelogram, of a reverse 'J'-shaped or 'S'-shaped ureter, with medial deviation of the ureter at the level of the L3–L4 vertebrae and varying degrees of hydronephrosis. Medial deviation of the upper ureter on ultrasonography may suggest this diagnosis, but this depends on the degree of distension and should be confirmed by other imaging modalities. Contrast CT, which can clearly visualize the anatomy of the ureter and IVC, is probably the least invasive method to diagnose retrocaval ureter. Diuretic renography is required to assess the degree of functional obstruction, whereas venacavography is required only if caval surgery is contemplated.

IVU often fails to visualize the portion of the ureter beyond the J hook (i.e. extending behind the IVC). Therefore, a diagnosis of retrocaval ureter should be

Fig. 6



Patient 2 (a) plain abdominal X ray showing a double-bubble sign and a duodenoduodenostomy was performed. (b) Intravenous urography (IVU) showed a 'reverse J'-shaped right ureter curving upward and medially.

**Table 1 Classification of retrocaval ureter on the basis of radiographic appearance and site of narrowing of the ureter 5**

Type I	<p>More common Ureter crosses behind the IVC at levels L1–L3 The ureter has a fish hook-shaped (S-shaped) deformity. Ureter obstruction appears to occur at the edge of the iliopsoas muscle, at which point the ureter deviates cephalad before passing behind the IVC Marked hydronephrosis observed in 50% of patients</p>
Type II	<p>Cross over occurs at levels higher than L1–L3 or at the renal pelvis Lower degree of hydronephrosis or none at all Obstruction if present appears to be at the lateral wall of the IVC, as the ureter is compressed against perivertebral tissues The renal pelvis and upper ureter lie almost horizontal before encircling the IVC in a smooth curve (sickle-shaped curve)</p>

IVC, inferior vena cava.

suspected when IVU shows an S-shaped deviation of the upper third of the right ureter toward the midline, with the distal ureter continuing medial to the pedicles of the IVC. On retrograde ureteropyelography, the lesion shows an S-like route [6]. Ultrasonography [8,9], CT, and MRI have also been useful in defining the vascular malformation. When necessary, CT may be the procedure of choice to confirm the diagnosis and avoid retrograde ureteropyelography [9,10]. At present, spiral CT scan is the best

tool for the diagnosis of IVC abnormalities and circumcaval ureters.

Treatment is needed only if there is significant obstruction, infection, urolithiasis, or increasing hydronephrosis. Ultrasound is the best tool for follow-up of evidence of complications in children. Surgical treatment is indicated for a symptomatic patient with severe hydronephrosis. Surgery involves transection of the ureter at the point where it leaves the border of the IVC, resection of the inert retrocaval portion, and ureteroureterostomy or pyeloureterostomy between the two peristaltic segments [7,11,12]. It is important to be mindful of the renal artery and aorta superiorly and the iliac vessels inferiorly [13].

Surgery involves resection of the retrocaval segment and relocation of the anastomosis anterior to the IVC. The risks of complications are lower when both the dissection and the anastomosis are at the pelvic level, as there is minimal dissection of the ureter. During the last decade, laparoscopic procedures have almost completely replaced open surgery because the former are associated with rapid recovery, early discharge from the hospital [14,15],

and excellent cosmetic results. Nephrectomy may be required in exceptional patients with nonfunctional kidneys.

### Conclusion

A retrocaval ureter is a rare anomaly in children and needs a high index of suspicion to be detected early in life. Medial deviation of the ureter should lead to a suspicion of a retrocaval ureter. Contrast-enhanced CT and diuretic renography are the methods of choice to reveal the anatomy and function on the affected side. Surgery is required in patients who are symptomatic or having increasing obstructions. Complication rates are lower when the anastomosis is at the level of the renal pelvis.

### Acknowledgements

#### Conflicts of interest

There are no conflicts of interest.

### References

- 1 Soundappan SVS, Barker AP. Retrocaval ureter in children: a report of two cases. *Pediatr Surg Int* 2004; **20**:158–160.
- 2 Rocha Brito R, Zulian R, Albuquerque J, Borges HJ. Retrocaval ureter. *Br J Urol* 1973; **45**:144–152.
- 3 Heslin JE, Mamonas C. Retrocaval ureter: report of four cases and review of literature. *J Urol* 1951; **65**:212–222.
- 4 Clements JC, Mcleod DG, Greene WR, Stutzman RE. A case report: duplicated vena cava with right retrocaval ureter and ureteral tumor. *J Urol* 1978; **119**:284–285.
- 5 Bateson EM, Atkinson D. Circumcaval ureter: a new classification. *Clin Radiol* 1969; **20**:173–177.
- 6 Kenawi MM, Williams DI. Circumcaval ureter: a report of four cases in children with a review of the literature and a new classification. *Br J Urol* 1976; **48**:183–192.
- 7 Xiaodong Z, Shukun H, Jichuan Z, Xiaofeng W, Guangdong M, Xingke Q. Diagnosis and treatment of retrocaval ureter. *Eur Urol* 1990; **18**:207–210.
- 8 Schaffer RM, Sunshine AG, Becker JA. Retrocaval ureter: sonographic appearance. *J Ultrasound Med* 1985; **4**:199–201.
- 9 Murphy BJ, Casillas J, Becerra JL. Retrocaval ureter: computed tomography and ultrasound appearance. *J Comput Tomogr* 1987; **11**:89–93.
- 10 Kellman GM, Alpern MB, Sandler MA, Craig BM. Computed tomography of vena caval anomalies with embryologic correlation. *Radiographics* 1988; **8**:533–556.
- 11 Harrill HC. Retrocaval ureter: report of a case with operative correction of the defect. *J Urol* 1940; **44**:450–457.
- 12 Considine J. Retrocaval ureter: a review of the literature with a report on two new cases followed for fifteen years and two years respectively. *Br J Urol* 1966; **38**:412–423.
- 13 Hellsten S, Grabe M, Nylander G. Retrocaval ureter. *Acta Chir Scand* 1980; **146**:225–228.
- 14 Ameda K, Kakizaki H, Harabayashi T, Watarai Y, Nonomura K, Koyanagi T. Laparoscopic ureteroureterostomy for retrocaval ureter. *Int J Urol* 2001; **8**:71–74.
- 15 Bhandarkar DS, Lalmalani JG, Shivde S. Laparoscopic ureterolysis and reconstruction of a retrocaval ureter. *Surg Endosc* 2003; **17**:1851–1852.