



Non-Reversed Appendicostomy for Antegrade Continence Enema in the Treatment of Encopresis

Kamal Abdel-Elah, Basem Saied, Adham EL-Saied, Sabry Mahmoud*

Pediatric Surgery Unit, General Surgery Department*, Faculty of Medicine, Mansoura University

Background/Purpose: Constipation in children is considered when stool frequency is less than three times per week. Encopresis represents 80-90% of children with fecal incontinence. Operative strategy for management of encopresis ranges from resectional surgery to myotomy. The objective of the study was to evaluate the efficacy of non-reversed appendicostomy without antireflux mechanism for management of encopresis in children.

Materials & Methods: The study included 35 patients with severe idiopathic constipation and encopresis with failure of conservative measures. They were subjected to non-reversed appendicostomy without anti-reflux procedures.

Results: The incidence of complications was 22.8% and included stomal leak, stricture, retraction and granulation tissue formation. False passage during dilatation occurred in one case. Antegrade continence enema effectively controlled constipation and encopresis.

Conclusion: Non-reversed appendicostomy without antireflux mechanism is safe and rapid with minimal incidence of leakage. Constipation and encopresis was effectively controlled with this simple procedure.

Index Word: Constipation, encopresis, antegrade continence enema.

INTRODUCTION

Encopresis is defined as soiling of the underpants with feces secondary to overflow, while constipation in children is considered when stool frequency is less than 3 times per week¹.

Encopresis represents 80-90% of children with fecal incontinence^{2,3}. The cycle typically begins with painful bowel movements that leads to retention and the development of constipation. No obvious organic etiology is found. The urge to defecate is met with attempts to withhold stool. Stool impaction stretches the colon over time leading to inertia and diminished sensory threshold at the rectum due to changes in the vesicoelastic properties of the rectal receptors¹.

Children with severe constipation and encopresis suffer from abdominal pain, bloating and soiling that often result in a poor quality of life and delayed social development⁴⁻⁶. There have been many reported operative strategies for the management of severe idiopathic constipation⁷ including fecal diversion⁸, transabdominal resection of the rectum and sigmoid⁹⁻¹² and transanal resection of the rectosigmoid⁷. Other less invasive techniques have been described such as antegrade continence enema (ACE)^{13,14}, botulinum toxin injection¹⁵ and internal anal sphincter myectomy¹⁶.

ACE procedure combines three principles: the Mitrofanoff principle of a continent catheterizable

stoma, complete colonic emptying producing fecal continence and the ability to completely empty the colon with antegrade colonic irrigation¹⁷.

The original description of the ACE described by Malone, 1990,¹⁸ was the amputation of the appendix from the cecum, reversing it and implanting it into a submucosal tunnel to create an anti reflux flap valve. The free end of the appendix was then brought out into a suitable position on the abdominal wall, the preferred position being the umbilicus.

Curry in 1999,¹⁹ described the use of an in-situ appendix with no anti reflux procedure. In the majority of cases, the stoma was continent.

The objective of the study was to evaluate the efficacy of simple appendicostomy for the antegrade administration of colonic washouts in the management of children with severe encopresis not responding to medical management and behavioral modalities.

PATIENTS AND METHODS

This is a prospective study, done between October 2006 & February 2009 on 35 children with severe idiopathic constipation and encopresis. After failure of medical management and behavioral modalities (rectal washouts, combined with laxatives and toilet training for 6 months), patients were subjected to non reversed appendicostomy without anti reflux procedure.

Exclusion Criteria:

- Cases with good response to conservative measures (Medical treatment and behavioral modalities).
- Constipation and incontinence secondary to identifiable causes like spina bifida, constipation following surgery for anorectal malformations or Hirschsprung's disease.

The patients were subjected to:

- Thorough history and physical examination.
- Barium enema, (Figure 1 A&B), to assess the degree of colonic dilatation.
- Rectal punch biopsy to exclude neurogenic or myogenic causes.
- Repeated colonic washouts with normal saline till complete evacuation of the colon. Manual disimpaction under anesthesia was performed for children with fecalomas.
- Patients remained on clear fluids 2 days before

operation.

- Intravenous antibiotics (cephtriaxone 50 mg/kg/day and metronidazole 30 mg/kg/day) were administered 2 hours before operation.

Surgical approach: Right lower quadrant incision overlying the cecum, which was mobilized and the length of the appendix was assessed (Figure 2). A small incision was performed through the umbilical cicatrix with delivery of the appendix through this incision. The cecum was anchored to the anterior abdominal wall with four stitches of 4/0 polyglactine sutures (Figure 3).

An 8 Fr silastic Foley catheter was inserted in the cecum through the appendix. The patients started oral fluids on returning of bowel sounds and were discharged home on the third to fifth post operative day.

ACE was started one week after operation through the catheter with tap water and repeated daily for one month before removal of the catheter.

After that, ACE was performed with a Nelaton catheter (8-10Fr), inserted only at the time of irrigation.

The outcome was measured by:

- Frequency of motions after each enema.
- Frequency of ACE needed to prevent soiling.
- Number of soiling between enemas.
- Occurrence of complications.

RESULTS

The median age at the time of operation was 5 years (2.5-9 years), with the male preponderance 60% of the series (21 cases).

In the selected patients, (35 children), medical treatment including rectal wash outs, different types of laxatives and toilet training for 6 months had failed. Daily enema volume ranged from 250ml to one liter with irrigation time lasting from 10-30minutes, and emptying within 20-90minutes. The frequency of ACE ranged from once every day to once per week (Table 1). (Frequency, volume and time of irrigation were determined by trial and error for each individual child).

Encopresis and constipation resolved within one-three months of ACE washouts.

The mean follow up period was 21 months (11 to 34

months), during which there was no fecal impaction or episodes of soiling. In 8 patients, number of irrigations was decreased gradually till it became discontinued within 2 years guided by clinical improvement and contrast study that showed improvement of megarectum (Figure 4 A & B). The other 27 patients were still dependant on ACE but showed gradual decrease in the frequency of rectal irrigation.

Complications were reported in a total of 8 patients (22.8%) (Table 2) most of them were linked to the

stoma only (stomal leak, stricture, retraction and granulation tissue formation). Stricture was corrected with repeated dilatations while stoma retraction was in need for local exploration through the abdominal wall with re-fixation of the appendix to the umbilical cicatrix. Silver nitrate painting was applied to the stoma that showed granulation tissue formation. False passage of Hegar dilator had occurred in one case during trial of dilatation evidenced by contrast study. It was treated conservatively and ACE was abandoned for 4 weeks before restarting again.

Table 1: Frequency of ACE to prevent soiling

<i>Frequency</i>	<i>Number</i>
Every day	9
Every other day	17
Twice per week	7
Once per week	2

Table 2: Complication (8 = 22.8%)

<i>Complication</i>	<i>Number</i>	
Stomal leak	3	(8.6%)
Stricture	2	(5.8%)
Retraction	1	(2.8%)
Granulation tissue formation	1	(2.8%)
False passage of the dilator	1	(2.8%)

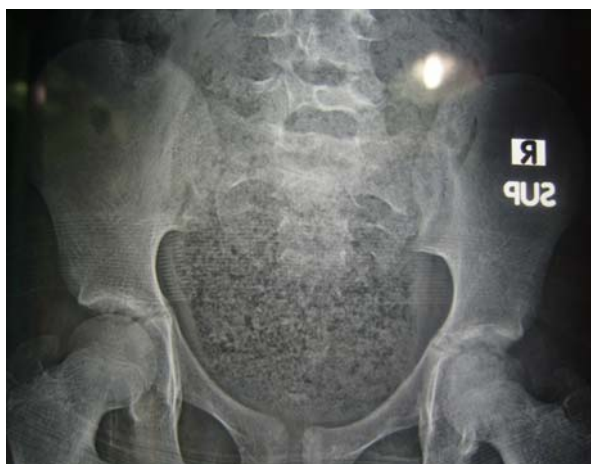

Fig. 1 A Plain X-ray showing fecaloma in the rectum

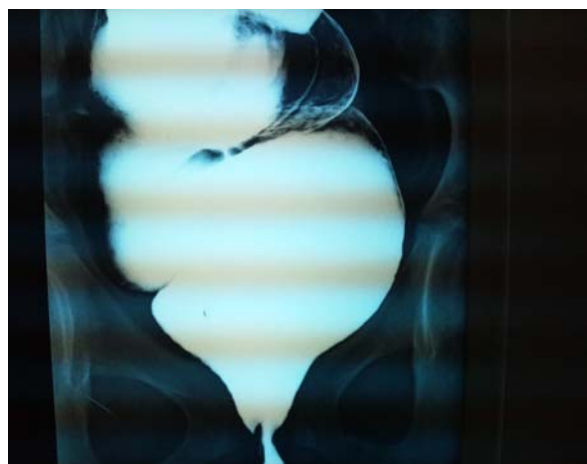


Fig. 1 B Barium enema showing megarectum

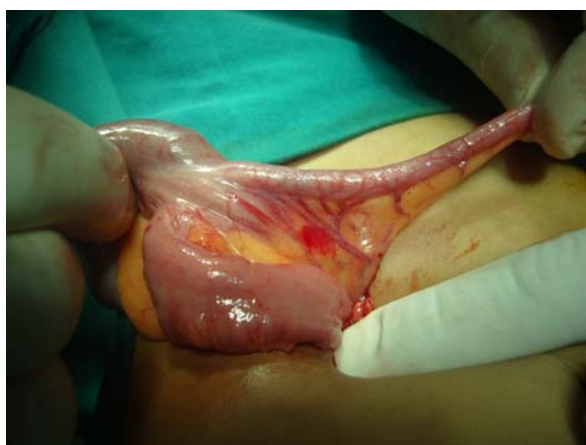

Fig. 2: Appendix length is assessed

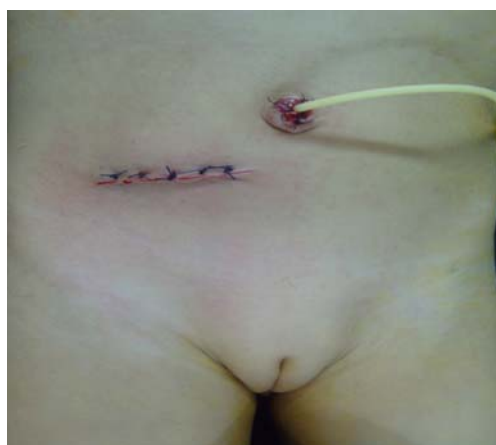

Fig. 3: Stoma is placed through the umbilicus

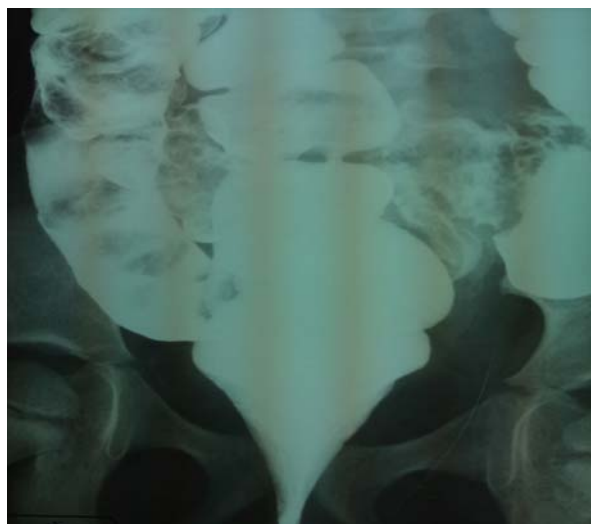

Fig. 4 A: Barium enema showing mega rectum before ACE

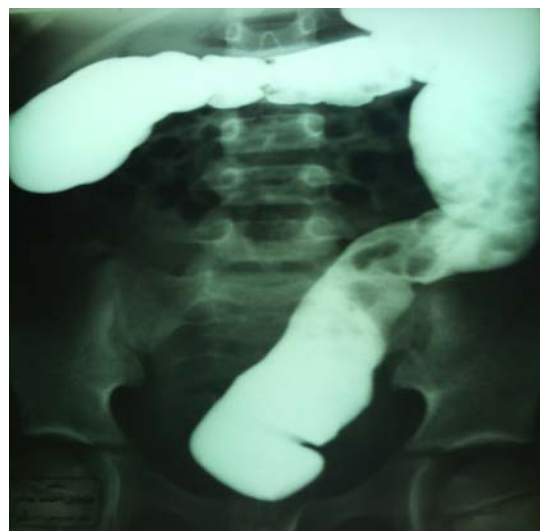

Fig. 4 B: Barium enema six month after ACE

DISCUSSION

Patients who have encopresis are considered to be pseudo incontinent and once their constipation is adequately managed, they stop soiling²⁰. The vast majority of these patients can be managed medically and only 11% needs operative intervention⁷. However, encopresis is not socially acceptable and most of the patients don't want to be treated with diets and rectal enema any more²¹.

Many studies have reported ACE as a therapeutic option in patients with idiopathic, intractable functional constipation when maximal conventional therapies are not successful^{22,23}. It minimizes the physical and emotional distress associated with dietary restrictions and repeated retrograde enemas. Also it enables antegrade delivery of an enema to clean out the colon at regular intervals, avoiding accumulation of stool and reducing soiling episodes²⁴.

In the study of Mousa et al²⁴, cecostomy was constructed for 31 children with defecation disorders. One patient needed surgical exploration due to development of pneumoperitoneum. In our series, the complications were confined to the stoma of the appendix only (stricture, retraction, leak and granulation tissue formation), and we didn't need a second laparotomy. In Mousa et al series²⁴, different types of enema solution were used in addition to oral laxatives whereas, in our series, we use only tap water in a dose of 20-30 ml/kg without the need for oral laxatives with good response in all cases. Tap water enemas are safe for the use in ACE in children without increased risk of water intoxication²⁵ and, at the same time, warm water is associated with lower incidence of abdominal cramps than irritant solutions²⁶. In accordance with the series reported by Wong et al²⁶, Mousa et al²⁴, and Yossef et al²⁷, ACE in children with functional constipation resulted in a significant increase in defecation frequency, decrease in soiling episodes and improvement of quality of life. On the other hand, Curry et al²⁸ reported a lower success rate (39%) after ACE placement in children with functional constipation and encopresis compared to 73% for all other underlying conditions. In the series of Wong et al,²⁶ time of up to 6 months was required to adjust the frequency and volume of irrigation to maximize the benefits of the enema, meanwhile, our series confirmed that one to three months only were sufficient to reach the same benefits.

Children and parents in this series were satisfied

in spite of the manageable complications occurred, due to the dramatic improvement in their psychosocial behavior and general well being.

CONCLUSION

This study confirms that the use of ACE through non-reversed appendicostomy is an effective modality for treatment of encopresis not responding to medical management; especially for attacks of soiling, physical and social activities.

Nonreversed appendicostomy without anti-reflux procedure is safe and rapid with minimal incidence of stomal leakage.

REFERENCES

1. Loening-Baucke V, Yamada T. Is the afferent pathway from the rectum impaired in children with chronic constipation and encopresis?. *Gastroenterology* 109: 397-403, 1995.
2. Loening-Baucke V. Prevalence rates for constipation and fecal and urinary incontinence. *Archives of Diseases in Childhood* 92: 486-489, 2007.
3. McGrath ML, Mellon MW, Murpy L. Empirically supported treatment in pediatric psychology: Constipation and encopresis. *Journal of Pediatric Psychology* 25: 225-254, 2000.
4. Clarke MC, Chow CS, Chase JW, et al. Quality of life in children with slow transit constipation. *J Pediatr Surg* 43: 320-4, 2008.
5. Halder SL, Locke 3rd GR, Talley NJ, et al. Impact of functional gastrointestinal disorders on health-related quality of life: a population-based case-control study. *Aliment Pharmacol Ther* 19: 233-42, 2004.
6. Youssef NN, Langseder AL, Verga BJ, et al. Chronic childhood constipation is associated with impaired quality of life: a case-controlled study. *J Pediatr Gastroenterol Nutr* 41: 56-60, 2005.
7. Levitt MA, Martin CA, Falcone Jr RA, et al. Transanal rectosigmoid resection for severe intractable idiopathic constipation. *J Pediatr Surg* 44: 1285-1291, 2009.
8. Scarpa M, Barollo M, Keighely MR, Ileostomy for constipation: long-term postoperative outcome. *Colorectal Dis* 5: 224-7, 2005.
9. Gladman MA, Scott SM, Lunniss PJ, et al. Systematic

- review of surgical options for idiopathic megarectum and megacolon. *Ann Surg* 241: 562-74, 2005.
10. Levitt MA, Pena A. Surgery and constipation: when, how, yes, or no? *J Pediatr Gastroenterol Nutr* 41(1): 558-60, 2005.
 11. Pena A, Levitt MA. Colonic inertia disorders in pediatric. *Curr Probl Surg* 39: 666-730, 2002.
 12. Verne GN, Hocking MP, Davis RH, et al. Long-term response to subtotal colectomy in colonic inertia. *J Gastroenterol Surg* 6: 738-44, 2002.
 13. Cascio S, Flett ME, De la Hunt M, et al. MACE or caecostomy button for idiopathic constipation in children: a comparison of complications and outcomes. *Pediatr Surg Int* 20: 484-7, 2004.
 14. King SK, Sutcliffe JR, Southwell BR, et al. The antegrade continence enema successfully treats idiopathic slow-transit constipation. *J Pediatr Surg* 40: 1935-40, 2005.
 15. Keshtgar AS, Ward HC, Sanei A, et al. Botulinum toxin, a new treatment modality for chronic idiopathic constipation in children: long-term follow-up of a double-blind randomized trial. *J Pediatr Surg* 42: 672-80, 2007.
 16. Keshtgar AS, Ward HC, Clayden GS, et al. Thickening of the internal anal sphincter in idiopathic constipation in children. *Pediatr Surg Int* 20: 817-23, 2004.
 17. Malone PS. The antegrade continence enema procedure. *British Journal of Urology International* 93: 248-249, 2004
 18. Malone PS, Ransley PG, Kiely EM. Preliminary report: The antegrade continence enema. *Lancet* 336: 1217-1218, 1990.
 19. Curry JI, Osborne A, Malone PS. The MACE procedure: experience in the United Kingdom. *J Pediatr Surg* 34(2): 338-340, 1999.
 20. Levitt MA, Falcone RA, Pena A. Pediatric fecal incontinence. In: Ratto C, Doglietto GB, (eds.). *Fecal incontinence diagnosis and treatment*. Springer: Berlin Heidelberg New York ,341-50, 2007
 21. Becmeur F, Demarche M, Lacreuse I, et al. Cecostomy button for antegrade enemas: Survey of 29 patients. *J of Pediatr Surg* 43: 1853-1857, 2008.
 22. Chait PG, Shandling B, Richards HP. The cecostomy button. *J Pediatr Surg* 32: 849-51, 1997.
 23. Marshall J, Hutson JM, Anticich N, et al. Antegrade continence enemas in the treatment of slow-transit constipation. *J Pediatr Surg* 36(8): 1227-30, 2001.
 24. Mousa HM, Maartje M, Van Den Berg, et al. Cecostomy in children with defecation disorders. *Digestive Diseases and Sciences* 51(1): 154-160, 2006.
 25. Yerkes EB, Rink RC, King S, et al. Tap water and the Malone antegrade continence enema: a safe combination? *J Urol* 166: 1476-1478, 2001.
 26. Wong AL, Kravarusic D, Wong SL. Impact of cecostomy and antegrade colonic enemas on management of fecal incontinence and constipation Ten years of experience in pediatric population. *J Pediatr Surg* 43: 1445-1451, 2008.
 27. Youssef NN, Barksdale JE, Griffiths JM, et al. Management of intractable constipation with antegrade enemas in neurologically intact children. *J Pediatr Gastroenterol Nutr* 34: 402-405, 2002.
 28. Curry JI, Osborne A, Malone PS. How to achieve a successful Malone antegrade continence enema. *J Pediatr Surg* 33: 138-141, 1998