

Treatment Outcomes of Auricular Hematoma Using Corrugated Rubber Drains: A Pilot Study

Okolugbo NE

Department of Surgery, Delta State University, Abraka, Delta State, Nigeria

Address for correspondence:
Dr. Okolugbo Nekwu Emmanuel,
Department of Surgery, PMB 1,
Delta State University,
Abraka Delta State, Nigeria.
E-mail: nekouokolugbo@yahoo.com

Abstract

Background: Hematoma of the auricle which is a collection of blood beneath the perichondrial layer of the pinna usually poses a challenge to the otolaryngologist due to its high rate of recurrence after treatment and lack of appropriate material for use as stitch dressing especially, in the developing world. This is a Pilot study in which corrugated rubber drain was used as a stitch dressing after routine incision and drainage (I and D) in patients who presented with auricular hematoma. **Aim:** To determine the effectiveness of corrugated rubber drain in the treatment of auricular hematoma. **Subjects and Methods:** A total of seven patients were seen within a 2 year period in an ENT Ear, nose and throat clinic. Two patients had simple I and D done, one patient had suturing of the auricle between improvised plastic material used for stitch dressing after I and D, while four patients had I and D done and subsequently, a corrugated rubber drain was used as the stitch dressing. **Results:** Two patients treated with simple I and D had recurrence of hematoma, the patient treated with improvised plastic material had pressure necrosis of areas of the pinna which however improved when dressing was removed as soon as symptoms were noticed 2 days post-operatively. Four patients who had I and D and subsequent use of rubber-drain as stitch dressing, had un-eventful recoveries. **Conclusion:** Corrugated rubber tubing drains which are readily available in a developing country like ours has been found very useful as stitch dressing in the management of auricular hematoma.

Keywords: Auricle, Hematoma, Rubber-Drain, Stitch dressing

Introduction

Hematomas of the auricle is a condition in which a collection of blood forms beneath the peri-chondrial layer of the pinna. It usually arise as a result of trauma^[1] or could be spontaneous.

It can also occur in hypertensive patients due to degenerative changes in fibrous wall of blood vessels.^[2]

Hematomas of the ear are caused by shearing forces of blunt trauma. These are usually caused by sports such as boxing and wrestling. The shear force results in separation of perichondrion from the auricular cartilage, tearing blood vessels and causing blood to accumulate between the densely adherent skin-perichondrial layer and the cartilage.^[3]

It poses a challenge to the otolaryngologist in the developing world due to its high rate of recurrence, and lack of appropriate materials for use as stitch dressing.

The diagnosis of auricular hematoma is generally straightforward. The collected blood or serum causes a loss of normal contour on the lateral surface of the auricle which is associated with a history of recent trauma along with possible pain, paresthesias and ecchymosis. Depending on the mechanism of injury, hearing loss or temporal bone fracture could also be considered.^[3]

The aim of our study is to describe the surgical technique used in treating auricular hematoma as well as introduce an easy to use and readily available material as stitch-dressing.

Subjects and Methods

This is a prospective and ongoing study, and seven patients were seen within a 2 year period from June 2009 to May 2011 both at the Delta State University Teaching Hospital Oghara and a private clinic, Manny ENT Specialist clinic Warri, both in Delta State Nigeria.

Access this article online

Quick Response Code:



Website: www.amhsr.org

DOI:
10.4103/2141-9248.117930

Approval was obtained from the research and ethics committee of Delta State University Teaching Hospital Oghara.

The age range of the patients was 15 years to 43 years with a mean of 29 years 3 months. There were six males and one female patient with a male to female ratio of 6:1.

Two of the patients had simple incision and drainage (I and D) done, while one had improvised plastic material used for stitch dressing after routine I and D. The other four patients were managed with the following technique.

At surgery, a curvilinear incision was made along the lateral border of the anti-helix, skin flaps were raised, complete evacuation of the fluid was done, subsequently a corrugated rubber drain was cut into the shape of the portion of the auricle drained, which was then sandwiched between two layers of the rubber drain. Using a 2/0 suture two mattress stitches were then placed across all the layers and a mastoid dressing was placed for 24 h.

The stitch dressing was then removed in 5 days with good results [Figures 1 and 2].

Patients were subsequently followed-up in the clinic for a period of 1 month and no re-accumulation of the hematoma was noted within this period.

Results

The first two patients who were treated with simple I and D had recurrence of symptoms and after the 2nd and 3rd episodes of drainage respectively requested for referral to another center for further management and was lost to follow-up.

The patient who had I and D and stitch dressing with improvised plastic material presented with severe pains and areas of pressure necrosis in the pinna after 24 h, the stitch dressing was immediately removed and wound dressing

was commenced. Patient improved considerably without re-accumulation of hematoma.

Four patients had I and D and subsequent stitch dressing using corrugated rubber-drains, their recovery was un-eventful and they were subsequently followed-up for 4 weeks without re-accumulation [Table 1].

Discussion

Hematoma of the auricle usually arises as a result of bleeding into the cartilage of the ear from trauma, though it could be spontaneous.

Due to its high rate of recurrence, it poses a challenge to the otolaryngologist.

If auricular hematoma is not treated properly, it can progress to abscess formation, chronic scarring and subsequent disfigurement of the auricle, cauliflower ear, development of fibrocartilagenous material due to a stimulation of mesenchymal cells in the perichondrion to produce a new cartilage.^[4]

The proper management is aimed at restoring normal appearance of the ear. This can only be achieved if perichondritis and re-accumulation of the hematoma is avoided.^[2]

Table 1: Outcome of treatment methods

Technique	No of patients	%	Outcome
I & D only	2	28.6	Recurrence
Plastic stitch dressing after I & D	1	14.3	Areas of necrosis which improved later
Corrugated drain (removed after 5 days) as stitch dressing after I & D	4	57.1	Un-eventful recoveries

I & D: Incision and drainage

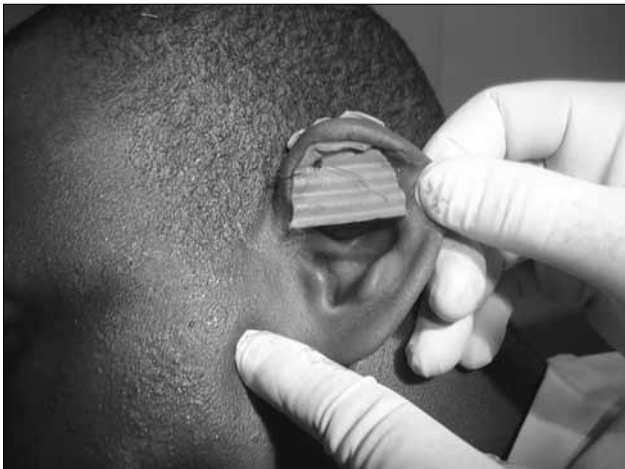

Figure 1: Corrugated rubber drains used as stitch dress

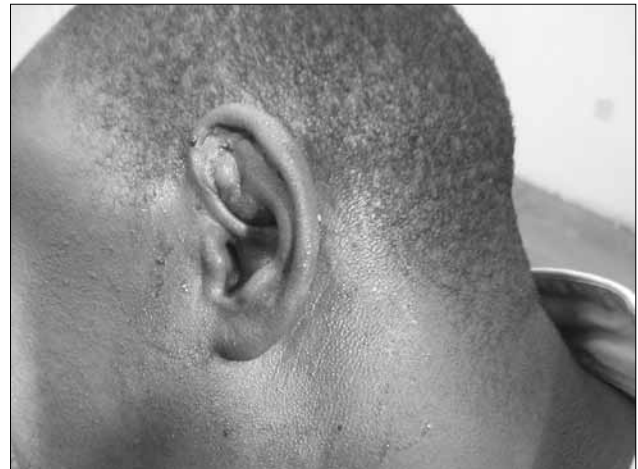


Figure 2: Stitch dressing removed after 5 days

Needle aspiration is still widely used, though not recommended by many sources as initial attempts at aspiration, usually results in re accumulation.^[5] Treatment usually involves the use of two or three mattress sutures with pledgits to allow for chronic drainage.^[6,7]

The goals of treatment are therefore evacuation of the hematoma, prevention of its re-accumulation and avoidance of complications.

Several techniques have been described including a technique using 3/0 silk suture sandwiching the ear between two dental rolls.^[2]

Silicon splints/plaster molds have also been described as being very useful in the management of this condition.^[8] However, this is not locally available and the author had previous challenges in finding an adequate material as previous materials tried after two attempts at aspiration and one I and D which failed almost led to a pressure necrosis of the affected pinna, and the improvised splints made from plastic material had to be removed after 24 h in a previous patient.

In managing four patients who presented with this condition, the author has used a corrugated drain made of flexible soft rubber, which causes no tissue reaction and has the ability to mold to the shape of the pinna. It is also readily available locally and quite affordable.

That two of the patients presented were factory workers does seem to suggest that the incidence is higher amongst factory workers and further research as to why this is so needs to be carried out.

Limitations of the study was the extent of the surgical incision and the amount of evacuation carried out at the initial I and D as this has a role to play on recurrence of symptoms also it should be noted that this is a small series, hence a pilot study.

Conclusion

In the management of auricular hematoma, it was noted that finding an adequate material for use as stitch dressing is a challenge in our environment as I and D on its own has been found to be ineffective. Corrugated rubber drain was suggested as it is readily available and results from this pilot study have been found to be encouraging, though it must be noted that this is an on-going study and the series so far is quite small.

References

1. Jones SE, Mahendran S. Interventions for acute auricular haematoma. *Cochrane Database Syst Rev* 2004;(2):CD004166CD004166
2. Sbaih AS, Khatatbeh WJ. Treatment of auricular hematoma using dental rolls splints. *J royal med services* 2011;18:22-5.
3. Ghanem T, Rasamny JK, Park SS. Rethinking auricular trauma. *Laryngoscope* 2005;115:1251-5.
4. Staindl O, Siedek V. Complications of auricular correction. *GMS Curr Top Otorhinolaryngol Head Neck Surg* 2007;6:3.
5. Ho EC, Jajeh S, Molony N. Treatment of pinna haematoma with compression using leonard buttons. *J Laryngol Otol* 2007;121:595-6.
6. O'Donnell O'donnell BP, Eliezri YD. The surgical treatment of traumatic hematoma of the auricle. *Dermatol Surg* 1999;10:803-5.
7. Vuyk HD, Bakkers EJ. Absorbable mattress sutures in the management of auricular hematoma. *Laryngoscope* 1991;101:1124-6.
8. Choung YH, Park K, Choung PH, Oh JH. Simple compressive method for treatment of auricular haematoma using dental silicone material. *J Laryngol Otol* 2005;119:27-31.

How to cite this article: Okolugbo NE. Treatment outcomes of auricular hematoma using corrugated rubber drains: A pilot study. *Ann Med Health Sci Res* 2013;3:447-9.

Source of Support: Nil. **Conflict of Interest:** None declared.