

# Postoperative Adhesive Intestinal Obstruction from Gossypiboma

Kataria SP, Garg M, Marwah S<sup>1</sup>, Sethi D

Departments of Pathology and <sup>1</sup>Surgery, Post Graduate Institute of Medical Sciences, Rohtak, Haryana, India

**Address for correspondence:**  
Dr. Divya Sethi,  
Department of Pathology, Post  
Graduate Institute of Medical  
Sciences, Rohtak - 124 001,  
Haryana, India.  
E-mail: dr.divyasethi@gmail.com

## Abstract

Retained foreign bodies after surgery is a rare condition which can have medico-legal consequences. Foreign bodies forgotten in the abdomen include towels, artery forceps, pieces of broken instruments or irrigation sets, and rubber tubes. The most common surgically retained foreign body is the laparotomy sponge. Such materials cause foreign body reaction in the surrounding tissue. The complications caused by these foreign bodies are well known, but cases are rarely published because of medico-legal implications. We report a case of 41-year-old female admitted with features of intestinal obstruction and had a previous history of hysterectomy performed 2 months back at another hospital. Pathologists must be aware of this entity and its proper reporting as the cases are liable to go to court. Surgeons must recognize the risk factors that lead to a gossypiboma and take measures to prevent it.

**Keywords:** Acute abdomen, Africa, Foreign body, Gossypiboma, Granuloma, Sponge

## Introduction

Forgotten or missed foreign bodies, such as cotton sponges, gauze, or instruments, after any surgical procedure are considered a misadventure and is associated with several legal problems. The term “gossypiboma” denotes a mass of cotton retained in the body after any intervention.<sup>[1]</sup> This term is derived from the Latin word *Gossypium* for “cotton” and the Swahili word boma for “a place of concealment. Other terms used for gossypiboma include “textiloma,” “cottonoid,” “cottonballoma,” “muslinomas,” or “gauzeoma.” Gossypiboma has been rarely reported in literature and the reports of this technical oversight are the tip of an iceberg because the symptoms of gossypiboma are usually nonspecific and some patients remain asymptomatic and are never discovered or documentation is not enough in some diagnosed cases. Data concerning the incidence of gossypiboma tend to fluctuate and the incidence of gossypiboma is difficult to estimate because of a low reporting rate lest medico-legal implication.<sup>[2]</sup> It is estimated that gossypiboma may occur in 1 out of 300–1000 of all surgical interventions and 1 out of 1000–1500 of intraabdominal operations.<sup>[3]</sup>

The first reported case of malpractice suit on gossypiboma was in 1933.<sup>[2]</sup> We report a case with retained gauze causing adhesive small bowel obstruction following hysterectomy done earlier.

## Case Report

A 41-year-old multiparous lady presented with abdominal pain and vomiting for 3 days and constipation for 2 days. There was history of abdominal hysterectomy 2 months before. All vital signs were normal. A per-abdomen examination revealed distension. All routine investigations were within normal limits. Radiology was inconclusive as the skiagram showed a vague radio-opaque shadow anteriorly. Exploratory laparotomy revealed dense adhesions between the bowel loops. A piece of gauze surrounded by omentum was removed. Grossly, we received omentum densely adherent to gauze piece measuring 10 cm × 8 cm × 2 cm. Microscopically, the sections from omentum revealed extensive granulomatous inflammation with numerous multinucleated foreign body type of giant cells, fibrosis, and chronic inflammatory cell infiltrate comprising lymphocytes, few plasma cells, eosinophils, and macrophages. In the central portion, the whorled stripes of gauze fibers were also seen. Postoperative course was uneventful [Figures 1-3].

## Discussion

Retained surgical sponge or gossypiboma in the abdominal cavity is an infrequent but serious surgical complication that

### Access this article online

#### Quick Response Code:



Website: [www.amhsr.org](http://www.amhsr.org)

DOI:  
10.4103/2141-9248.105677

may lead to medico-legal problems. The condition is often underestimated because case numbers are calculated only on the basis of malpractice claims. Reason of non-reporting of occurrences is the fear of medico-legal repercussions.<sup>[4]</sup>

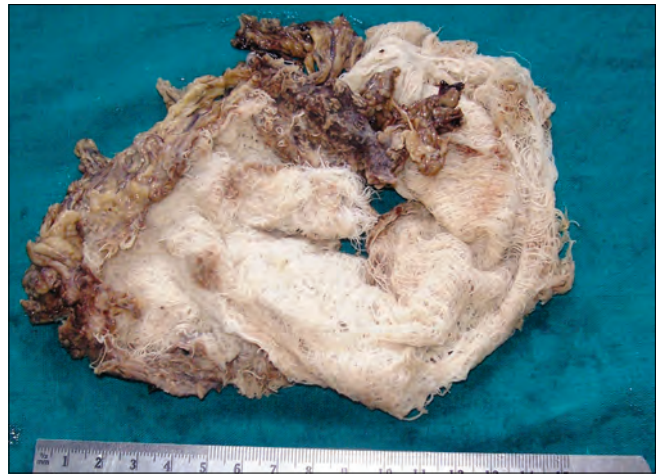It is not easy to say whether cases of gauze left in the abdomen are always due to a real lack of quality on the part of the surgeon or of the theater nurse. It has been reported that the interval between the probable causative operation and the diagnosis of retained gauze may range from 11 days to 28 years.<sup>[5]</sup>

Surgical sponges are made of cotton that does not stimulate any specific biochemical reaction except adhesion and granuloma formation. They may be asymptomatic for a long time. The clinical presentation of gossypiboma may be acute or relatively delayed, and depends on the location of the sponge and the type of reaction. There are two types of pathologic responses to foreign body: The first type is an exudative reaction leading to abscess or granuloma formation and usually leads to early detection and surgical removal and the second type is delayed response manifesting as an aseptic fibrotic reaction to the material and development of a mass.<sup>[6,7]</sup> In the present case, a foreign body granulomatous reaction was observed.

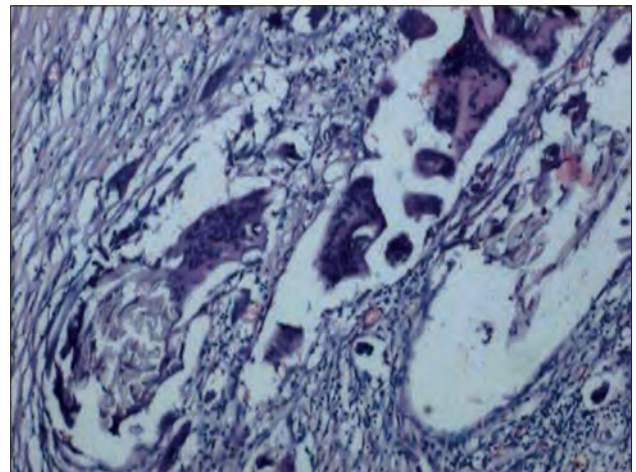
The diagnosis can be made by plain abdominal radiography, ultrasonography, computed tomography (CT), and magnetic resonance imaging (MRI). CT and MRI may reveal comprehensive details about the mass in most cases. However, the CT findings of gossypiboma, particularly in long-standing cases, may be indistinguishable from those of intraabdominal abscess, since air bubbles and calcification of the cavity wall as well as contrast enhancement of the rim may be seen in both conditions. Once gossypiboma is diagnosed, it should be removed. Surgery has been the mainstay in the removal of the foreign bodies for many years. However, some reports recommending alternative methods have recently appeared in the literature, including percutaneous abscess drainage.<sup>[8,9]</sup>

Besides many diagnostic and therapeutic difficulties, gossypiboma also carries some medico-legal implications. The presence of a foreign body inside the patient can be easily proven and the patient may litigate the responsible surgeon because this is an avoidable problem. Moreover, gossypiboma may be misdiagnosed as a malignant tumor and lead to unnecessary invasive diagnostic procedures or extensive extirpative surgery which may result in further complications.<sup>[8,9]</sup> Further, there are always questions as to whether this is a case of negligence or not; if a criminal charge has to be made out; whether any notification to the authorities is required; and lastly whose responsibility it is to inform the investigating agencies, the police or the medical council.

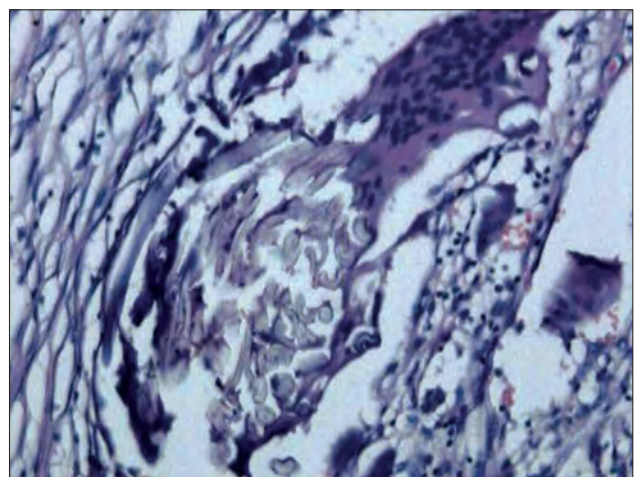
A study reported that emergency surgery, unplanned change in the operation, and body mass index were statistically significant risk factors for retained foreign bodies. Surgeons should place radiologically detectable sponges and towels in



**Figure 1:** Photograph showing the specimen of gossypiboma - gauze adherent to omentum



**Figure 2:** Photomicrograph showing granulomatous inflammation with giant cell reaction (H and E; 100x)



**Figure 3:** Photomicrograph showing giant cell reaction along with whorled stripes of gauze fibers (H and E; 200x)

the surgical site, carefully consider the use of small sponges in large cavities, and perform a methodical wound examination

each and every time before they begin to close the wound. New technologies like electronic article surveillance system and bar coding are being developed that would hopefully decrease the incidence of negligence.<sup>[10,11]</sup>

## Conclusion

Gossypiboma is uncommon, mostly asymptomatic, and hard to diagnose. It should be included in the differential diagnosis of the soft tissue masses with a history of prior operation. Patient-clinician interaction and compliance enhance the possibility of accurate diagnosis. This type of errors will probably never be completely abolished, but the incidence of retained surgical sponge can be reduced to a “minimum” by strict adherence to regulations, especially systematic and rigorous sponge count; this is particularly important during emergency procedures. Although human errors cannot be completely avoided, continuous medical training and strict adherence to rules of the operation room should reduce the incidence of gossypiboma to a minimum.

## References

1. Sharma D, Pratap A, Tandon A, Shukla RC, Shukla VK. Unconsidered cause of bowel obstruction-gossypiboma. *Can J Surg* 2008;51:E34-5.
2. Tarik U, Gokhan DM, Sunay YM, Mahmut A. The Medico-legal importance of Gossypiboma. In: Abstract CD of Poster Presentations. Antalya, Turkey: 2009 [cited 2011 Feb 15]. p. 82-3. Available from: <http://cbuadlitip4.tripod.com/sitebuildercontent/sitebuilderfiles/1165-english.pdf>.
3. Dakubo J, Clegg-Lampsey J, Hodasi W, Obaka H, Toboh H, Asempe W. An intra-abdominal gossypiboma. *Ghana Med J* 2009;43:43-5.
4. Asuquo ME, Ogbu N, Udosen J, Ekpo R, Agbor C, Ozinko M, *et al.* Acute abdomen from gossypiboma: A Case series and review of literature. *Nig J Surg Res* 2006;8:174-6.
5. Grassi N, Cipolla C, Torcivia A, Bottino A, Fiorentino E, Ficano L, *et al.* Trans-visceral migration of retained surgical gauze as a cause of intestinal obstruction: A case report. *J Med Case Reports* 2008;2:17.
6. Kim CK, Park BK, Ha H. Gossypiboma in abdomen and pelvis: MRI findings in four patients. *AJR Am J Roentgenol* 2007;189:814-7.
7. Kaiser CW, Friedman S, Spurling KP, Slowick T, Kaiser HA. The retained surgical sponge. *Ann Surg* 1996;224:79-84.
8. Gencosmanoglu R, Inceoglu R. An unusual cause of small bowel obstruction: Gossypiboma-case report. *BMC Surg* 2003;3:6.
9. Zbar AP, Agrawal A, Saeed IT, Utidjian MR. Gossypiboma revisited: A case report and review of the literature. *J R Coll Surg Edinb* 1998;43:417-8.
10. Gawande AA, Studdert DM, Orav EJ, Brennan TA, Zinner MJ. Risk factors for retained instruments and sponges after surgery. *N Engl J Med* 2003;348:229-35.
11. Aminian A. Gossypiboma: A case report. *Cases J* 2008;1:220.

**How to cite this article:** Kataria SP, Garg M, Marwah S, Sethi D. Postoperative adhesive intestinal obstruction from gossypiboma. *Ann Med Health Sci Res* 2012;2:206-8.

**Source of Support:** Nil. **Conflict of Interest:** None declared.