

# Asyndromic Bilateral Transverse Facial Cleft

Oghale OP, Chris-Ozoko LE (Nee Ebite)<sup>1</sup>

Departments of Anatomy, Delta State University, Abraka, Delta State, Anesthesiology, University of Benin Teaching Hospital Benin City, <sup>1</sup>Anatomy, Delta State University, Abraka, Nigeria

**Address for correspondence:**

Dr. Lilian Ebele Chris-ozoko  
(Nee Ebite),  
Delta State University,  
Abraka, Delta State, Nigeria.  
E-mail: lilyzoks@yahoo.com

## Abstract

Bilateral transverse facial cleft, Tessier no 7 also known as bilateral congenital macrostomia are very rare clefts. We present an eight months old female with bilateral transverse facial cleft, third child of three siblings in a monogamous setting born to parents of Delta origin who resides in effurun Delta state of Nigeria. Mother ingested postinor several times in an attempt to abort pregnancy. Pregnant women should be encouraged to have adequate folic acid diet or supplements.

**Keywords:** Asyndromic, Folic acid, Tessier, Transverse bilateral cleft

## Introduction

Facial cleft or prosopanoschisis are the most common congenital malformations of the head and neck second only to club foot as the most common congenital malformation of the entire body.<sup>[1]</sup> However, transverse facial cleft, Tessier no 7 also referred to as congenital macrostomia are a very rare form of facial clefts. The precise incidence of this atypical cleft is unknown although the frequency is estimated at 1 in 50,000 to 175,000 live births. The occurrence is reported in 0.7 up to 5.4 out of 1,000 cases of cleft lip (cheiloschisis).<sup>[2]</sup> Various classifications with clinical acceptance have been described with Tessiers being the most popular.<sup>[3,4]</sup> He assigned numbers 0-14 to the various clefts with the midline as 0 to demonstrate their location and extent using the mouth, nose and eye sockets as anatomical landmarks. Clefts running southwards through the lower eyelids are facial and those running upwards through the upper eyelids are cranial.

These atypical clefts presents in two forms, unilateral and bilateral with the former having a higher frequency.<sup>[5]</sup> They occur as part of a syndrome and are termed syndromic and rarely as an isolated entity referred to asyndromic clefts. The aetiopathogenic mechanism of congenital macrostomias is unknown but is postulated to be associated

with genetic factors, uncontrolled apoptosis, damage or interruption of the stapedius artery, inadequate arterial supply of the brachial arch during the decisive or crucial period of facial development and the restraining force of amniotic fluid bands. In fact interruption of normal embryonic growth and differentiation of the bones of the face and skull in early gestational life results in a variety of craniofacial abnormalities ranging from facial clefts to Cyclops a severe form of holoprosencephaly incompatible with life.<sup>[6]</sup>

Genetic factors contributing to syndromic facial cleft include cleft lip and palate trans membrane protein 1, GAD 1 and glutamate decarboxylase,<sup>[7]</sup> variation in IRF6 gene seen in Van Der woude syndrome which increases the occurrence of cleft by threefold and MSX1/PVRL1 genes which have been demonstrated on laboratory animals.<sup>[8]</sup> Environmental risk factors include, increasing maternal age, maternal stress, poor maternal nutrition with vitamin A and folic acid deficiency, maternal hypoxia resulting from cigarette smoking, abuse of alcohol, drugs of abuse like cocaine and heroin, anticonvulsant drugs e.g., phenytoin and phenobarbitone, nitrate compounds, organic solvents, and exposure to lead and pesticide. Folic acid deficiency causes facial cleft in laboratory animals and research has shown that folic acid supplementation of 400 micrograms or more per day reduces the risk of isolated cleft lip with or without palate by one third.<sup>[9]</sup>

## Case Report

An 8 months old female infant weighing 6.5 kg brought by her mother to the plastic surgery clinic of the University of Benin Teaching Hospital with complaint of her mouth being wider than normal since birth. A third child in a

**Access this article online**

**Quick Response Code:**



**Website:** [www.amhsr.org](http://www.amhsr.org)

**DOI:**  
10.4103/2141-9248.109480

monogamous setting from Effurun, Delta State, Nigeria. No family history of similar condition. Her mother never smoked nor took alcohol neither was she on any known anticonvulsants; but ingested postinor several times while pregnant because pregnancy was unwanted for financial reasons. No other means of termination was attempted. Although there was no antenatal care, she was delivered by spontaneous vaginal delivery, cried immediately after birth and had normal developmental milestones. Family's source of drinking water was from an untreated borehole. She had no difficulty with feeding and was exclusively breastfed for 2 months.

Close examination revealed a cheerful infant with bilateral transverse facial cleft, Tessiers no 7 also referred to as congenital macrostomia or commissural cleft [Figure 1] which was more evident either on smiling or crying [Figure 2]. Thorough examination and investigation revealed neither associated congenital anomaly nor any coexisting medical illness. Repair by bilateral Z plasty was done by the plastic and burns unit.

## Discussion

Facial cleft remains a source of social anxiety and in the past has lead to the controversial abortions. Akinmoladun, *et al.*, reported a suspected case of infanticide in Ibadan.<sup>[10]</sup> This was however, not the situation with this case here presented who although initially unwanted, was cared for after birth and subsequently brought for repair though her parents

were very poor. Her cleft could largely be ascribed to environmental factors, most likely poor maternal nutrition. Postinor is a progestogen only contraceptive and no adverse effect of progestogens on the foetus have been demonstrated in epidemiological studies. It has been observed that most children with congenital abnormalities who present to the teaching hospital are from oil producing areas, notably Delta state of Nigeria.

In a study to investigate the "antenatal determinants of oro-facial cleft in southern Nigeria" Omo-Aghoja, *et al.*, found a prevalence rate of 1.35% which is a prevalence higher than the overall world wide prevalence and those from other regions they also recorded a number of risk factors that were associated with the risk of development of cleft lip and palate; they include paternal age >40 years, maternal age >35 years, genetic/family history, low socioeconomic status, alcohol consumption and indulgence in the intake of herbal medications in pregnancy.<sup>[11]</sup> This index case was from a low socio economic class the veracity of use of herbal medications in pregnancy could not be determined; mother was in her early thirties while the father was in his late thirties.

Cosmetic distortion of the face is a threat to quality of life leading to reduced self esteem and confidence especially in school age girls.<sup>[12]</sup> This condition is highly amenable to surgery and organisations like "Smile Train" have been involved in helping children born with facial cleft to bear the financial cost of repair in Nigeria. Because folic acid deficiency has been demonstrated to cause facial cleft, we encourage pregnant women to have adequate folic acid supplements and or increase intake of leafy vegetables, citrus fruits and beans which are a rich source of folic acid readily available and affordable irrespective of status.

## Acknowledgment

We sincerely thank Dr. Oludiran, head of department of plastic and reconstructive surgery, University of Benin Teaching Hospital for his kind permission to take photographs for this report.

## References

1. Habel A, Sell D. Management of cleft lip and palate. *Arch Dis Child* 1996;74:360-6.
2. Ranta R, Rintala A. Oblique lateral oro-ocular facial cleft. Case report. *Int J Oral Maxillofac Surg* 1988;17:186-9.
3. Tessier P. Anatomical classification of facial, cranio-facial and latero-facial clefts. *J Maxillofac Surg* 1976;4:69-92.
4. David DJ, Moore MH, Cooter RD. Tessier clefts revisited with third dimension. *Cleft Palate J* 1989;26:163-85.
5. Daghan I, Mustafa T, Mehmeter B. Tessier no 7 unilateral cleft: Two case reports. *Eastern J Med* 2001;16:90-3.
6. Otuaga PO, Eweka AO, Oni AO, Ebite LE. Cyclops deformity in Benin city, Nigeria: A case report. *Internet J Neurol* 2008;10:33-6.
7. Kanno K, Suzuki Y, Yamanda A, Aoki Y, Kune S, Masubara Y.

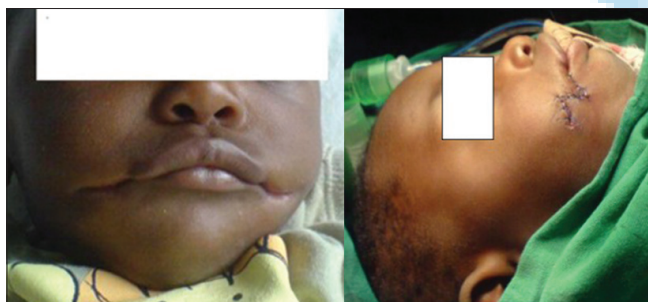

Figure 1: Baby sleeping (pre op)

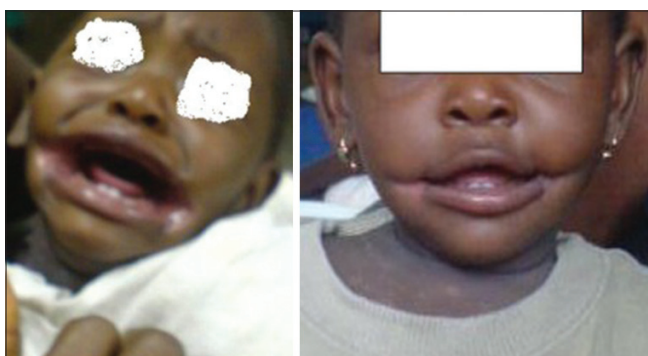


Figure 2: Baby laughing (pre op)

- Association between non syndromic cleft lip with or without cleft palate and glutamic acid decarboxylase 67 gene in the Japanese population. *Am J Med Genet A* 2004;127A1:11-6.
8. Cox TC. Taking it to the maximum: Genetic and developmental mechanisms co-ordinating midfacial morphogenesis and dysmorphology. *Clin Genet* 2004;65:163-76.
  9. Wilcox AJ, Lie RT, Solvoll K, Taylor J, McConaughy DR, Abyholm F, *et al.* Folic acid supplements and the risk of facial clefts: A national population-based control study. *BMJ* 2007;334:464.
  10. Leonard BJ, Brust JD, Abrahams G, Sielaff B. Self-concept of children and adolescents with cleft lip and/or palate. *Cleft Palate Craniofac J* 1991;28:347-53.
  11. Omo-Aghoja VW, Omo-Aghoja LO, Ugboko VI, Obuekwe ON, Saheeb BD, Feyi-Waboso P, *et al.* Antenatal determinants of oro-facial clefts in Southern Nigeria. *Afr Health Sci* 2010;10:31-9.
  12. Akinmoladun VI, Owotade FJ, Afolabi AO. Bilateral transverse facial cleft as an isolated deformity: Case report. *Ann Afr Med* 2007;6:39-40.

**How to cite this article:** Oghale (Nee Ebite) OP, Chris-Ozoko LE. Asyndromic Bilateral Transverse Facial Cleft. *Ann Med Health Sci* 2013;3:122-4.

**Source of Support:** Nil. **Conflict of Interest:** None declared.



#### Announcement

#### iPhone App



Download  
iPhone, iPad  
application

FREE

A free application to browse and search the journal's content is now available for iPhone/iPad. The application provides "Table of Contents" of the latest issues, which are stored on the device for future offline browsing. Internet connection is required to access the back issues and search facility. The application is Compatible with iPhone, iPod touch, and iPad and Requires iOS 3.1 or later. The application can be downloaded from <http://itunes.apple.com/us/app/medknow-journals/id458064375?ls=1&mt=8>. For suggestions and comments do write back to us.