

Ruptured Seminoma of Undescended Testis Presenting as Acute Abdomen: Case Report with Literature Review

Singh P, Bajaj K¹, Kaur R, Mishra A¹, Riar HK¹

Departments of Radiodiagnosis and Medicine, Maharishi Markandeshwar Institute of Medical Sciences and Research, Mullana (Ambala), Haryana, ¹Surgery and Anaesthesia, Dayanand Medical College and Hospital, Ludhiana, Punjab, India

Address for correspondence:

Dr. Paramdeep Singh,
Department of Radiodiagnosis,
MM Institute of Medical Sciences and
Research, Maharishi Markandeshwar
University, Mullana (Ambala),
Haryana, India.
E-mail: paramdeepdoctor@gmail.com

Abstract

We present a case of a 28-year-old male who presented with acute abdomen and was later diagnosed to be having ruptured intra-abdominal seminoma with hemoperitoneum, where the pre-operative diagnosis was not made. Laprotomy and complete excision were carried out. Rupture of intra-abdominal testicular seminoma is a rare cause of acute abdomen and hemoperitoneum. The pre-operative diagnosis is often difficult because history of cryptorchidism is not provided and imaging findings may be non-specific. In a male patient with acute abdomen and without previous history of orchidectomy, a testicular aetiology of acute abdomen should be kept as the differential diagnosis.

Keywords: Acute abdomen, Cryptorchidism, Intra-abdominal seminoma

Introduction

Acute abdomen may be due to a variety of diseases that may involve the gastrointestinal system, biliary tract, solid viscera or genitourinary system. Identification of patients who require surgery is important for timely management. On account of the substantial overlap of symptoms and signs in an acute abdomen, the clinical accuracy for specific diagnosis is low, ranging from 50 to 65%.^[1] Undescended testis has an incidence of one in 500 men, and can be associated with complications like malignancy, infertility, torsion and hemorrhage. It has a 40-times higher risk of malignant transformation, most commonly seminoma, as compared with scrotal testis.^[2] Rupture of intra-abdominal seminoma is very rare. Only two cases have been reported worldwide, till date. The radiological diagnosis is often difficult because history of cryptorchidism is not provided.^[3,4]

Case Report

A 28-year-old man was admitted in the emergency department,

with the chief complaint of sudden, severe, continuous abdominal pain of one day duration that was precipitated by lifting a heavy load. Initially, pain was localized to the right lower abdomen, but later became diffuse in nature. He had no past history of surgery or any other disease. On admission, his blood pressure was 110/70 mmHg, and his pulse rate was 106 beats/min. There was generalized abdominal tenderness with guarding and rigidity. His plain chest roentgenogram showed no abnormality. Abdominal radiograph taken in the erect posture did not show any free air under domes of diaphragm. His hemoglobin concentration was 10.8 g/dL, and the white blood cell count was elevated to 15,000/mm³. Provisional clinical diagnosis of acute appendicitis with perforation was made. Scrotal examination and tumoral markers were not done. Ultrasound abdomen revealed a significant amount of free fluid with echoes in peritoneal cavity and an echogenic organized fluid collection in pelvis suggesting a hematoma. Solid viscera were normal. No evidence of appendicular pathology was seen. Fluid resuscitation was started immediately. Contrast-enhanced computerized tomography scan was done 12 h after admission, which, in addition to depicting the large pelvic hematoma, showed a suspicious pelvic mass with active bleeding and significant high-density ascites [Figure 1]. Rest of the scan was unremarkable. The patient was immediately moved to the operating room. At laparotomy, there was about 4000 mL of mixed free and clotted blood. In the right iliac fossa, an actively bleeding testicular mass, 7 cm × 7 cm in size, which was ruptured at the superior pole was found. The mass was

Access this article online

Quick Response Code:



Website: www.amhsr.org

DOI:
10.4103/2141-9248.109467

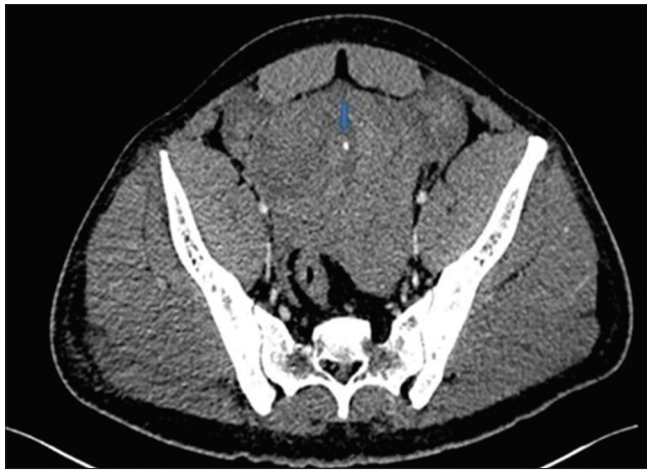


Figure 1: Axial computerized tomography section at the level of the pelvis showing high-density fluid with a suspicious heterogeneous mass on the right side. Punctate hyperdensity (arrow) represents an active bleeding

excised [Figure 2]. No other mass was found and the solid viscera, mesentery and intestines were found to be normal. Post-operative management included regular monitoring of vitals, IV fluids, antibiotics and dressings. The post-operative period was uneventful. The patient was discharged 7 days after the operation. Histopathological examination proved the mass to be a testicular seminoma.

Discussion

Although there is a low overall incidence of cryptorchidism (<1%), a history of testicular maldescent is present in 3.5-14.5% of patients with testicular tumors.^[5] Approximately 90% of tumors in undescended testis are seminomas, particularly those that occur in the abdominally located testis.^[5] Compared with developing countries, cryptorchidism in the adult population is rare in developed countries due to the practice of elective orchidopexy in children aged under 2 years old and orchiectomy in post-puberal patients.^[6] The present case did not have any history of surgery. The peak incidence of malignancy in undescended testes is in the third or fourth decade of life. Clinically, patients with malignant intra-abdominal testis can be asymptomatic or may present with symptoms mimicking appendicitis, incarcerated hernia, urinary frequency or dysuria from mass effect on bladder or as acute abdomen due to torsion and rupture with hemorrhage. Radiological and pre-operative diagnosis of complications such as torsion or rupture is often difficult because, generally, the history of cryptorchidism is not provided and imaging findings can be non-specific.

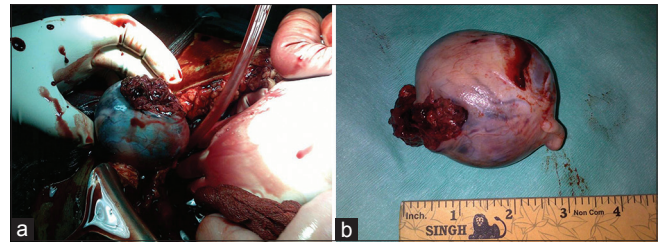


Figure 2: (a) Testicular mass during operation; (b) Testicular mass after resection

In a male patient with undescended testis, and presence of a retroperitoneal mass on imaging, testicular malignancy should be suspected.^[7] A definitive diagnosis and treatment usually involve operative exploration and resection of the mass. If there is a probability of a testicular tumor, the tumoral markers might bring further evidence and also will be of use for post-operative management and follow-up. In conclusion, physical examination of the external genitalia should not be overlooked in male patients presenting with acute abdomen, as it could be a pointer to the diagnosis.

References

1. Balthazar EJ, Chako AC. Computerized tomography in acute gastrointestinal disorders. *Am J Gastroenterol* 1990;85:1445-52.
2. Fonkalsrud EW. Current management of undescended testis. *Semin Pediatr Surg* 1996;5:2-7.
3. Batata MA, Whitmore WF Jr, Chu FC, Hilaris BS, Loh J, Grabstald H, *et al.* Cryptorchidism and testicular cancer. *J Urol* 1980;124:382-7.
4. Küçük HF, Dalkiliç G, Kuroğlu E, Altuntaş M, Barişik NO, Gülmen M. Massive bleeding caused by rupture of intra-abdominal testicular seminoma: Case report. *J Trauma* 2002;52:1000-1.
5. Woodward PJ. Seminoma in an undescended testis. *Radiology* 2004;231:388-92.
6. Cristián PC, Cristóbal B, Maccioni R. New case of an intra-abdominal testicular seminoma in an adult. *Actas Urol Esp* 2007;31:160-3.
7. Miller FH, Whitney WS, Fitzgerald SW, Miller EI. Seminomas complicating undescended intraabdominal testes in patients with prior negative findings from surgical exploration. *AJR Am J Roentgenol* 1999;172:425-8.

How to cite this article: Singh P, Bajaj K, Kaur R, Mishra A, Riar HK. Ruptured Seminoma of Undescended Testis Presenting as Acute Abdomen: Case Report with Literature Review. *Ann Med Health Sci Res* 2013;3:108-9.

Source of Support: Nil. **Conflict of Interest:** None declared.