

An Alternative Instrument for Making Entry Point for Elastic Intramedullary Nail

Sharma P, Meena S, Gangary S¹, Chowdhury B

Department of Orthopedics, All India Institute of Medical Sciences, ¹ESI Hospital, Okhla, New Delhi, India

Address for correspondence:

Dr. Sanjay Meena,
Department of Orthopedics,
All India Institute of Medical
Sciences, New Delhi - 110 029, India.
E-mail: sanjaymeena@hotmail.com

Abstract

Femoral shaft fractures are common in children and are increasingly being treated with elastic intramedullary nail. We outline an instrument we have used successfully to make an entry point for placement of elastic nail.

Keywords: Elastic nailing, Fracture shaft femur, Technique

Introduction

Femoral shaft fracture is a common major pediatric orthopedic injury that most orthopedic surgeons treat routinely.^[1] These fractures have traditionally been treated nonoperatively with early spica cast or a period of traction followed by application of hip spica cast until the fracture unites. Internal fixation of pediatric shaft femur fracture by elastic stable intramedullary nail is gradually replacing conservative treatment^[2] and over the past two decades the advantages of fixation of pediatric femoral shaft fractures by elastically stable intramedullary nails have been increasingly accepted.^[3] The most common complication with titanium elastic nail is skin irritation at nail entry point due to protruded nail. Other complications include mal-union of fracture, shortening and lengthening of a limb due to inadequate axial and bending stability in comminuted, spiral and oblique fracture. Stiffness of knee and painful bursa formation over the nail tip are other complications.^[4,5] Despite all these complications, the flexible nail is being increasingly used because it allows early mobilization of patient, the complications are minor and could be addressed easily and that it gives freedom from cumbersome conservative management appliance and necessities such as hip spica cast, thomas splint, tractional devices and prolonged bed recumbency. Furthermore, the elastic nail insertion technique is easy with short learning curve and complication profile is favorable when compared with plating, a solid antegrade nail, and external fixator in skeletally immature patient.^[6]

Titanium flexible intramedullary nail is usually inserted in a retrograde manner. The entry points are made just proximal to the growth plate in distal metaphysis of the femur each on medial and lateral side. Conventionally, the entry point is made with a 4.5 or 3.2 mm drill bit or using an awl, 2 cm proximal to the growth plate in the distal metaphyseal area of the femur.^[6,7] Making an oblique entry point with a straight 4.5 mm drill bit is difficult because it jumps over the cortex and it may result in missing of desired correct site of entry point and sometime may lead to breakage of drill bit. The repeated use of the awl may make it tip blunt, and one may find difficulty in making the entry point with the awl. Sometimes, inadvertent fall of instrument on the floor from the operation table makes the instrument unsterile, and this may lead the surgeon into temporary despair. The awl may not be available in rural setting. In this scenario, we improvised a method to make a correct oblique entry point without any difficult. We describe here an instrument we have used successfully to make an entry point for placement of elastic nail.

Technical Note

We suggest the use of trocar of the vacuum suction drain to make the entry point. The trocar can be attached to the T-handle and with a gentle rotatory movement a relatively longitudinal entry point can be made, which facilitate easy nail insertion [Figures 1 and 2]. The trocar is curved, sharp and of adequate thickness that make it easier for the surgeon to make the entry hole. The children's bones are soft and can be penetrated easily by the sharp trocar. Owing to a disposable nature of the needle, every time a fresh trocar with a sharp tip can be used.

Discussion

The advantages of using this new instrument are as follows; better control over making entry point due to solid construct

Access this article online

Quick Response Code:	Website: www.amhsr.org
	DOI: *****

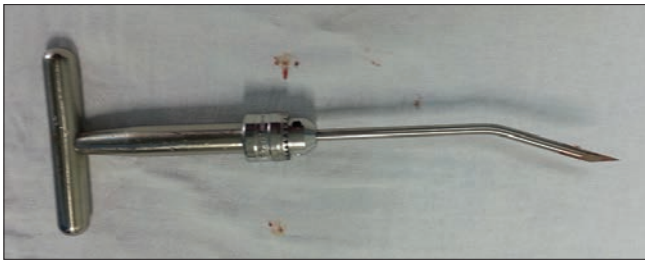


Figure 1: Curved trocar of vacuum suction set

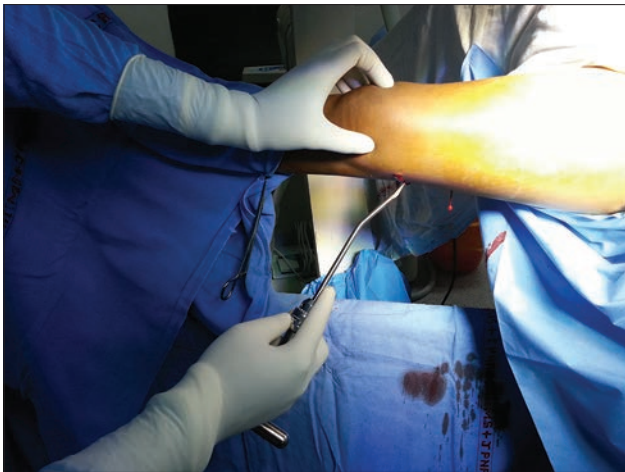


Figure 2: Entry point being created by attaching the tip to the T handle

and symmetrical width of its whole length, cost effective, no chances of slipping and break down of drill bit, time saving because no need of using drill bit prior to awl, easily available

in even peripheral operation theatres, light weight so durable as comparative to drill assembly and no need of power and battery as manual power used for working without any maintenance due to disposable nature.

References

1. Hosalkar HS, Pandya NK, Cho RH, Glaser DA, Moor MA, Herman MJ. Intramedullary nailing of pediatric femoral shaft fracture. *J Am Acad Orthop Surg* 2011;19:472-81.
2. Flynn JM, Schwend RM. Management of pediatric femoral shaft fractures. *J Am Acad Orthop Surg* 2004-Oct; 12:347-59.
3. Houshian S, Gøthgen CB, Pedersen NW, Harving S. Femoral shaft fractures in children: Elastic stable intramedullary nailing in 31 cases. *Acta Orthop Scand* 2004;75:249-51.
4. Ligier JN, Metaizeau JP, Prévot J, Lascombes P. Elastic stable intramedullary nailing of femoral shaft fractures in children. *J Bone Joint Surg Br* 1988;70:74-7.
5. Flynn JM, Hresko T, Reynolds RA, Blasier RD, Davidson R, Kasser J. Titanium elastic nails for pediatric femur fractures: A multicenter study of early results with analysis of complications. *J Pediatr Orthop* 2001;21:4-8.
6. Spiegel DA, Ganley TJ, Flynn JM. Titanium elastic nailing of pediatric femur fractures. *Oper Tech Orthop* 2005;15:326-30.
7. Metaizeau JP. Stable elastic intramedullary nailing for fractures of the femur in children. *J Bone Joint Surg Br* 2004;86:954-7.

How to cite this article: ???

Source of Support: Nil. **Conflict of Interest:** None declared.