

Hydatid Cyst of Fallopian Tube

Jafarian A, Fakhar N, Parsaei R

Department of General Surgery, Tehran University of Medical Sciences, Tehran, Iran

Address for correspondence:

Dr. Reza Parsaei,
Department of General Surgery,
Imam Khomeini hospital,
Keshavarz Boulevard, Tehran, Iran.
E-mail: parsaeir@irimc.org

Abstract

Echinococcosis is a common disease in the Middle East region and is in the differential diagnosis of cystic lesions in patients of this area. Liver and lung are commonly involved. Infection of unusual sites can cause difficulties in diagnosis. Here, we present a patient with echinococcal cyst of the fallopian tube. She had abdominal pain and a cystic lesion in adnexa was found by imaging. She underwent surgery and diagnosis of echinococcosis was established.

Keywords: Echinococcosis, Fallopian tube, Hydatid cyst

Introduction

Echinococcosis is a common disease in Middle East and Mediterranean countries. It is in the differential diagnosis of cystic lesions in patients from these areas. Hydatid cyst is an infection with metacestodes of tapeworm *Echinococcus granulosus* that is transmitted through ingestion of parasite eggs in contaminated vegetables and soil. The oncospheres are hatched from eggs and enter circulation to develop fluid filled cysts in target organs.^[1] Common involved organs are liver and lung but infection of other less common organs have been reported and since clinical and imaging features of echinococcosis are nonspecific, this can lead to a diagnostic challenge. Here, we present a patient with echinococcal cyst of the fallopian tube. She had abdominal pain and imaging showed cystic lesions in the liver and adnexa. Definite diagnosis was made only after surgery.

Case Report

A 40-year-old woman presented to our outpatient clinic with a 1 year history of epigastric pain. She also reported intermittent pain in the lower abdomen.

Physical examination revealed no abnormal finding. Routine lab data was normal.

An upper gastrointestinal endoscopy had been performed that showed nonspecific gastritis. 3 months before her visit to our

clinic, she presented to an emergency department with the complaint of fever and pelvic pain. An abscess in left pelvis was diagnosed and percutaneous drainage was performed.

Abdominal ultrasonography showed a cystic lesion measuring 95 × 85 mm in the right lobe of the liver and a cystic lesion of 50 × 40 mm in right adnex. Abdomenopelvic computed tomography (CT) scan with double contrast was performed for further investigation and found a large homogenous cyst in the liver with enhancement of the cyst wall compatible with Type I echinococcal cyst. In addition, a cystic lesion was found in right adnex [Figures 1 and 2].

The patient underwent surgery, the liver cyst was excised, the cavity was irrigated with hypertonic saline and omentoplasty was performed. The uterus and adnexa was inspected and a mass was found in right fallopian tube. Salpingectomy was performed and incision of the fallopian tube revealed a cyst containing a clear fluid and white lining typical for germinative layer of echinococcal cyst [Figure 3].

Postoperative course of the patient was uneventful. She was discharged from hospital 2 days later. Oral albendazole 400 mg/d was prescribed. Pathology report confirmed the diagnosis of echinococcal cyst in both liver and fallopian tube.

Discussion

Echinococcosis mostly involves liver and lung. In <20% of patients involvement of other organs happen. Most extrahepatic and extrapulmonary sites are kidney, spleen and peritoneum.^[2,3] Hydatid cyst of the fallopian tube is extremely rare, <20 reports could be found in Med Line database. As in other organs of the abdomen and pelvis, hydatid cyst of fallopian tube usually causes nonspecific symptoms due to its compressive effect. Bacterial superinfection and abscess formation may also

Access this article online

Quick Response Code:	Website: www.amhsr.org
	DOI: *****

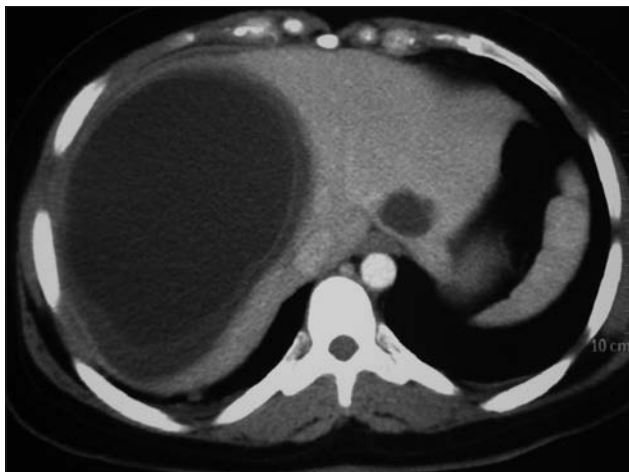

Figure 1: Computed tomography scan demonstrating large homogenous liver cyst

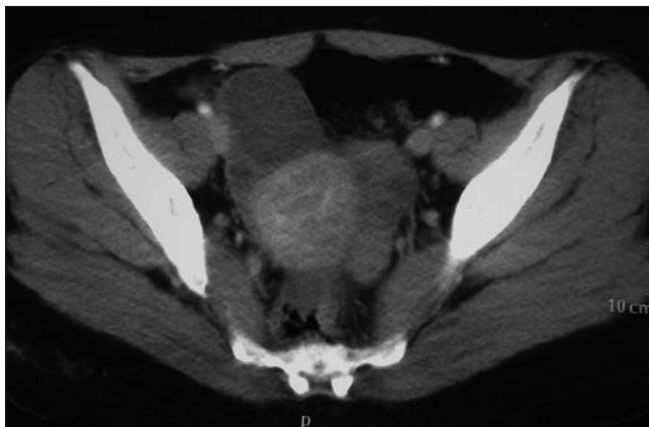


Figure 2: Adnexal cyst demonstrated in the pelvic computed tomography scan

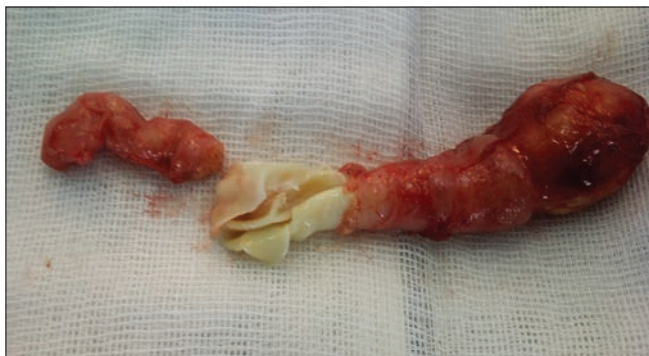

Figure 3: Excised fallopian tube containing a hydatid cyst

happen and can be the presenting feature of hydatid cyst. It is highly probable that previously diagnosed pelvic abscess in our patients was a superinfected hydatid cyst in the left adnex.

Preoperative diagnosis is helpful for taking precautions to prevent spillage or considering puncture-aspiration-injection-reaspiration treatment. Serologic test are helpful, but available commercial kits have not high specificity and sensitivity.^[4] Imaging plays

a major role in diagnosis of hydatid disease; both CT scan and magnetic resonance imaging can assist in diagnosing hydatid disease, especially in the liver.^[2,5] Four types of imaging appearances are defined for hydatid cysts: Simple cyst with noninternal architecture, cyst with daughter cysts that shows floating membranes and septa, calcified cyst and cysts with complications like rupture of superinfection.^[2,5] Diagnosing hydatid disease in extrahepatic sites by imaging is however difficult since these features have similarities with other benign or malignant lesions.^[2] Signs and symptoms of hydatid disease are also nonspecific, so diagnosis of extrahepatic hydatid disease is often suspected by considering epidemiologic factors and prevalence of echinococcosis in patient's residence area. This diagnosis must be considered especially when a concomitant liver or lung cyst exists. If hydatid cyst involves solely a site that is uncommon for echinococcosis, it will be challenging to make the diagnosis before surgical excision. In our patient, as many reported pelvic hydatid cysts,^[6-8] symptoms warranted surgical excision and intraoperative findings led to a diagnosis. Surgical resection is the treatment of choice. Avoiding spillage during surgery is important to prevent recurrence or anaphylaxis. Albendazole is a safe and effective adjuvant therapy and should be administered to minimize recurrence rate after surgery.^[9]

Hydatid cyst must be considered in differential diagnosis of every cystic lesion in patients from endemic areas.

References

1. McManus DP, Zhang W, Li J, Bartley PB. Echinococcosis. *Lancet* 2003;362:1295-304.
2. Polat P, Kantarci M, Alper F, Suma S, Koruyucu MB, Okur A. Hydatid disease from head to toe. *Radiographics* 2003;23:475-94.
3. Cöl C, Cöl M, Lafçi H. Unusual localizations of hydatid disease. *Acta Med Austriaca* 2003;30:61-4.
4. Zhang W, Wen H, Li J, Lin R, McManus DP. Immunology and immunodiagnosis of cystic echinococcosis: An update. *Clin Dev Immunol* 2012;2012:101895.
5. Marrone G, Crino' F, Caruso S, Mamone G, Carollo V, Milazzo M, et al. Multidisciplinary imaging of liver hydatidosis. *World J Gastroenterol* 2012;18:1438-47.
6. Uchikova E, Pehlivanov B, Uchikov A, Shipkov C, Poriazova E. A primary ovarian hydatid cyst. *Aust N Z J Obstet Gynaecol* 2009;49:441-2.
7. Alimohamadi S, Dehghan A, Neghab N. Primary bilateral intrapelvic hydatid cyst presenting with adnexal cystic mass: A case report. *Acta Med Iran* 2011;49:694-6.
8. Geramizadeh B. Unusual locations of the hydatid cyst: A review from Iran. *Iran J Med Sci* 2013;38:2-14.
9. Arif SH, Shams-Ul-Bari, Wani NA, Zargar SA, Wani MA, Tabassum R, et al. Albendazole as an adjuvant to the standard surgical management of hydatid cyst liver. *Int J Surg* 2008;6:448-51.

How to cite this article: ????

Source of Support: Nil. Conflict of Interest: None declared.

K.S. Micro-Implant Placement Guide

Sharma K, Sangwan A¹

Departments of Orthodontics and Dentofacial Orthodontics and ¹Department of orthodontics and dentofacial orthopaedics, Rajasthan Dental College and Hospital, Jaipur, Rajasthan, India

Address for correspondence:

Dr. Anu Sangwan,
C/o Dr. Kuldeep Sharma,
Plot No. 287, Tagore Nagar,
Main Ajmer Road, Near
Heerapura School, Heerapura,
Jaipur - 302 021, Rajasthan, India.
E-mail: drasangwan@gmail.com

Abstract

A one of the greatest concerns with orthodontic mini-implants is risk of injury to dental roots during placement is, especially when they are inserted between teeth. Many techniques have been used to facilitate safe placement of interradicular miniscrews. Brass Wires or metallic markers are easy to place in the interproximal spaces, but because their relative positions may be inconsistent in different radio-graphic views, they are not always accurate. K.S. micro implant placement guide suggested in this article is simple design and easy in fabrication, required minimal equipment for fabrication and does not disturb the existing appliance system, clearly located in the radiograph and the mini-screw can be easily inserted through the guide reducing the chance of implant misplacement.

Keywords: Orthodontic, Mini-implants, microimplant jig, microimplant guide, microimplant positioning, miniscrew

Introduction

Mini-screws offer skeletal anchorage and having many clinical uses and advantages, available in varied sizes and shapes, there are various sites for placement according to uses. Micro-implants are ease of insertion and removal, the ability to load forces immediately and rapid healing. A one of the greatest concerns with orthodontic mini-implants is a risk of injury to dental roots during placement is, especially when they are inserted between teeth.^[1] Placement of a mini-screw too close to the root can also result in insufficient bone remodeling around the screw and transmission of occlusal forces through the teeth to the screw, which can lead to implant failure.^[2] Even though, periodontal structures can heal after being injured by temporary orthodontic anchorage devices,^[3] it is important to carefully select insertion sites using the clinical and radiographic evaluation of their anatomical details.

Many techniques have been used to facilitate safe placement of interradicular mini-screws. Brass wires^[4] or metallic markers^[5] are easy to place in the interproximal spaces, but because their relative positions may be inconsistent in different radiographic views, they are not always accurate. K.S. micro-implant placement guide suggested in this article is a simple design and

easy in fabrication, required minimal equipment for fabrication and does not disturb the existing appliance system, clearly located in the radiograph and the mini-screw can be easily inserted through the guide reducing the chance of implant misplacement.^[6]

K.S. Micro-Implant Placement Guide Fabrication

The wire guide is fabricated using round 0.018 or 0.020 (A.J. Wilcock) or 17 × 25 or 19 × 25 stainless steel wire [Figure 1]. A helix of 2–3 mm diameter is made at the center of the wire [Figure 2]. The appropriate length is determined by the desired mini-screw insertion point (generally 5–6 mm apical to the alveolar crest). After vertical height is determined, continues vertical loop made until measured length and one or two horizontal bends are the place at the level of the adjacent brackets.

Here, we are using multiple loops helix as they are helpful in area determination as compared to single helix and also if we use thickened wire than stability will be more, as the gap between the slots will be filled.

Clinical Procedure

The wire guide is secured with a bracket or tube by ligature or an “O” ring. The mini-screw is inserted through the helix of the guide in the desired direction. The wire guide is disengaged after three-fourth of the mini-screw is driven in and then the mini-screw is completely inserted. Placement accuracy

Access this article online

Quick Response Code:	Website: www.amhsr.org
	DOI: *****

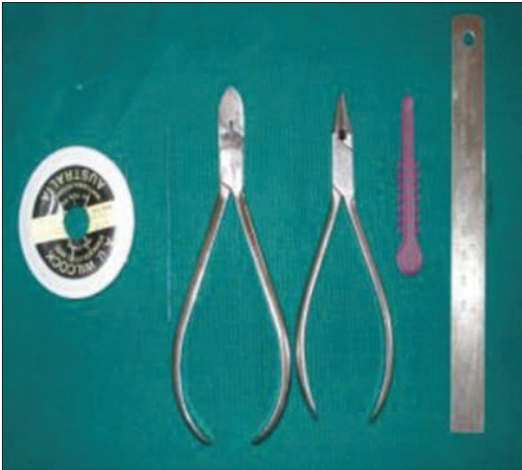

Figure 1: Explains fabrication armementarium



Figure 2: K.S. micro-implant placement guide

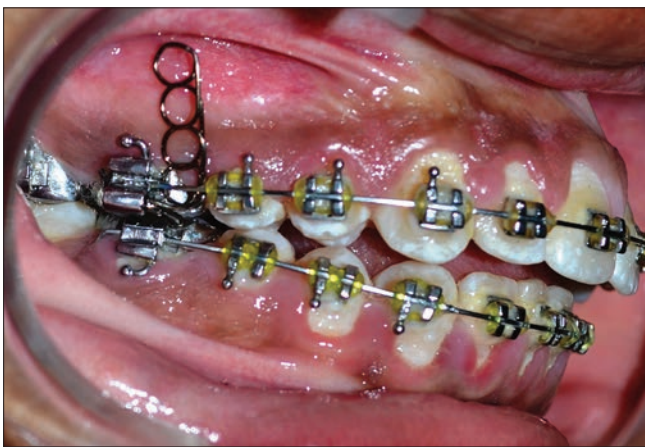


Figure 3: Clinical application

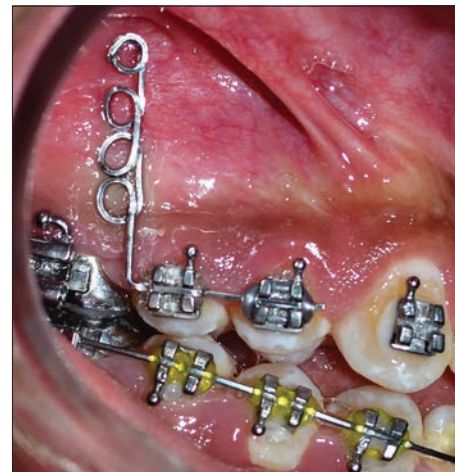

Figure 4: Clinical applications

is reconfirmed clinically [Figures 3 and 4]. A periapical radiograph is taken to confirm the correct position of the helixes for the mini-screw insertion the intraoral periapical radiograph here shown was taken by cone-beam paralleling technique.

Discussion

The use of mini-implants in orthodontics has phenomenally increased in the last few years due to the clear advantage of their clinical efficiency in anchorage control.

The critical issue about mini-implants is the location of the implant. It is very important to place the implant in a location that does not damage adjacent roots or other vital tissues. There are various methods mentioned in the literature; e.g. using a mesh placed in an interradicular area and radiographed to use as a guide to implant placement, or custom-made soldered wire guides placed both buccally and lingually and then radiographed to use as a guide.

The technique mentioned in the present article is simple and accurate because the implant is inserted through the helix of the guide, hence less chance for it to be misplaced. The existing

orthodontic appliance is not disturbed and the implant guide can be disengaged without any difficulty.

We can also use rectangular wire and we can place one loop over another to increase the thickness so that angulation does not get changed. Here reason for using wire .018 is because if we use .014 the stability will get compromised.

Conclusion

K.S. micro-implant placement guide is simple in design, easy to fabricate, inexpensive, supportive and can be used with a variety of mini-screws. Here, we used 0.018 wire as it engages the bracket slots properly hence giving better stability. Further we are researching on it for betterment like changing the gauge and increasing the loop thickness. However, still lots of modifications are yet to be searched.

References

1. Choi HJ, Kim TW, Kim HW. A precise wire guide for positioning interradicular miniscrews. *J Clin Orthod* 2007;41:258-61.

2. Kuroda S, Yamada K, Deguchi T, Hashimoto T, Kyung HM, Takano-Yamamoto T. Root proximity is a major factor for screw failure in orthodontic anchorage. *Am J Orthod Dentofacial Orthop* 2007;131:S68-73.
3. Asscherickx K, Vannet BV, Wehrbein H, Sabzevar MM. Root repair after injury from mini-screw. *Clin Oral Implants Res* 2005;16:575-8.
4. Kyung HM, Park HS, Bae SM, Sung JH, Kim IB. Development of orthodontic micro-implants for intraoral anchorage, *J. Clin. Orthod.* 37:321-328, 2003.
5. Carano A, Velo S, Leone P, Siciliani G. Clinical applications of the Miniscrew Anchorage System, *J. Clin. Orthod.* 39:9-24, 2005.
6. Ludwig B, Glasl B, Bowman SJ, Wilmes B, Kinzinger GS, Lisson JA. Anatomical guidelines for miniscrew insertion: Palatal sites. *J Clin Orthod* 2011;45:433-41.

How to cite this article: ????

Source of Support: Nil. Conflict of Interest: None declared.