

Fine Needle Aspiration Cytology in Pediatric Age Group with Special Reference to Pediatric Tumors: A Retrospective Study Evaluating Its Diagnostic Role and Efficacy

Prathima S, Suresh TN, Harendra Kumar ML, Krishnappa J¹

Departments of Pathology, and ¹Pediatrics, Sri Devaraj Urs Medical College, Tamaka, Kolar, Karnataka, India

Address for correspondence:

Dr. S. Prathima
Department of Pathology, Sri Devaraj
Urs Medical College,
Tamaka, Kolar - 563 101, Karnataka,
India. E-mail: parianil@gmail.com

Abstract

Background: Fine needle aspiration cytology (FNAC) is a well-established diagnostic technique in adult mass lesions but a comparatively new technique to pediatric lesions. **Aim:** The current study aims to evaluate the role of FNAC in pediatric age with special reference to pediatric tumors. **Subjects and Methods:** A retrospective study of FNAC in children ≤ 18 years of age presenting with mass lesions was studied for 5 years. Distribution of cases in different age groups, sex, and site of lesion was analyzed. Pediatric lesions were categorized into non-neoplastic, benign, and malignant conditions. Diagnostic efficacy was assessed by comparing subsequent histopathological examination wherever possible. **Statistical Analysis:** Epi info 07 (Centers for Disease Control and Prevention in Atlanta, Georgia (USA) 07) and values were presented as simple percentages. **Results:** FNAC was performed on 2903 cases in 5 years out of which 327 cases 11.3% (327/2903) were ≤ 18 years of age. Out of 327 cases, 180 cases 55% (180/327) were between 11 and 18 years. Male to female ratio was 1.15:1. The commonest site for FNAC was cervical lymph node swelling 48.3% (158/327). Reactive lymphadenitis was the commonest diagnosis among all mass lesions 38.8% (103/265), whereas Fibroadenoma 20.8% (10/49) was commonest diagnosis among benign lesions and among malignant lesions there were two cases 15.3% (2/13) each of Hodgkins and non-Hodgkins lymphoma and one case of chondrosarcoma. The positive predictive value of diagnosing malignant lesions on FNAC was 100%. **Conclusions:** The ease of FNAC along with its high diagnostic accuracy makes it a desirable method for diagnosing lesions in children.

Keywords: Fine needle aspiration cytology, Histopathology, Pediatric, Tumors

Introduction

Fine needle aspiration cytology (FNAC) is a well-established diagnostic technique for evaluating mass lesions in adult patients.^[1] FNAC is a safe, minimally invasive rapid procedure with good patient acceptance and low morbidity.^[2] However, it has been slow in gaining popularity in pediatric patients compared with its utilization in adult patients.^[1] Pediatric

lesions varies from country to country and region to region. In literature, there are only few Indian studies of FNAC in pediatric population.^[3-5]

Hence, this study was undertaken to review the cytomorphological spectrum of pediatric lesions in Kolar region with respect to age, sex, and site of involvement with special reference to pediatric tumors and to assess the diagnostic efficacy of FNAC.

Subjects and Methods

A total of 327 pediatric patients aged 0-18 years with palpable or deep seated lesions were included in the study period extending from January 2007 to December 2011. The cases included both inpatients and outpatients referred to the cytology section at our hospital. Ethical clearance certificate

Access this article online

Quick Response Code:



Website: www.amhsr.org

DOI:
10.4103/2141-9248.126608

from institutional ethical committee was taken for conducting the study.

After obtaining consent from parent or guardian, routine FNAC procedure was done using 21-24 gage needle attached to 10 ml syringe by a cytopathologist or by an invasive radiologist if guided aspiration was required. Wet fixed smears in absolute alcohol were stained by Hematoxylin and Eosin, Papanicolaou stain and air dried smears were stained with May Grunwald Geimsa stain. Special stains were done wherever necessary. Histopathological examination was done in 31 cases. Patients above 18 years of age and children with hematological malignancies were excluded from the study. Data was entered into a spread sheet and analyzed using Epi info 07.

Results

FNAC was performed on 2903 cases in 5 years out of which 327 cases 11.3% (327/2903) were \leq 18 years of age. Out of 327 cases, maximum number of pediatric patients i.e., 180 cases 55% (180/327) were between 11 and 18 years [Table 1]. Male to female ratio was 1.15:1. The most common site for FNAC was cervical lymph node swelling 48.3% (158/327) followed by thyroid swelling. Ultrasonography guided aspiration was performed in six cases 1.8% (6/327). Reactive lymphadenitis was the most common among non-neoplastic lesions 38.8% (103/265) followed by acute suppurative lesion 16.22% (43/265) and colloid goiter 7.2% (19/265). Among cervical lymph node lesions, maximum cases were of reactive lymphadenitis 65.2% (103/158), followed by acute suppurative lymphadenitis 12.6% (20/158), granulomatous lymphadenitis 10.7% (17/158), and tubercular lymphadenitis 10.1% (16/158). The smears of reactive lymphadenitis showed

Age group (years)	Male (n=175)		Female (n=152)		Total (n=327)	
	Frequency	%	Frequency	%	Frequency	%
\leq 1	5	2.8	6	3.9	11	3.3
2-5	36	20.5	14	9.2	50	15.2
6-10	55	31.4	31	20.3	86	26.2
11-18	79	45.1	101	66.4	180	55.0

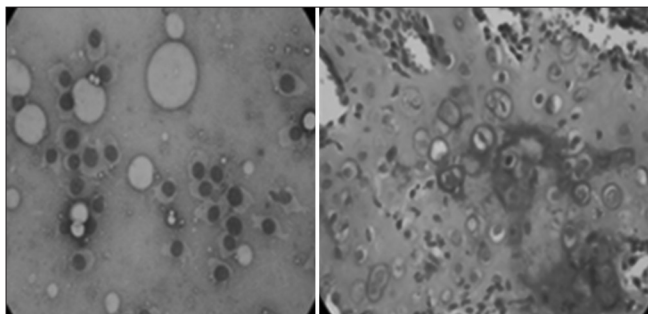


Figure 1: Photomicrograph of chondrosarcoma on FNAC and histopathology (H and E, \times 400)

a polymorphous population of lymphocytes and tingible body macrophages. Tubercular lymphadenitis cases were diagnosed on smears showing epithelioid granulomas in a background of necrosis, lymphocytes and presence of acid fast bacilli on Ziehl Neelsen (ZN) stain. Seventeen cases were diagnosed as non-specific granulomatous lymphadenitis where Periodic acid Schiff stain (PAS) and ZN stain showed no organisms.

Among benign tumors, fibroadenoma amounted for 10 cases 20.8% (10/49) followed by lipoma 18.3% (9/49), pleomorphic adenoma ($n = 4$) and spindle cell tumor ($n = 4$).

Among malignant lesions, there were two cases each of Hodgkins and non-Hodgkins lymphoma amounting to 15.3% (2/13) and one case of chondrosarcoma which were confirmed on subsequent histopathological examination. Smears from a case of chondrosarcoma showed a highly cellular smear consisting of large oval tumor cells with well demarcated eosinophilic cytoplasm against amorphous eosinophilic background [Figure 1]. Two cases of non-Hodgkins lymphoma demonstrated similar cytologic features, consisting of highly cellular samples of poorly cohesive monotonous lymphoid cells with slightly irregular nuclear membranes and inconspicuous nucleoli. Smears of Hodgkins lymphoma showed mixed population of lymphoid cells consisting of eosinophils, neutrophils and small lymphocytes and classical Reed-Sternberg cells [Figure 2].

The positive predictive value of diagnosing malignant lesions on FNAC was 100%.

Forty-nine children 15% (49/327) presented with thyroid lesions of which 38.7% (19/49) cases were diagnosed as colloid goiter, followed by 22.4% (11/49) cases of lymphocytic thyroiditis and 14.2% (7/49) cases of thyroglossal duct cyst.

Comparison of cytological and histological diagnosis was possible in 9.4% cases (31/327), the cytological diagnosis

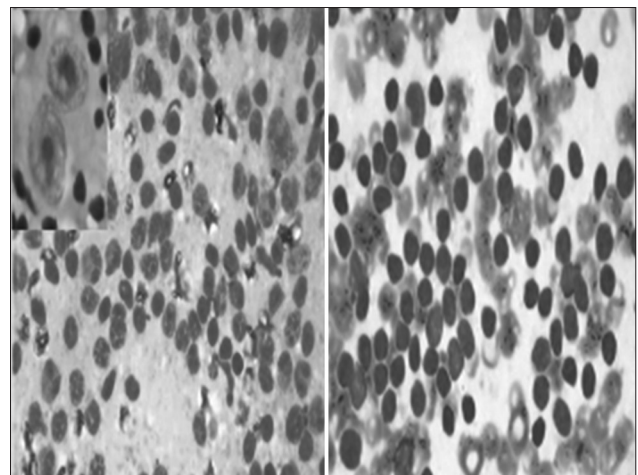


Figure 2: Photomicrographs of Hodgkin's lymphoma and non-Hodgkin's lymphoma on FNAC (Inset: Shows classical Reed Sternberg cell) (H and E, \times 400)

was concordant with the histopathological diagnosis in 81.6% (25/31) cases. In 19.4% (6/31) cases, there was discrepancy between cytology and histopathology diagnosis [Table 2].

Discussion

FNAC has been a very popular initial diagnostic tool in evaluating both superficial and deep seated lesions in adult patients.^[1] However, FNAC has received limited acceptance in pediatric cases possibly because of desire for diagnostic technique of low morbidity but high accuracy. In children, there are only few studies done mainly in head and neck lesions, lymphadenopathy, renal, and liver space occupying lesions.^[3-8]

A study by Jain, *et al.*, reported 6% of unsatisfactory aspirates and attributed them to small size of the lesions and poor handling of aspirated material, however, in the present study no unsatisfactory aspirates were obtained as repetition of the procedure was done if the first specimen was found inadequate on rapid methylene blue stain screening technique. This was supported by study done by Taylor *et al.*^[3,9]

In a study by Maheshwari, *et al.*, majority of cases (40.82%) were in the age group of 11-14 years, male dominated the study population (66.67%) with male:female ratio being 2:1.^[10] In the present study, maximum number of patients 55% (180/327) were in the age group of 11-18 years, male preponderance was observed 53.5% (175/327) with male:female ratio of 1.15:1.

In our study the commonest site for FNAC was cervical region swelling 48.3% (158/327). Shonubi, *et al.*, also reported similar finding in 70% (14/20) cases.^[11]

In the present study, the commonest cytopathological finding among cervical lymph node lesions was reactive lymphadenitis in 38.8% (103/158), followed by suppurative lymphadenitis 12.6% (20/158), granulomatous lymphadenitis in 10.75% (17/158) and tubercular lymphadenitis in 10.1% (16/158). Annam, *et al.*, also noted that the most common cytopathological finding as reactive lymphadenitis in 58.08%, followed by granulomatous lymphadenitis and tubercular lymphadenitis in 30.55% and 29.01%

respectively.^[12] Tuberculosis is still one of the leading cause of cervical lymphadenopathy in India. Diagnosis of tuberculosis in lymph nodes can be established by demonstrating acid fast bacilli in FNA smears with ZN stain or Auramine-rhodamine stain, mycobacterial culture or by amplification of bacterial DNA by polymerase chain reaction. But, the cost, time required and frequent negative results are important limitations.^[13] In 17 cases of granulomatous lymphadenitis, the etiological agent was not identified.

In our study, one case of reactive lymphadenitis was falsely diagnosed as granulomatous lymphadenitis on FNAC as the endothelial cells were misinterpreted as epithelioid cells. Two cases of granulomatous lymphadenitis, one case of parasitic cyst, branchial cyst, and follicular adenoma were missed on cytology due to lack of representative sample. Ultrasonography guided FNAC improves the accuracy of FNAC diagnosis because of representative samples and radiological correlation.

Fibroadenoma 20.8% (10/49) formed the majority among benign tumors in our study. Maheshwari *et al.*, noted soft tissue tumors (64%) were predominant among benign tumors.^[10]

The largest malignant group was formed by lymphomas (25.1%), followed by small round cell tumors (21.3%), and Wilms' tumor (12.6%) in a study by Maheshwari *et al.*^[10] In the present study, there were two cases each of non-Hodgkin's lymphoma and Hodgkin's lymphoma 15.3% (2/13) and one case of chondrosarcoma. Earlier study by Mobley *et al.*, has shown the predictive value of cytologically malignant FNAC to be 89.4% whereas in the present study it was 100%.^[14]

To conclude, FNAC is a safe and cost-effective procedure with good patient acceptance, no essential morbidity and can be used as an initial screening tool in superficial and deep seated lesions in pediatric age group. Although, the number of cases with histopathological correlation was less, the role of FNAC as an initial investigative procedure is undisputed, because of its high diagnostic accuracy.

References

1. Saad RS, Singh HK, Silverman FJ. Fine needle aspiration cytology. In: Orell SR, Sterett GF, editors. 5th ed. Pediatric Tumors. New Delhi: Churchill Livingstone Elsevier Ltd.; 2012. p. 445-67.
2. Rapkiewicz A, Thuy Le B, Simsir A, Cangiarella J, Levine P. Spectrum of head and neck lesions diagnosed by fine-needle aspiration cytology in the pediatric population. *Cancer* 2007;111:242-51.
3. Jain M, Majumdar DD, Agarwal K, Bais AS, Choudhury M. FNAC as a diagnostic tool in pediatric head and neck lesions. *Indian Pediatr* 1999;36:921-3.
4. Dey P, Mallik MK, Gupta SK, Vasishtha RK. Role of fine needle aspiration cytology in the diagnosis of soft tissue tumours and tumour-like lesions. *Cytopathology* 2004;15:32-7.
5. Khan RA, Wahab S, Chana RS, Naseem S, Siddique S.

Age (years)	Sex	Cytology diagnosis	Histopathology diagnosis
16	M	Granulomatous lymphadenitis	Reactive lymphadenitis
11	F	Colloid goitre	Follicular adenoma
12	F	Reactive lymphadenitis	Granulomatous lymphadenitis
14	F	Sialadenitis	Granulomatous lymphadenitis
15	F	Thyroglossal cyst	Branchial cyst
12	F	Keratinous cyst	Infected parasitic cyst

- Children with significant cervical lymphadenopathy: Clinicopathological analysis and role of fine-needle aspiration in Indian setup. *J Pediatr (Rio J)* 2008;84:449-54.
6. van de Schoot L, Aronson DC, Behrendt H, Bras J. The role of fine-needle aspiration cytology in children with persistent or suspicious lymphadenopathy. *J Pediatr Surg* 2001;36:7-11.
 7. Iyer VK. Role of fine needle aspiration cytology in management of pediatric renal tumors. *J Ind Assn Paediatr* 2007;12:116-9.
 8. Bakshi P, Srinivasan R, Rao KL, Marwaha RK, Gupta N, Das A, *et al.* Fine needle aspiration biopsy in pediatric space-occupying lesions of liver: A retrospective study evaluating its role and diagnostic efficacy. *J Pediatr Surg* 2006;41:1903-8.
 9. Taylor SR, Nunez C. Fine-needle aspiration biopsy in a pediatric population Report of 64 consecutive cases. *Cancer* 1984;54:1449-53.
 10. Maheshwari V, Alam K, Jain A, Agarwal S, Chana RS. Diagnostic utility of fine needle aspiration cytology in pediatric tumors. *J Cytol* 2008;25:45-9.
 11. Shonubi AM, Akiode O, Salami BA, Musa AA, Ntele LM. A preliminary report of fine-needle aspiration biopsy in superficially accessible lesions in children. *West Afr J Med* 2004;23:221-3.
 12. Annam V, Kulkarni MH, Puranik RB. Clinicopathologic profile of significant cervical lymphadenopathy in children aged 1-12 years. *Acta Cytol* 2009;53:174-8.
 13. Raviglione MC, O'Brien RJ. Tuberculosis. In: Longo DL, Kasper DL, Jameson J, Fauci AS, Hausen SL, Loscalzo J, *et al.* editors. *Harrison's Principles of Internal Medicine*. 18th ed. New York: McGraw-Hill; 2012. p. 1340-59.
 14. Mobley DL, Wakely PE Jr, Frable MA. Fine-needle aspiration biopsy: Application to pediatric head and neck masses. *Laryngoscope* 1991;101:469-72.

How to cite this article: Prathima S, Suresh TN, Harendra Kumar ML, Krishnappa J. Fine needle aspiration cytology in pediatric age group with special reference to pediatric tumors: A retrospective study evaluating its diagnostic role and efficacy. *Ann Med Health Sci Res* 2014;4:44-7.

Source of Support: Nil. **Conflict of Interest:** None declared.

Announcement

“QUICK RESPONSE CODE” LINK FOR FULL TEXT ARTICLES

The journal issue has a unique new feature for reaching to the journal's website without typing a single letter. Each article on its first page has a “Quick Response Code”. Using any mobile or other hand-held device with camera and GPRS/other internet source, one can reach to the full text of that particular article on the journal's website. Start a QR-code reading software (see list of free applications from <http://tinyurl.com/yzlh2tc>) and point the camera to the QR-code printed in the journal. It will automatically take you to the HTML full text of that article. One can also use a desktop or laptop with web camera for similar functionality. See <http://tinyurl.com/2bw7fn3> or <http://tinyurl.com/3ysr3me> for the free applications.