

Multiple Unerupted Permanent Teeth Associated with Noonan Syndrome

Uloopi KS, Madhuri V, Gopal AS, Vinay C, Chandrasekhar R

Department of Pedodontics and Preventive Dentistry, Vishnu Dental College, Bhimavaram, West Godavari, Andhra Pradesh, India

Address for correspondence:

Dr. Madhuri V,
Department of Pedodontics
and Preventive Dentistry,
Vishnu Dental College, Bhimavaram,
West Godavari - 534 202,
Andhra Pradesh, India.
E-mail: madhuvagesna@yahoo.co.in

Abstract

The present report describes a case of Noonan's syndrome from a dental viewpoint. Noonan syndrome is an autosomal dominant multisystem disorder. Congenital heart deformities, short stature, thoracic deformities, short neck with webbing, hypertelorism, and malocclusions are some of the frequently observed clinical features. Atypical dental anomalies such as multiple unerupted permanent teeth, multiple submerged and retained deciduous teeth, and supernumerary teeth were found in the present case. Oral prophylaxis and preventive resin restorations were done following which the supernumerary teeth were extracted. 54, 55, 64, 65, 74, 75 and 84 were extracted after orthodontic consultation to facilitate the eruption of permanent teeth. The patient is undergoing fixed orthodontic therapy for forced eruption of unerupted permanent teeth. General dentists should correlate dental anomalies with other systemic features in the diagnosis of such syndromes because of the variability in presentation and the need for multidisciplinary care.

Keywords: Hypertelorism, Noonan syndrome, Submerged teeth, Supernumerary teeth, Unerupted teeth

Introduction

Noonan syndrome (NS) is a clinically and genetically heterogeneous condition characterized by distinctive facial features, short stature, chest deformity, congenital heart disease, and other co-morbidities.^[1] The distinctive facial features consist of a broad forehead, hypertelorism, down-slanting palpebral fissures, a high-arched palate, and low-set, posteriorly rotated ears. Cardiac involvement is present in up to 90% of patients. Pulmonic stenosis and hypertrophic cardiomyopathy are the most common forms of cardiac disease, but a variety of other lesions are also observed. Additional relatively frequent features include multiple skeletal defects (chest and spine deformities), webbed neck, mental retardation, cryptorchidism and bleeding diathesis.^[2] Oral findings in patients with NS include a high arched palate (55–100%), dental malocclusion (50–67%), articulation difficulties (72%), and micrognathia (33–43%).^[1]

Some individuals with NS develop mandibular cysts, which can mimic cherubism.^[1]

This condition affects both males and females, and most cases are sporadic, but occasionally autosomal dominant inheritance occurs.^[3] The incidence of NS is estimated to be between 1:1000 and 1:2500 live births.^[1] Other disorders with significant phenotypic overlap with NS include William's syndrome, Leopard syndrome, fetal alcohol syndrome, and Aarskog syndrome. The present case report describes the atypical dental anomalies such as multiple unerupted permanent teeth; multiple submerged and retained deciduous teeth and supernumerary teeth associated with other known clinical features in a child with NS.

Case Report

A 13-year-old boy reported to the Department of Pediatric Dentistry with the chief complaint of irregularly placed upper and lower front teeth and unerupted teeth. Though his medical history was noncontributory, the child experienced an epileptic attack during childhood. Dental history reveals that he visited a private dental practitioner 1-year back with the same problem, and his lower front teeth were extracted. Physical examination revealed hypertelorism, flat nasal bridge, saddle nose, mild webbing of neck, pectus excavatum

Access this article online

Quick Response Code:	Website: www.amhsr.org
	DOI: *****

(funnel-shaped chest) [Figure 1], arachnodactyly (long and narrow toes and fingers) and clubbing of nails [Figure 2]. No marked cardiac abnormality was observed, and the patient had a normal electrocardiogram. Hand wrist radiograph revealed a missing carpal bone with no fusion of the present carpal bones [Figure 2]. Hematological findings showed an increase in alkaline phosphatase levels (179 U/L).

Intraoral examination revealed multiple submerged and retained deciduous teeth (53, 54, 55, 63, 64, 65, 73, 74, 75, 84, 85) [Figure 3], deep bite, high arched palate, gingival overgrowth with supernumerary teeth in the lower anterior region with grade I mobility of lower permanent incisors. Many permanent teeth were unerupted (12, 14, 15, 22, 24, 25, 33, 34, 35, 43, 44, 45, 46) [Figure 3] and all the erupted teeth were caries free.

Orthopantomograph revealed three supernumerary teeth in relation to lower anteriors, congenitally missing (12, 22, 38, and 48) and multiple impacted permanent teeth.

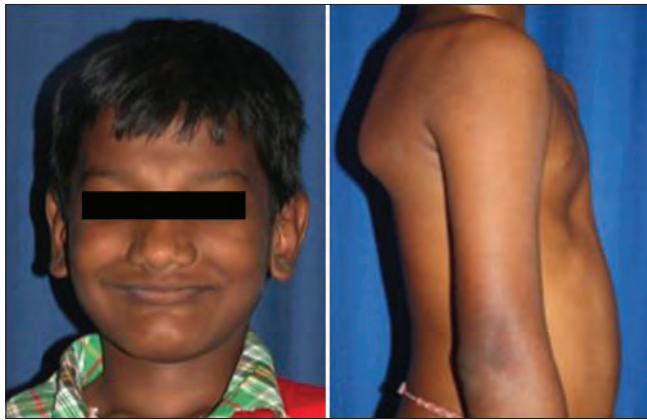

Figure 1: Extraoral profile view showing hypertelorism, flat nasal bridge, saddle nose, mild webbing of neck and lateral view showing pectus excavatum

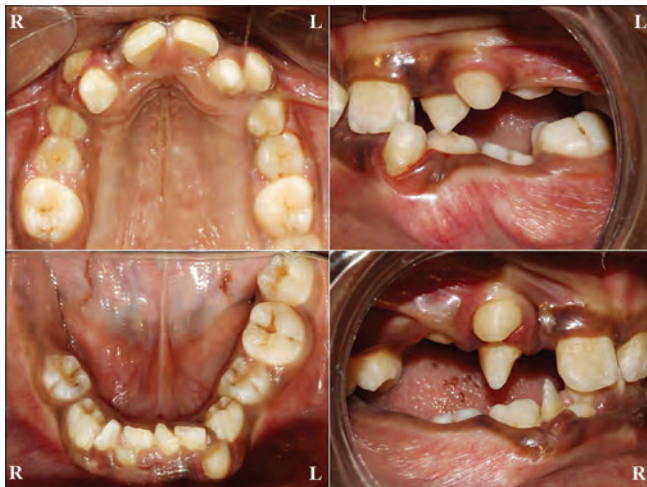

Figure 3: Intraoral views showing multiple submerged and retained deciduous teeth (53, 54, 55, 63, 64, 65, 73, 74, 75, 84, 85) and unerupted permanent teeth (12, 14, 15, 22, 24, 25, 33, 34, 35, 43, 44, 45, 46)

Mandibular right first permanent molar (46) was impacted and exhibited divergent roots [Figure 4]. Cephalometric analysis confirmed skeletal class I malocclusion with orthognathic maxilla and mandible associated with horizontal growth pattern and retroclined upper and lower anteriors [Figure 5].

The differential diagnosis includes William's syndrome, Leopard syndrome, fetal alcohol syndrome, and Aarskog syndrome.^[4,5] The absence of cardiovascular abnormalities in our patient has ruled out the possibility of William's syndrome.^[6] The absence of maternal alcohol consumption during pregnancy and lack of central nervous system abnormalities that are the cardinal features of fetal alcohol syndrome excludes it from the diagnosis.^[7] The present case could not be attributed to Aarskog syndrome due to lack of digital and genital findings.^[1] The presence of only one cardinal feature of Leopard syndrome that is, ocular hypertelorism in our patient excludes it from our diagnosis.^[1] The dental anomalies in the present case are closely associated to that of cleidocranial dysplasia, but the lack of skeletal anomalies affecting the skull and clavicle eliminates it from our diagnosis. Based on the clinical and radiographic features observed a

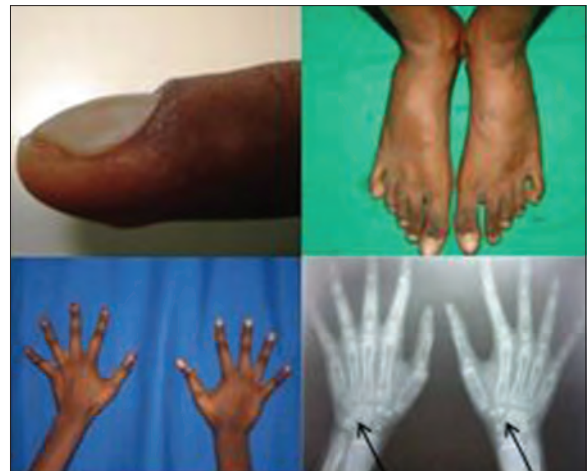

Figure 2: Photograph showing arachnodactyly and clubbing of nails; hand wrist radiograph revealing a missing carpal bone with no fusion of the present carpal bones

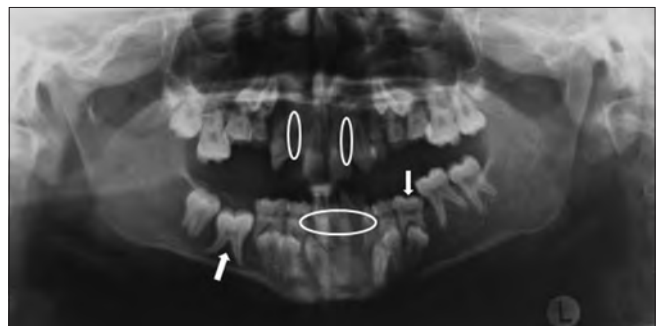

Figure 4: Orthopantomogram exhibiting three supernumerary teeth in relation to lower anteriors, congenitally missing (12, 22, 38, 48) and impacted permanent teeth (14, 15, 24, 25, 33, 34, 35, 43, 44, 45, 46). Mandibular right first permanent molar (46) was impacted and exhibited divergent roots

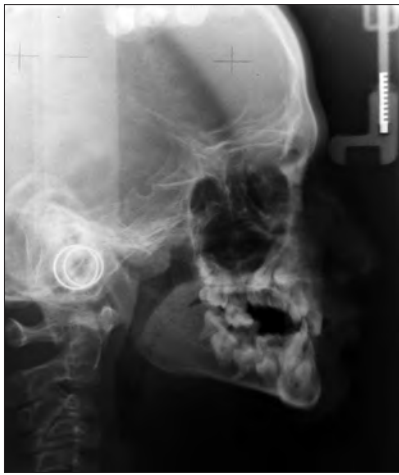

Figure 5: Lateral cephalogram showing skeletal class I malocclusion with orthognathic maxilla and mandible associated with horizontal growth pattern and retroclined upper and lower anteriors

provisional diagnosis of Noonan's syndrome was established after ruling out other differential diagnosis.

Comprehensive treatment was planned which included oral prophylaxis, fissure sealants, and preventive resin restorations. All the supernumerary teeth were extracted. The submerged primary teeth 54, 55, 64, 65, 73, 74, 75 and 84 were extracted to facilitate the eruption of permanent successors. After the extractions, only 35 has erupted into occlusion [Figure 6] The patient has been referred for orthodontic consultation to address the delayed eruption of permanent teeth. Presently, the patient is undergoing fixed orthodontic therapy for forced eruption of unerupted permanent teeth.

Discussion

Noonan syndrome (MIM number: 163950) was described by Noonan and Ehmke in 1963 as a multisystem disorder, characterized by broad forehead, hypertelorism, down-slanting palpebral fissures, a high-arched palate, and low-set, posteriorly rotated ears.^[2,8] NS is an autosomal dominant disorder characterized by short stature, facial dysmorphism, and a wide spectrum of congenital heart defects.^[2] The general body appearance is that of Turner syndrome, and hence NS is also known as "Pseudo-Turner syndrome" in females and "Male Turner syndrome" in males.^[3] In NS, no consistent chromosomal abnormality has been found.^[8] Recently, PTPN11 that encodes the nonreceptor protein tyrosine phosphatase SHP-2 (src omology region 2-domain phosphatase-2) was identified as the defective gene.^[9] Peripheral blood chromosomal analysis of this patient showed a normal male karyotype with no structural or numerical chromosome abnormalities. In view of the fact that NS is genetically heterogeneous disorder,^[10] we have established the diagnosis based on salient clinical features observed in this case.

The facial appearance is most characteristic in infancy and early-to-middle childhood and becomes more subtle in

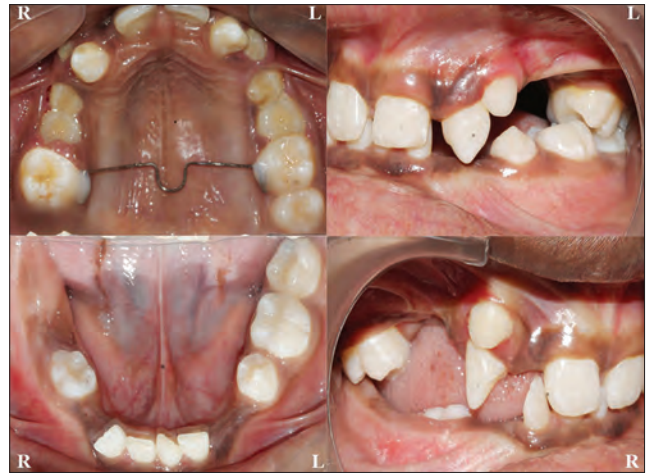


Figure 6: Intraoral postoperative photographs after preventive and corrective treatment

adulthood.^[1] It is proposed that orofacial features of NS result from edema of face and neck as a result of developmental disturbances of 3rd and 4th pharyngeal arches.^[11] Many adults have features that differ little from those in the general population. Other adults are recognizable because of continuing ptosis and wide-spaced eyes, low-set, posteriorly rotated ears with a fleshy helix, inverted triangular face that is broad at the temples and tapers to a small chin, and long and broad or webbed neck.^[4] In the present case, the child showed hypertelorism, flat nasal bridge, saddle nose, clubbing of nails, mild webbing of neck, pectus excavatum and arachnodactyly.

Despite the reported frequency of 50–80% cardiovascular alterations among patients with NS no cardiac abnormality was found in this patient, he had a normal electrocardiogram.^[12]

Bleeding disorders are of variable clinical severity and stem from different defects in the coagulation and platelet systems in NS patients. It has been estimated that roughly one-third of the patients have some sort of bleeding disorder.^[13] Hematological findings showed mild increase in clotting time and alkaline phosphatase levels. Derbent *et al.* (2011) concluded that patients with NS should have a thorough coagulation evaluation, but complications related to coagulation are unlikely, and extensive testing is unnecessary.^[2]

Very few studies have investigated changes in hand wrist radiographs in patients with NS. Emral and Akcam reported a case where hand wrist radiography demonstrated a slightly retarded bone age (13 years old) according to the standards of Greulich and Pyle.^[10] Hand wrist radiograph of this patient revealed a missing carpal bone with no fusion of carpal bones.

Oral features of Noonan's syndrome include micrognathia, high arched palate, dental malocclusion, dental anomalies, bifid uvula and rarely cleft palate.^[3,5] Distinctively this child exhibited multiple submerged, retained deciduous teeth and

multiple unerupted permanent teeth compared to previously reported cases in the literature.

Though many case reports did not confirm the presence of supernumerary teeth, Ortega *et al.* and Toureno and Park reported the presence of supernumerary teeth.^[13,14] In this case, the child had three supernumerary teeth. An interesting finding in this case was the presence of divergent roots in the unerupted mandibular right first permanent molar (46).

Full spectrum of dental anomalies in both deciduous and permanent dentition makes this case distinctive. The dental treatment was focused on extracting the submerged and retained deciduous teeth and supernumerary teeth and to aid the eruption of the unerupted permanent dentition. The need for early diagnosis should be emphasized in these cases because of the high incidence of cardiac, ophthalmic, growth, orthopedic and dental abnormalities. Growth hormone therapy has been tried in few children with NS with the aim of promoting growth.^[14] The pediatric dentist serves as the coordinator of overall oral health care and disease prevention during an extended treatment regimen that includes both surgical and orthodontic interventions.

References

- Romano AA, Allanson JE, Dahlgren J, Gelb BD, Hall B, Pierpont ME, *et al.* Noonan syndrome: Clinical features, diagnosis, and management guidelines. *Pediatrics* 2010;126:746-59.
- OMIM, Online Mendelian Inheritance in Man. Available from: <http://www.omim.org/entry/163950>. [Last accessed on 2014 Jul 14].
- Lee SM, Cooper JC. Noonan syndrome with giant cell lesions. *Int J Paediatr Dent* 2005;15:140-5.
- Allanson JE. Noonan syndrome. *Am J Med Genet C Semin Med Genet* 2007;145C: 274-9.
- Sahebamee M, Ameri NG, Farhud DD. First report of new oral findings in a case with Noonan syndrome. *Iran J Public Health* 2008;37:131-7.
- Game X, Panicker J, Fowler CJ. Williams – Beuren syndrome. *N Engl J Med* 2010;362:239-52.
- Bertrand J, Floyd LL, Weber MK, Fetal Alcohol Syndrome Prevention Team, Division of Birth Defects and Developmental Disabilities, National Center on Birth Defects and Developmental Disabilities, Centers for Disease Control and Prevention (CDC). Guidelines for identifying and referring persons with fetal alcohol syndrome. *MMWR Recomm Rep* 2005;54:1-14.
- Okada M, Sasaki N, Kaihara Y, Okada R, Amano H, Miura K, *et al.* Oral findings in Noonan syndrome: Report of a case. *J Oral Sci* 2003;45:117-21.
- Asokan S, Muthu MS, Rathna Prabhu V. Noonan syndrome: A case report. *J Indian Soc Pedod Prev Dent* 2007;25:144-7.
- Emral ME, Akcam MO. Noonan syndrome: A case report. *J Oral Sci* 2009;51:301-6.
- Terezhalmay GT, Moore WS. Noonan syndrome presenting with oral and dentofacial abnormalities. *Quintessence Int* 2002;33:554-5.
- Noonan JA. Noonan syndrome revisited. *J Pediatr* 1999;135:667-8.
- Ortega Ade O, Guaré Rde O, Kawaji NS, Ciamponi AL. Orofacial aspects in Noonan syndrome: 2 case report. *J Dent Child (Chic)* 2008;75:85-90.
- Toureno L, Park JH. Atypical orofacial conditions in Noonan syndrome: A case report. *J Clin Pediatr Dent* 2011;36:197-202.

How to cite this article: ????

Source of Support: Nil. **Conflict of Interest:** None declared.