



Pan African Urological Surgeons' Association

African Journal of Urology

www.ees.elsevier.com/afju
www.sciencedirect.com



Case report

Bladder exstrophy associated with complete urethral duplication: Bladder can be augmented with dorsal urethral mucosa

J.E. Mensah^{a,*}, K.N. Ampadu^a, M.Y. Kyei^a, B. Edusie^b

^a University of Ghana Medical School, Korle Bu Teaching Hospital, Department of Surgery, Accra, Ghana

^b 37 Military Hospital, Accra, Ghana

Received 29 September 2012; received in revised form 1st January 2013; accepted 1st January 2013

KEYWORDS

Bladder exstrophy;
Urethral duplication;
Bladder augmentation;
Urinary incontinence

Abstract

Bladder exstrophy associated with complete urethral duplication is very rare with only 8 reported cases in the English literature. This is a report of a 16 years old boy who had originally been diagnosed with only bladder exstrophy but was discovered to have a normal ventral urethra intra-operatively during penile disassembly. The mucosa of the dorsal urethral plate was transected at the corona and mobilised proximally to augment the bladder. The ventral urethra was preserved and the bladder closed. At 14 months follow up he is voiding normally, has adequate bladder capacity and a normal penis. Post operative voiding cystogram shows bilateral grade 2 vesicoureteric reflux.

In conclusion, bladder exstrophy with urethra duplication is rare and the diagnosis usually missed. The mucosa of the dorsal urethral plate can be preserved and used to augment the bladder.

© 2013 Pan African Urological Surgeons' Association. Production and hosting by Elsevier B.V. All rights reserved.

Introduction

Bladder exstrophy associated with complete urethral duplication is a very rare with only 8 reported cases in the English literature [1,2]. These cases were all successfully managed with preservation of the ventral urethra, excision of the dorsal urethra and closure of the bladder.

Case report

A 16 year old boy was referred to our unit with urinary incontinence since birth. Physical examination revealed features consistent with classic bladder exstrophy. He had a lower abdominal wall defect, no umbilicus, exstrophic bladder plate, a penis of adequate length with severe dorsal chordee (Fig. 1). Both tests were easily palpa-

* Corresponding author. Tel.: +233 20 8179911.

E-mail addresses: jemensah@chs.edu.gh, jemensah@hotmail.com (J.E. Mensah).

Peer review under responsibility of Pan African Urological Surgeons' Association.



Production and hosting by Elsevier

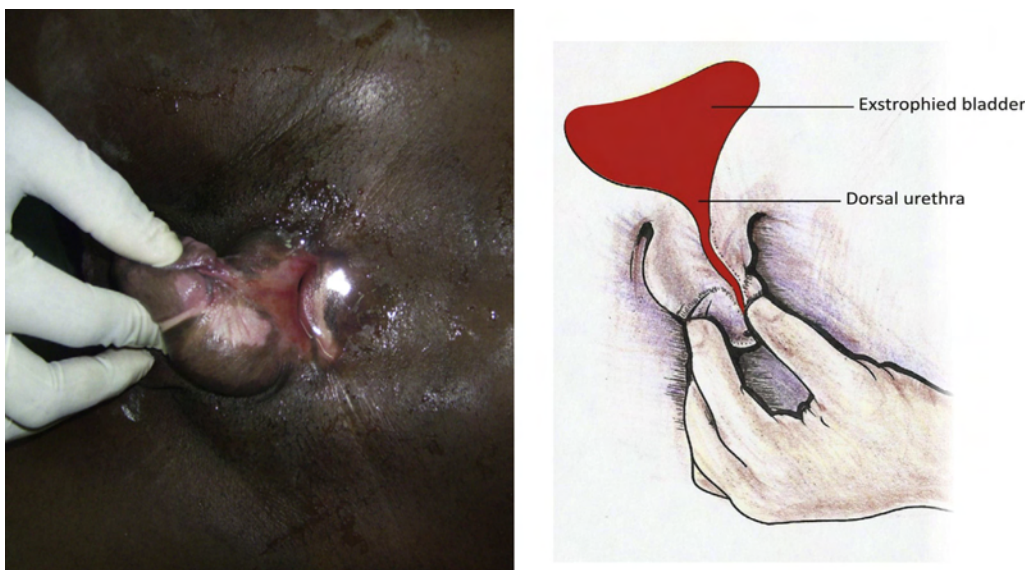


Figure 1 Exstrophied bladder.

ble. A pelvic X-ray showed diastases of the symphysis pubis. Our initial diagnosis was classic bladder exstrophy. He was prepared for augmentation cystoplasty with ileum, a continent Cutaneous diversion, bladder neck closure and epispadias repair. During penile degloving in preparation for epispadias repair, the ventral urethra was noticed. This prompted a closer inspection of the glans which revealed an apical urethral meatus which can easily accommodate a 16Fr urethral sound (Fig. 2). The surgery was suspended for a few minutes to allow us to conduct a literature search on what to do next. The ventral urethra could not be inspected because a suitable cystoscopy set was not available. The dorsal urethra was transected at the corona and carefully dissected off the underlying fibrotic corpus spongiosus and mobilised proximally to the bladder. The fibrotic dorsal spongiosal tissue which was identified as the cause of the dorsal chordee was completely excised. Artificial erection test

with normal saline instillation into the corpora cavernosa bilaterally confirmed a good correction of the chordee. The mucosa of the dorsal urethra plate which measured 2.2 cm × 6 cm (Fig. 3) was then incorporated in the bladder closure significantly increasing bladder capacity. The abdominal wall was closed primarily. The penile skin was restored with a reverse Byars flap. Because we were not sure about the ventral urethra a suprapubic catheter was left in situ. The post operative course was complicated by dorsal penile skin loss which was successfully managed with a split skin graft. Voiding cystogram showed a normal ventral urethra with bladder capacity of 320 ml and a grade two vesicoureteric reflux. The Suprapubic tube was then removed. At 14 months follow-up he is continent, voids normally and has good cosmetic penis of adequate length (Fig. 4).

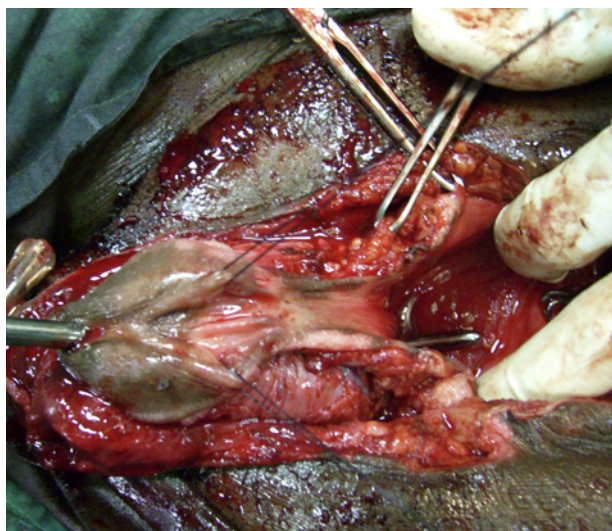


Figure 2 Ventral urethra with urethral sound in situ.

Discussion

Bladder exstrophy is a rare congenital anomaly with a reported prevalence of 3.52 per 100,000 [3]. Urethral duplication is also rare and is most common in the sagittal plane [4]. The urethral duplication which we failed to notice is usually not identified during preoperative assessment, with 5 cases out of 8 discovered at the time of bladder closure or penile reconstruction [1]. The ventral urethra is almost always the functional aspect and contains the sphincters and the opening of the ejaculatory duct [4]. The recommended management is therefore a complete excision of the dorsal urethra and preservation of the ventral urethra. This approach works well if the bladder capacity is large as occurs when the bladder is closed in the neonatal period. Patients presenting in adulthood with an open bladder usually therefore require some form of augmentation with bowel to increase bladder capacity [5–7]. Complications of enterocystoplasty including metabolic acidosis, stone formation and malignant transformation have been reported [8]. The use of urethral mucosa for bladder augmentation will potentially prevent these problems.

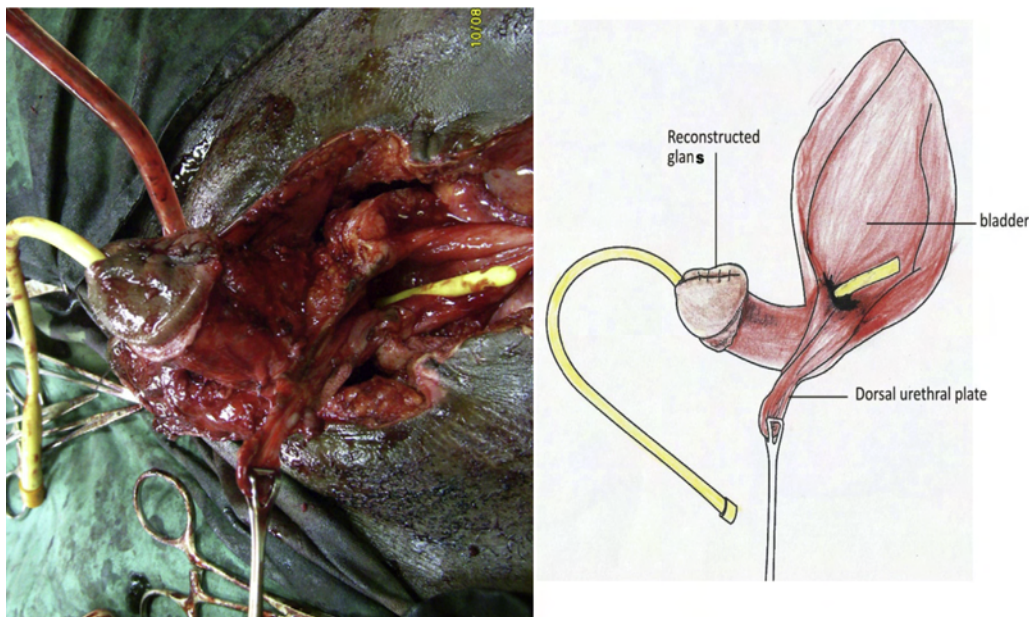


Figure 3 Dissection and mobilization of dorsal urethra.

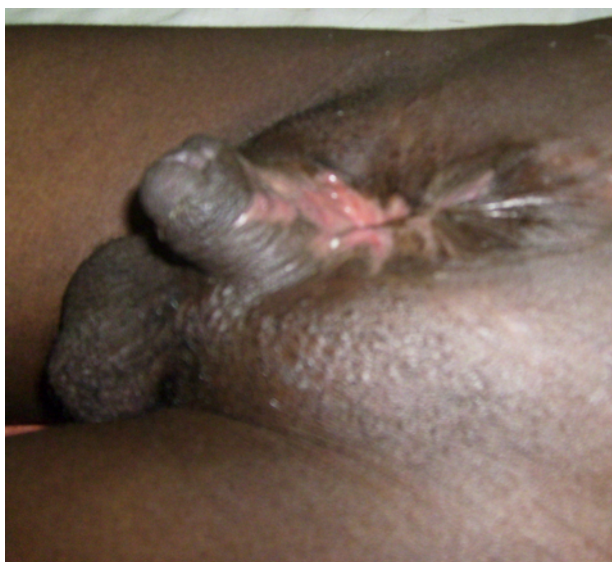

Figure 4 Post op results at 4 months.

Conclusion

Bladder exstrophy associated with complete urethra duplication is a rare malformation with a good functional outcome. The bladder can be augmented with the mucosa of the dorsal urethra.

References

- [1] Zeidan S, El-Ghoneimi A. Exstrophy-epispadias complex associated with complete urethral duplication: preoperative diagnosis is a must. *Urology* 2009;74:1228–9.
- [2] Pippi Salle JL, Sibai H, Jacobson AI, Fehri M, Brzezinski A, Homsy YL. Bladder exstrophy associated with complete urethral duplication: a rare malformation with excellent prognosis. *The Journal of Urology* 2001;165:2434–7.
- [3] Jayachandran D, Bythell M, Platt MW, Rankin J. Register based study of bladder exstrophy-epispadias complex: prevalence, associated anomalies, prenatal diagnosis and survival. *The Journal of Urology* 2011;186:2056–60.
- [4] Salle JL, Sibai H, Rosenstein D, Brzezinski AE, Corcos J. Urethral duplication in the male: review of 16 cases. *The Journal of Urology* 2000;163:1936–40.
- [5] Mansour AM, Sarhan OM, Helmy TE, Awad B, Dawaba MS, Ghali AM. Management of bladder exstrophy epispadias complex in adults: is abdominal closure possible without osteotomy? *World Journal of Urology* 2010;28:199–204.
- [6] Pathak HR, Mahajan R, Ali NI, Kaul S, Andankar MG. Bladder preservation in adult classic exstrophy: early results of four patients. *Urology* 2001;57:906–10.
- [7] Gulati P, Yadav SP, Sharma U. Management of bladder exstrophy in adulthood: report of 2 cases. *The Journal of Urology* 1997;157:947–8.
- [8] Schalow EL, Kirsch AJ. Advances in bladder augmentation. *Current Urology Reports* 2002;3:125–30.