



Pan African Urological Surgeons' Association

**African Journal of Urology**

www.ees.elsevier.com/afju  
www.sciencedirect.com



# Magnified and non magnified subinguinal varicocelectomy in infertile and/or symptomatic men: A comparative study of the outcome

H.H. Almaramhy\*, M. Aly

Department of General Surgery, Taibah University, Almadena Almonawara, Saudi Arabia

Received 26 July 2012; received in revised form 14 September 2012; accepted 30 September 2012

## KEYWORDS

Varicocelectomy;  
Reactive hydrocele;  
Recurrent varicocele

## Abstract

**Objective:** To compare the outcome of magnified and non magnified varicocelectomy for infertile and/or symptomatic men.

**Patients and methods:** One hundred and sixteen patients with 2nd and 3rd degree varicocele were treated in a university based hospital between January 2006 and July 2008. Sixty patients were randomly allocated to be operated upon by conventional subinguinal technique and this is the 1st group (9 patients of them with bilateral varicocele). Other 56 patients were operated upon by microsurgical subinguinal technique and this is the 2nd group (11 of them with bilateral varicocele). All patients were followed up at regular intervals, every 3 months for 3 years, 7 patients were lost during follow-up period, all of them with unilateral varicocele (3 patients from 1st group and 4 patients from 2nd group).

**Results:** Sixty-six varicocelectomies in the 1st group were done by conventional subinguinal technique (57 unilateral and 9 bilateral). Their results had been shown; 8 unilateral hydroceles (12.1%), 7 unilateral recurrences (10.7%) and one scrotal hematoma (1.5%). In the 2nd group total varicocelectomies were 63 (52 unilateral and 11 bilateral) had been done by microsurgical subinguinal technique resulting in no hydroceles and no scrotal hematomas but there were two unilateral recurrence (3%). The differences between the two techniques in the incidence of hydrocele formation and varicocele recurrence are significant ( $P < 0.001$ ) and ( $P < 0.03$ ) respectively.

\* Corresponding author.

E-mail address: hamdymaramhy@gmail.com (H.H. Almaramhy).

Peer review under responsibility of Pan African Urological Surgeons' Association.



Production and hosting by Elsevier

1110-5704 © 2012 Production and hosting by Elsevier B.V. on behalf of  
Pan African Urological Surgeons' Association.  
<http://dx.doi.org/10.1016/j.afju.2012.09.004>

*Conclusion:* Approaching the testis via a small subinguinal incision gives direct access to all testicular venous drainage. Furthermore, using the operating loupes helps to ease the recognition of the small venous channel, the testicular artery and the lymphatics, thus resulting in significant decrease of the incidence of varicocele recurrence, persistence, hydrocele formation and testicular artery injury. It is considered safe, effective and less morbid method for varicocelectomy.

© 2012 Production and hosting by Elsevier B.V. on behalf of Pan African Urological Surgeons' Association.

## Introduction

It is well-known that varicocele is an abnormal dilation of the pampiniform plexus. It is presented as asymmetry of the hemiscrotum or feeling of pain or heaviness in the scrotum. However, most of the cases are discovered during clinical examination before joining the military services [1–4].

Varicocele affects 12–16% of male children in late childhood and adolescence [5] but in comparison, it affects 30–40% of the male population at reproductive age [6]. The incidence of high-grade varicocele is approximately 5% throughout the world [7].

There is a relationship between varicocele, arrest of testicular growth, and infertility [8–11]. On the other hand varicocelectomy can reverse growth of the testes [12–15]. The significant effect of varicocele on testicular volume and fertility has increased attention of the population in diagnosis and surgical correction of varicocele [16]. Complication rates have increased and are related to the operative procedure used. The most common complications are recurrence and/or persistent varicocele (5–45%) [17] and reactive hydrocele (7–39%) [18]. Up to date, surgical varicocelectomy is considered as the primary form of treatment for varicocele. Different approaches have been described including; retroperitoneal high ligation, inguinal and sub-inguinal ligation, laparoscopic and microsurgical varicocelectomy [19,20].

While both retroperitoneal high ligation or inguinal approaches are effective, both of them necessitate incision of abdominal or inguinal fascias which lead to long recovery. This disadvantage has been overcome by the laparoscopic approach, in which the inguinal canal is not disturbed and thus gives advantage of shorter recovery time to normal activity. However, it is more costly and has the potential risk of injury to pelvic and/or intraabdominal contents. Subinguinal varicocele ligation has the advantages of repairing the varicocele without disturbing inguinal canal anatomy, abdominal fascia or entering the abdominal cavity. So, patients have an early return to normal activity [20].

Whatever the approach, some degree of magnification is necessary. This sort of magnification is usually achieved by surgical telescopes, 'Loupes' or an operating microscope. Clear visualization and identification of the anatomy is important in preventing potential sequelae [21]. If veins are not completely ligated, there will be a persistence of the varicocele and if these veins are not properly ligated, secondary hematoma may develop. Moreover, if the arteries are sacrificed, the patient may have an atrophic testis secondary to arterial insufficiency. While, if lymphatics are sacrificed, formation of a hydrocele may occur [21]. Injection of vital drops like methylene blue into the tunica vaginalis space may aid in identifications of lymphatics to be accessibly preserved [17]. All of these complications can be

avoided if care is taken to accurately identify the surgical anatomy by surgical loupes [12,22].

## Aim of the study

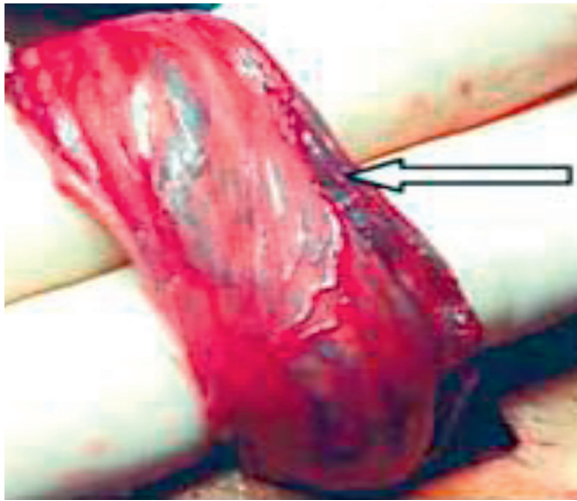
Conventional subinguinal open varicocelectomy is associated with risks of hydrocele formation, varicocele recurrence and ligation of the testicular artery. So, to avoid these complications we use a safer surgical approach in the form of subinguinal microsurgical varicocelectomy. The objective of this study is to compare the outcome of magnified and non magnified varicocelectomy for infertile and/or symptomatic men.

## Patients and methods

In a prospective, randomized, comparative study was conducted between January 2006 and July 2008 in the general surgery department of a University based Hospital after providing informed, written consent, A total of 116 patients of 2nd and 3rd degree varicocele presented with infertility for more than one year with abnormal two semen analysis and/or symptomatic varicocele. All patients underwent thorough history-taking and examination; semen analysis (at least twice) was taken after 3 days of abstinence and at least 1 month apart and scrotal color Doppler ultrasound. All varicoceles were diagnosed and graded (grade 1, 2, or 3) on the basis of physical examination and color Doppler ultrasound according to Cornud [23]. *Patient's inclusion criteria* for eligibility for participation were men between 16 and 45 years of age with symptomatic 2nd and 3rd degree varicocele, both unilateral or bilateral. *Exclusion criteria* were patients with sub clinical varicoceles or asymptomatic varicoceles, patients who had previous varicocele ligation either inguinal or scrotal surgery. Normal results on gynecologic assessment of the patient's partner were ensured before inclusion in the study.

Patients were randomly divided into two groups through a computer randomization program. The study protocol was approved by the Ethics Committee of the Hospital.

Patients were classified into two groups, *first group* randomly included 60 patients operated by conventional nonmagnified sub-inguinal technique without using any magnification with 9 of them with bilateral varicocele, and *second group* included 56 patients who were operated by microsurgical subinguinal technique with use of loupes, with 11 of these patients with bilateral varicocele. All patients were followed up postoperatively. *Varicoceles were graded* according to Cornud et al. [23], Grade I: brief reflux lasts less than 1 s and is physiological, Grade II: intermediate less than 2 s in most cases and, grade III: permanent reflux lasts more than 2 s.

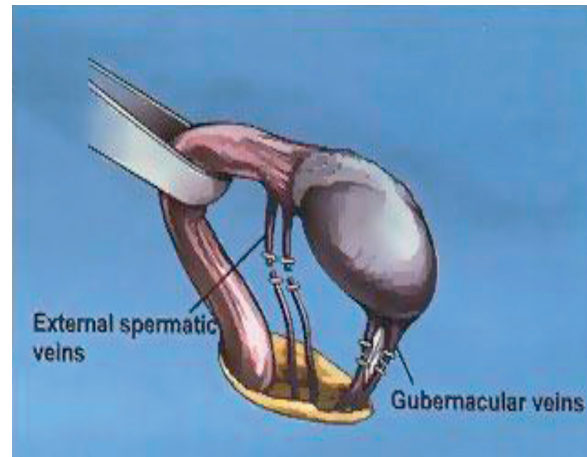


**Figure 1** Delivery of testis providing exposure of the external spermatic veins (arrow).

Physical examination was performed in a warm room with warm hands on with the patient standing. One hundred and seventeen patients were complaining from infertility or sub infertility (oligoasthenospermia). Forty-three patients were complaining of painful scrotum or infertility problem. In addition to routine investigations (as blood picture, X-ray chest, E.C.G. and fitness) specific investigations were done in the form of a color Doppler ultrasound to testis and cord. Testicular volume was measured by a single examiner on physical examination and testicular sonography. All men had at least two semen analyses before surgery and two semen analysis 3 months after surgery. Verbal and written consent was obtained from each patient. Randomization was achieved by computer-generated lists. The Mann-Whitney *U* test was used for comparison of medians; Student's *t* test was used for normally distributed data with equal variance between the two groups.

#### Operative techniques

The goal of treatment of the varicocele is to obstruct the refluxing venous drainage to the testis while maintaining arterial inflow and lymphatic drainage. In our microsurgical technique, the surgeon and the assistant wear surgical Loupes with  $2.5\times$  magnification. For the patient under general or spinal anaesthesia a 2–3-cm subinguinal oblique skin incision was done over the external inguinal ring. The incision is deepened through Camper's and Scarpa's fascias and the spermatic cord is then grasped with a Babcock clamp, delivered and placed over a large Penrose drain. The testicle is then delivered and the gubernacular veins and external spermatic perforators are isolated and divided (Fig. 1). The testicle is rehoused to the scrotum and the spermatic cord is elevated on a large Penrose drain. The cord is then tented anteriorly over one or two fingers and examined carefully (Fig. 2). The internal and external spermatic fascias are incised and the cord structures are examined well. To protect the vas deferens and its vessels from potential injury during cord dissection, we first create a small window between the internal spermatic vessels and the external spermatic fascia so that the internal spermatic vessels are separate from the external spermatic fascia and its associated structures (vas deferens and its vessels, cremasteric fibers and external spermatic vessels). A second soft drain is then



**Figure 2** The cord is tented of external spermatic and gubernacular venous collateral. After Chan and Goldstein, AUA 2001 [19].

introduced between the internal spermatic vessels and the external spermatic fascia and its associated structures.

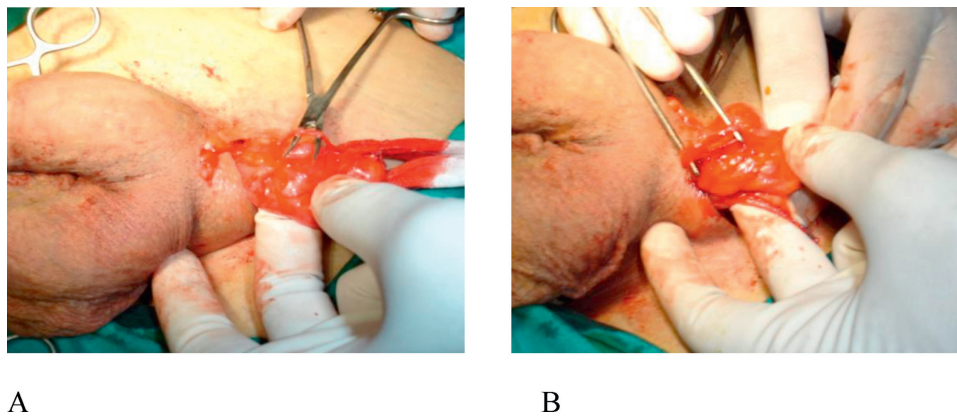
Firstly we dissect the contents of the internal spermatic fascia. Fine pulsations will usually point the location of the underlying internal spermatic artery (or arteries). Once located and identified, the artery is dissected and freed from all surrounding veins. Care is taken to identify a number of lymphatic's (usually 2–5 channels). All internal spermatic veins are clipped or ligated with 3-0 silk ties and then divided. At the end of the dissection, the cord is clarified so that only the identified artery (or arteries) and lymphatics are preserved.

Secondly genital handling and dissection of the contents of the external spermatic fascia was done. The vas deferens and its associated vessels are clearly identified and preserved. Any cremasteric artery is also preserved. The remaining cremasteric fibers and veins are ligated and cut, and this will lead to complete clarification of the cord. At the completion of varicocelectomy, the cord should contain only the vas deferens, and associated vessels, the testicular artery (Fig. 3a and b) and spermatic cord lymphatics (Fig. 4). The cord can be placed back to its normal position. Scarpa's and fascia are closed with a single 3-0 chromic catgut suture. The skin was closed with a subcuticular 4-0 Prolene. Semen analysis was done at 4 and 12 months. Seven patients with unilateral varicocele were lost during follow-up.

#### Results

*In the 1st group*, conventional subinguinal varicocelectomies were done in 57 patients without use of a microscope. Unilateral left-sided varicocelectomies were performed in 48 patients, while bilateral varicocelectomies were performed in 9 patients, and total number of varicocelectomies in this group were 66. The mean age of the patients in this group was 33 years. Postoperatively, there were 8 unilateral hydroceles (12.1%) and 7 unilateral recurrences (10.6%) and one scrotal hematoma (1.5%), which required surgical drainage.

*In the 2nd group* 52 cases.  $2.5\times$  loupes were used (microsurgical). Unilateral left-sided varicocelectomies were performed in 41 patients, while bilateral varicocelectomies were performed in 11 patients. Total varicocelectomies were 63 resulting in no hydroceles



**Figure 3** Testicular artery clearly identified and preserved with subinguinal microsurgical varicocelectomy.



**Figure 4** Lymphatic vessels can be exposed and preserved.

and no scrotal hematomas but there were two unilateral recurrences (3%). Mean age was 29 years. No cases of testicular atrophy or wound infection were found in both groups after follow-up for one-year duration. The differences between the two techniques in the incidence of hydrocele formation and varicocele recurrence are significant ( $P < 0.001$ ) and ( $P < 0.03$ ) respectively (Table 1).

**Table 1** The differences between the two techniques in the incidence of hydrocele formation\* and varicocele recurrence\*\* are significant ( $P < 0.001$ ) and ( $P < 0.03$ ) respectively.

	Nonmagnified varicocelectomy	Microsurgical (magnified) varicocelectomy
Mean age	33 years	29 years
Mean operative time	23 min	20 min
<i>Early postoperative complication</i>		
Scrotal hematoma	1 (1.5%)	None
Wound infection	None	None
<i>Late postoperative complication</i>		
Hydrocele	8 (12.1%)*	None (0.0%)
Recurrent varicocele	7 (10.6%)**	2 (3%)
Testicular atrophy	None	None
Total varicocelectomies	66	63

Postoperative semen analysis in both groups was equally improved ( $P$  value non significant).

### Discussion

Varicocelectomy have been under continuous improvement. The best varicocelectomy should enable surgeons to do ligation of the spermatic veins while protect the arteries and lymphatics and improve intraoperative and postoperative complications, with minimal morbidity. The method of varicocelectomy is still a matter of controversy owing to the complexity and variations of the testicular venous anatomy. Each approach or method has its own advantages and disadvantages, and conflicting results have been obtained by different researchers. The most common complications associated with conventional approaches include postoperative varicocele recurrence, hydrocele formation, and injury to the testicular artery, which may exert deleterious effects on semen quality. Microsurgical approaches allow precise delineation of the testicular artery and lymphatics, thus minimizing the risk of arterial injury, testicular atrophy and hydrocele formation. An additional benefit is the possibility of in situ repair if the artery is unintentionally injured. Although progressive modification has been made with the microsurgical varicocele ligation technique, there are few studies directly comparing the microsurgical technique with the nonmagnified techniques [20,21,24].

Our results in conventional varicocelectomies showed increased incidence of postoperative hydrocele (12.1%), in comparison to our results in microsurgical technique which showed no postoperative hydrocele (0.0%) or scrotal hematoma. There were two cases of scrotal hematoma in conventional procedure which needs surgical drainage. In conventional varicocelectomies, varicocele recurrence was found in 7 cases (10.6%) while recurrent varicoceles in microsurgical varicocelectomies had been shown in two cases (3%). The  $P$  value is significant as regard postoperative hydrocele ( $P < 0.001$ ) and recurrent varicocele ( $P < 0.03$ ). These results are nearly similar to results of other author as Goldstein et al. [17] who performed 33 conventional varicocelectomies in 24 men without use of a microscope. Postoperatively, 3 unilateral hydroceles (9%) and 3 unilateral recurrences (9%) were detected. They then performed 640 varicocelectomies using the microsurgical technique with delivery of the testis. Postoperatively no hydroceles and no cases of testicular atrophy were found. Postoperative complications vary with surgical techniques. Hydrocele formation is the most commonly seen

complication of varicocele repair. Etiology of post-varicocelectomy hydrocele is ligation of the lymphatic vessels, which are colorless and sometimes are mistaken for veins [25]. In microsurgical varicocelectomy series, the rate of postoperative hydrocele is so low that it can be considered negligible [26]. In the meta-analysis of Cayan et al. [27] the lowest hydrocele formation rate was 0.44% in the microsurgical series and 7.3% in the macroscopic inguinal or subinguinal varicocelectomy series.

Conventional open varicocelectomy is associated with a wide range of postoperative surgical complications. The most common complication in our study being hydrocele formation 12.1% agrees with the results of Carbone and Merhoff [28], Marmar and Kim [29], Cayan et al. [30] and Grober et al. [31] and Kim et al. [32]. Complications rate recorded by Szebo and Kessler [21] was about 5–30%, including hydrocele, arterial ligation, wound infection testicular atrophy, epididymitis, hematoma and injury to the vas deferens. The persistence and/or recurrence rate, from about 10–45%, is also significantly higher than microsurgical varicocelectomy. These results were near by our results. In addition, our results in microsurgical varicocelectomies are nearly similar to those obtained by Carbone and Merhoff [28]. In their series of 139 patients who underwent microsurgical varicocele ligation without delivery of the testicle; complications had occurred only in 4 (2.9%), recurrence in one (0.7%), wound infection in 1 (0.7%) and one (0.7%) had epididymitis. Unintentional injury of the testicular artery was reported only in one patient (0.7%). None of the 139 patients developed hydrocele. Thus, microsurgical varicocele ligation with delivery of the testicle results in less complication rate and postoperative hydrocele formation than non-microsurgical techniques [24]. There is no postoperative testicular atrophy in both groups, while others had an unintentional injury of the testicular artery (0.7%) [28]. This is mostly due to relatively small number of patients included in our study. The recommendation of American Urological Association, that varicocelectomy should be done by optical magnification as a safe, effective and less morbid method for varicocelectomy [33,34]. Therefore, microsurgical varicocelectomy virtually eliminates post-operative hydrocele formation, which is the most common complication of non-microsurgical varicocelectomy [19].

## Conclusion

Subinguinal microsurgical varicocelectomy allows clear visualization of the testicular artery, lymphatics and small venous channels, resulting in a significant decrease in the incidence of complications including; hydrocele formation, testicular artery injury and varicocele recurrence and/or persistent. Furthermore, microsurgical subinguinal varicocelectomy is considered a safe, effective and less morbid method for varicocelectomy, and it offers the best outcome and should be the preferred varicocelectomy technique.

## References

- [1] Skoog SJ, Roberts KP, Goldstein M, Pryor JL. The adolescent varicocele: what's new with an old problem in young patients? *Pediatrics* 1997;100:112–21.
- [2] Buch JP, Cromie WJ. Evaluation and treatment of the preadolescent varicocele. *Urologic Clinics of North America* 1985;12:3–12.
- [3] Vasavada S, Ross J, Nasrallah P, Kay R. Prepubertal varicoceles. *Urology* 1997;50:774–7.
- [4] Lund L, Rasmussen HH, Ernst E. Asymptomatic varicocele testis. *Scandinavian Journal of Urology and Nephrology* 1993;27:395–8.

- [5] El-Gohary MA. Boyhood varicocele: an overlooked disorder. *Annals of the Royal College of Surgeons of England* 1984;66:36–8.
- [6] Comhaire I'H. Vasculature of the testis: assessment and management of varicocele. In: Burger H, De Krester D, editors. *The testis*. New York: Raven Press; 1989. p. S15–26.
- [7] Niedzielski J, Paduch D, Raczynski P. Assessment of adolescent varicocele. *Pediatric Surgery International* 1997;12:410–3.
- [8] Gorelick JJ, Goldstein M. Loss of fertility in men with varicocele. *Fertility and Sterility* 1993;59:613–6.
- [9] Goldstein M. New insights into the etiology and treatment of male infertility. *Journal of Urology* 1997;158:1808–9 [Editorial; Comment].
- [10] The influence of varicocele on parameters of fertility in a large group of men presenting to infertility clinics. *World Health Organization* 1992;57:1289–93.
- [11] Belloli GS, Pesce DA, Fantuz CE. Varicocele in childhood and adolescence and other testicular anomalies: an epidemiological study. *Pediatrica Medica e Chirurgica* 1993;15:159–62.
- [12] Paduch DA, Niedzielski J. Repair versus observation in adolescent varicocele: a prospective study. *Journal of Urology* 1997;158:1128–32.
- [13] Kass EJ, Reitelman C. Adolescent varicocele. *Urologic Clinics of North America* 1995;22:151–9.
- [14] Atassi O, Kass EJ, Steinert BW. Testicular growth after successful varicocele correction in adolescents: comparison of artery sparing techniques with the Palomo procedure. *Journal of Urology* 1995;153:482–3.
- [15] Lenzi A, Gandini L, Bagolan P, Nahum A, Dondero F. Sperm parameters after early left varicocele treatment. *Fertility and Sterility* 1998;69:347–9.
- [16] Podesta ML, Gottlieb S, Medel Jr R, Ropelato G, Bergada C, Quesada EM. Hormonal parameters and testicular volume in children and adolescents with unilateral varicocele: preoperative and postoperative findings. *Journal of Urology* 1994;152:794–7.
- [17] Goldstein M, Gilbert BR, Dicker AP. Microsurgical inguinal varicocelectomy with delivery of the testis: an artery and lymphatic sparing technique. *Journal of Urology* 1992;148:1808–11.
- [18] Hutson JM. Varicocele and its treatment [editorial]. *Pediatric Surgery International* 1995;10:509–12.
- [19] Chan P, Goldstein M. Varicocele: options for management. *AUA News* 2001;6:1–8.
- [20] Chiou RK, Cornell LE, Chiou YK, Carr A. Subinguinal inguinal varicocele ligation: surgical technique and clinical experience. *South Central Section AUA Austin, TX* 2001;9:8–12.
- [21] Szebo R, Kessler R. Hydrocele following internal spermatic vein ligation: a retrospective study and review of the literature. *Journal of Urology* 1984;154:924–5.
- [22] Fisch H, Johnson W, Bingham B, Anastasiadis G. A novel surgical approach to subinguinal varicocelectomy: artery and lymphatic isolation technique. *Urologia Internationalis* 2004;72:162–4.
- [23] Cornud F, Belin X, Amar E, Delafontaine D, Helenon O, Moreau JF. Varicocele strategies in diagnosis and treatment. *European Radiology* 1999;9:536–45.
- [24] Barbalius GA, Liatsikos EN, Nikiforidis G, Siablis D. Treatment of varicocele for male infertility: a comparative study evaluating currently used approaches. *European Urology* 1998;34:393–8.
- [25] Al-Kandari AM, Shabaan H, Ibrahim HM, Elshebiny YH, Shokeir AA. Comparison of outcomes of different varicocelectomy techniques: open inguinal, laparoscopic, and subinguinal microscopic varicocelectomy: a randomized clinical trial. *Urology* 2007;69:417–20.
- [26] Hagood PG, Mehan DJ, Worischek JH, Andrus CH, Parra RO. Laparoscopic varicocelectomy: preliminary report of a new technique. *Journal of Urology* 1992;147:73–6.
- [27] Cayan S, Shavakhobov S, Atekadiolu A. Treatment of palpable varicocele in infertile men: a metaanalysis to define the best technique. *Journal of Andrology* 2009;30:33–40.
- [28] Carbone DJ, Merhoff V. Complication rate of microsurgical varicocele ligation without delivery of the testis. *Archives of Andrology* 2003;49(3):201–4.

- [29] Marmar JL, Kim Y. Subinguinal microsurgical varicocelectomy: a technical critique and statistical analysis of semen and pregnancy data. *Journal of Urology* 1994;152:1127–32.
- [30] Cayan S, Kadioglu TC, Tefekli A, Kadioglu A, Tellaloglu S. Comparison of results and complications of high ligation surgery and microsurgical high inguinal varicocelectomy in the treatment of varicocele. *Urology* 2000;55:750–4.
- [31] Grober ED, O'Brien J, Jarvi JA, Zini A. Preservation of testicular arteries during subinguinal microsurgical varicocelectomy: clinical considerations. *Journal of Andrology* 2004;25:5.
- [32] Kim SO, Chung HS, Park K. Modified microsurgical subinguinal varicocelectomy without testicular delivery. *Andrologia* 2011;43(December (6)):405–8.
- [33] Jarow JP, Sharlip ID, Belker AM, Lipshultz LI, Sigman M, Thomas AJ, et al. Best practice policies for male fertility. *Journal of Urology* 2002;167:2138–44.
- [34] Diamond DA, Xuewu J, Cilento Jr BG, Bauer SB, Peters CA, Borer JG, et al. Varicocele surgery: a decade's experience at children's at a children's hospital. *BJU International* 2009;104(July (2)): 246–9.