

Original Article

## Management of Complex Urogenital Fistulae in the Female

M. A. Al Rifaei, A.M. Al Rifaei and S. El Salmy

*Department of Urology, Faculty of Medicine, University of Alexandria, Alexandria, Egypt.*

### ABSTRACT

**Objective:** To present our experience in the management of complex genitourinary fistulae in the female.

**Patients and Methods:** Between 1995 and 2004, 12 female patients with a mean age of 30 (range 6 – 40) years were managed in our department for various types of complex genitourinary fistulae caused by difficult labor in 6 cases, abdominal hysterectomy in 5 cases and car accident in one case. All patients were subjected to clinical, radiological and endoscopic examination. The fistulae were managed by open surgery. The procedures were individualized according to the existing pathology and included bladder augmentation and construction of a bladder tube.

**Results:** The fistulae were repaired successfully and socially acceptable continence was achieved in all patients.

**Conclusion:** Through urological evaluation of complex urinary fistulae is recommended. The treatment should be individualized based on the existing pathology and may include bladder augmentation and construction of a bladder tube.

**Keywords :** Female urogenital fistulae, complex fistulae, urinary incontinence.

**Corresponding Author:** Prof. Mostafa Al Rifaei, Department of Urology, Faculty of Medicine, University of Alexandria, Alexandria, Egypt.

**Article Info:** Date received : 10/1/2007

Date accepted: ( after revision): 9/3/2008

### INTRODUCTION

Female genitourinary fistulae are defined as "complex" if they fulfill one or more of the following criteria:

1. associated injury to the urinary sphincters,
2. involvement of more than two organs,
3. previous failed surgical repair and
4. marked loss of urinary or genital tissue.

In the management of such complex genitourinary fistulae surgical expertise and awareness of alternatives are indispensable<sup>1</sup>. Successful repair clearly involves the application of a spectrum of techniques that are selected on the basis of the underlying factors including the cause, location, size of the fis-

tula and/or the presence of urethral involvement. Therefore, careful selection of patients, optimal timing of surgery, comprehensive diagnostic studies, appropriate use of bowel or bladder tubes and proper drainage are mandatory<sup>1-4</sup>.

### PATIENTS AND METHODS

Between 1995 and 2004, 120 cases of urogenital fistula in the female were managed in our department. Twelve of these patients (10%) with a mean age of 30 (range 6 – 40) years had complex fistulae caused by difficult labor in 4, abdominal hysterectomy in 7 and a car accident in one (Table 1).

**Table 1:** Overview of patients' characteristics, treatment and results in 12 patients

No.	Age (years)	Etiology	Diagnosis	Management	Result
1	27	Difficult labor	Urethral loss and derangement of bladder neck	Proximally based anterior bladder tube	Continent, good bladder capacity
2	24	Difficult labor	Urethral loss and derangement of bladder neck	Proximally based anterior bladder tube	Continent, good bladder capacity
3	6	Car accident	Urethral loss and derangement of bladder neck	Distally based anterior bladder tube	Continent, good bladder capacity
4	26	Difficult labor	Vesicovaginal fistula and stenotic ureteric orifice	Closure of the fistula and transvesical meatoplasty	Continent, refused further studies
5	30	Difficult labor	Vesicovaginal fistula and stenotic ureteric orifice	Closure of the fistula and transvesical meatoplasty	Continent, refused further studies
6	40	Abdominal hysterectomy	Vesical and bilateral ureterovaginal fistula	Colocystoplasty and implantation of both ureters in the colonic segment	Continent, good bladder capacity
7	28	Abdominal hysterectomy	Vesical and left ureterovaginal fistula	Closure of the fistula and left ureterovesical implantation	Continent, refused further studies
8	31	Abdominal hysterectomy	Vesical and left ureterovaginal fistula	Closure of the vesical fistula and left ureterovesical implantation	Continent, refused further studies
9	36	Abdominal hysterectomy	Vesical and right ureterovaginal fistula	Closure of the vesical fistula and right ureterovesical implantation	Continent, good right renal function
10	37	Abdominal hysterectomy	Right ureterovaginal fistula (short ureter)	Anastomosis of the right ureter to a Boari bladder tube.	Continent, good right renal function
11	40	Abdominal hysterectomy	Right ureterovaginal fistula (short ureter)	Anastomosis of the right ureter to a Boari bladder tube	Continent, good right renal function
12	35	Abdominal hysterectomy	Left ureterocervical fistula (short ureter), with stones in the cervical stump	Removal of the stones and anastomosis of the left ureter to a Boari bladder tube	Continent, good left renal function

All patients were subjected to clinical, radiological and endoscopic examination, intravenous pyelography (IVP) and retrograde cystography. Ureteric catheterization was performed in every case of suspected ureteric involvement and in cases where the vesicovaginal fistulae were close to the ureteric orifice.

The choice of treatment depended on the individual case:

Two patients with complete destruction of the bladder neck and urethra (Fig. 1, 2) due to vesicourethrovaginal fistulae were managed via a combined abdominal and vaginal

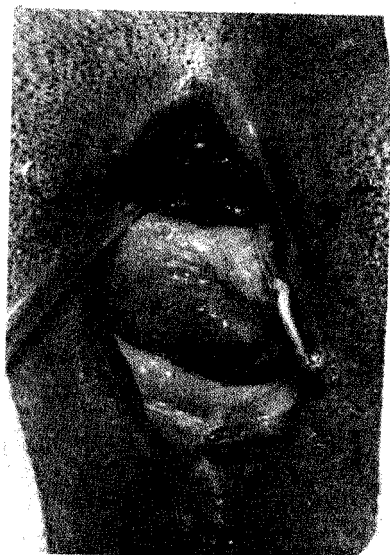

Fig. 1: Large vesico-vaginal fistula with complete destruction of the urethra and the bladder neck, as a result of difficult labor in a 27-year-old woman.

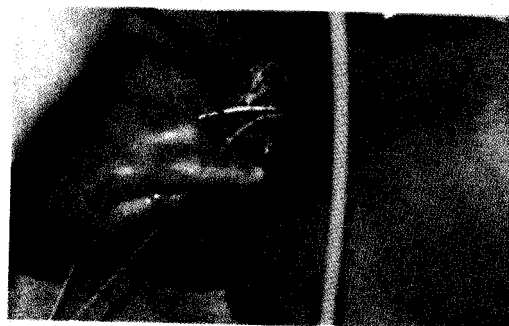


Fig. 2: Large vesico-vaginal fistula as a result of difficult labor in a 24-year-old female, with complete destruction of the bladder neck and urethra, showing an exposed trigone. Two ureteric catheters were manually passed up the ureters.

approach. A proximally based anterior bladder tube was constructed (Fig. 3) in order to replace the urethra anatomically and functionally. The fistula was closed and a 20F Foley catheter was left indwelling, combined with a suprapubic vesical catheter. The urethral catheter was removed after 3 weeks, the suprapubic catheter one week later.

A 6-year-old female child sustained pelvic fracture, vaginal injury and severe injury to the bladder neck and urethra as a result of a car accident. Suprapubic cystostomy was performed as an emergency procedure. There was intermittent leakage of urine through the vagina. A cystogram performed via the bladder catheter 2 months later showed obstruction of the bladder neck and bilateral vesicoureteric reflux (Fig. 4 A). On vaginal examination the urethra was found to be almost completely destroyed. By a combined abdominal and vaginal approach, a distally based anterior bladder tube was placed and fixed in the bed of the urethra (Fig. 4 B).

In two cases, the vesico-vaginal fistula was associated with a stenotic ureteric orifice, possibly due to the pressure exerted by the

fetal head during prolonged difficult labor. These cases were managed by transvesical meatoplasty and closure of the fistulae via the abdominal route.

One patient had a very wide vesico-vaginal fistula with loss of the bladder dome, associated with bilateral ureteric fistulae. These injuries were inflicted during abdominal hysterectomy where both ureters were transected. The patient was managed by augmentation colcystoplasty and antireflux implantation of both ureters by a Goodwin submucous tunnel in the colonic segment (Fig. 5).

Combined vesical and uretero-vaginal fistulae as complications of abdominal hysterectomy were found in 3 cases. They were repaired by closure of the vesical fistulae and uretero-vesical implantation of the injured ureters. One of these patients had fused pelvic kidneys adhering to the bladder which were released by careful dissection.

In two patients with right ureterovaginal fistulae and short ureters, ureteric anastomosis to a Boari bladder tube was performed.

The last patient had a left uretero-cervical fistula which was complicated by the formation of two stones in a pouch in the cervical stump. This injury was a complication

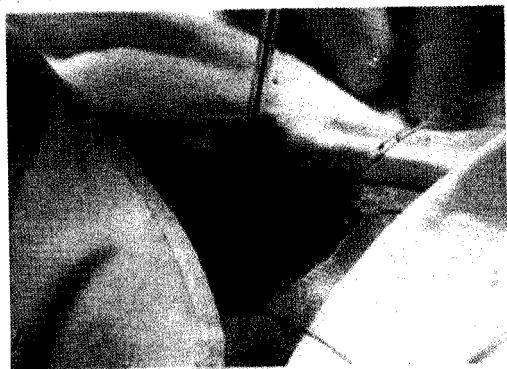

Fig. 3: (A) Operative picture showing the fashioned bladder tube for the repair of a lost bladder neck and urethra and diagram (B) illustrating the steps of the operation.

of emergency subtotal hysterectomy for rupture of the uterus during difficult labor. The left kidney showed a good excretion of contrast medium on intravenous pyelography and the left ureter was shown to be directed to the cervical stump (Fig. 6). On endoscopy of the vagina a large stone was visible in the cervical stump with urine passing around it. After removing two stones from the cervical stump per vaginam under vision, a 3 x 3 cm cavity could be seen in the cervical stump. Abdominal exploration was performed; the left ureter was dissected from the cervical stump and anastomosed to a left Boari bladder tube.

The follow-up period varied between 3 months and 2 years.

## RESULTS

In all cases treatment was successful defined as closure of the fistula and restoration

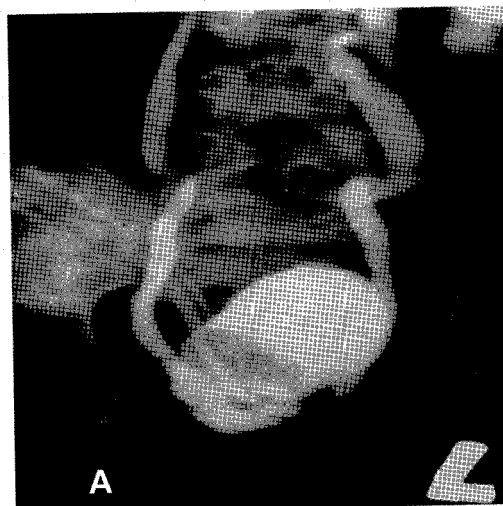


Fig. 4: (A) Suprapubic cystogram in a 6-year-old female child, showing marked vesico-ureteric reflux, hydroureters, and complete destruction and obliteration of the bladder neck resulting from a car accident. (B) Illustrative diagram of the steps of performing a distally based anterior bladder tube.

of urinary continence – the latter was defined as requiring one or no pads per 24 hours and good control during stress. This was achieved immediately after catheter removal in 9 patients and after 3-6 months in 3 patients. Post-operative cystography performed in some cases showed arrest of the contrast medium above the bladder outlet, proving bladder neck competence (Fig. 7). Four of the 12 patients were satisfied with regaining bladder control and declined further studies.

## DISCUSSION

Complications of labor and delivery continue to be the main etiological factor in the formation of genitourinary fistulae in our society.

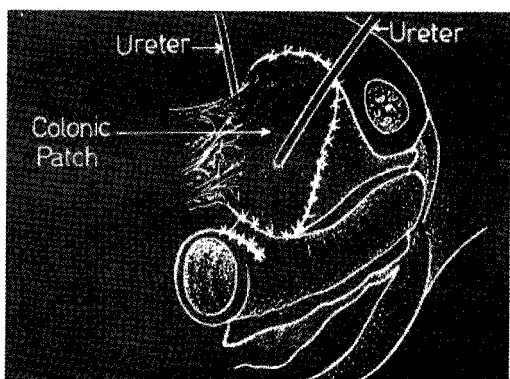


Fig. 5: Diagrammatic illustration of colocolostomy and implantation of both ureters into the colonic patch.

For successful closure of such fistulae, accurate diagnosis is mandatory. One must be aware of combined fistulae (e.g. cases 1 and 2) and of associated ureteric injury (e.g. cases 6 and 7). An incomplete diagnosis may carry the risk of overlooking combined fistulae which will lead to treatment failure<sup>5</sup>.

In one of our patients (case 6) the pre-operative diagnosis was not conclusive. On exploration we found that most of the bladder was removed and both ureters were hidden in the pelvic wall, necessitating colocolostomy with ureterocolic implantation. This procedure is similar to the one described by Gan and Li<sup>5</sup> who reported on a case of ureterovaginal and vesicovaginal fistulae managed with ileocystoplasty and ureteric implantation into an antireflux ileal nipple valve. Augmentation enterocystoplasty should be performed if the remnant bladder capacity is small.

The fistula may take an irregular course that cannot be catheterized. In one case we identified endoscopically two pits in the bladder and the vagina, which did not appear to communicate with each other. The presence of such an irregular track can be identified only during surgical exploration.

An anterior bladder tube can be constructed from the anterior bladder wall in order to replace the bladder neck and urethra anatomically and functionally. The circular

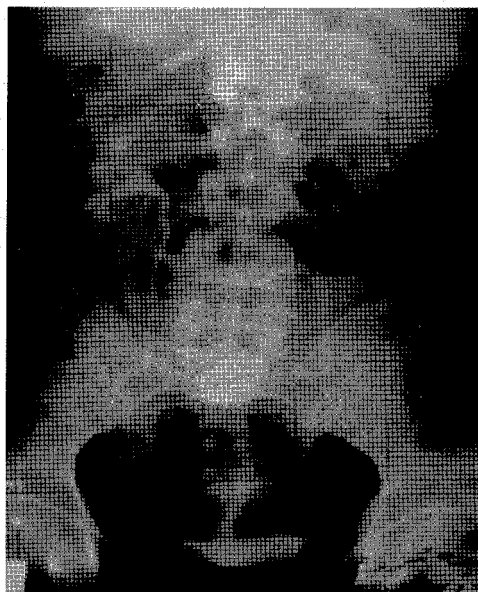


Fig. 6: Intravenous urogram of a 35-year-old female after emergency subtotal hysterectomy for rupture of the uterus during difficult labor, showing left uretero-cervical fistula. The contrast medium fills the cervical stump and passes to the vagina.

smooth muscle fibres in the anterior bladder wall can attain urinary continence<sup>6</sup>. Naru et al.<sup>7</sup> reported three cases of large recurrent urethrovaginal fistulae associated with urinary incontinence. They managed them by ureterosigmoid anastomosis, but did not attempt urethral reconstruction.

Combined abdominal and vaginal approaches should be used in cases of urethrovaginal fistulae and transverse vesicovaginal fistulae near the bladder neck, as the abdominal approach alone presents some technical difficulties.

Large fistulae may result from tissue necrosis of the anterior vaginal wall and the posterior bladder wall during obstructed labor caused by pressure exerted by the fetal head. The tissue ischemia may extend to involve the urethra and even the intramural ureters<sup>3</sup>. Large vesical and vesicourethral fistulae can also result from surgical operations.

When pressure necrosis of the anterior vaginal wall and the bladder neck occurs du-

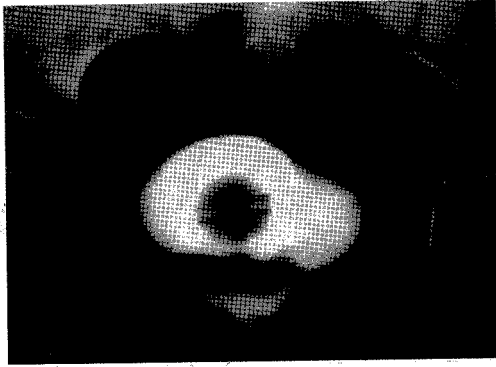


Fig. 7: Postoperative cystogram showing arrest of the contrast medium above the bladder outlet which proves bladder neck competence.

ring prolonged obstructed labor, sometimes the area of necrosis is more extensive, and the urethra and trigone are involved<sup>8</sup>. If the bladder neck and urethra are involved, the patients will suffer from sphincteric incontinence, even after successful closure of the fistula<sup>9</sup>. In such cases incontinence is inevitable, as both sphincters are destroyed.

Tancer<sup>10</sup> managed 26 women with urethrovaginal fistulae, with an intact urethra distal to the fistula. Successful function and anatomic results were obtained in 23 patients. In another 5 women with completely destroyed posterior urethral walls, he achieved the same success in 3 cases.

Omental pedicled graft interposition between the bladder and the vagina may provide a barrier against recurrence of the fistula<sup>3,11-13</sup>. We employed omental interposition whenever this was possible during abdominal exploration.

The use of a peritoneal flap is useful as a barrier against recurrence<sup>14</sup>. A labial fat pad (Martius flap) can be interposed between the bladder and vagina after transvaginal closure of the fistula<sup>15</sup>. Martius flap provides highly vascularized tissue between the closed defects in patients with urethrovaginal fistulae and fistulae involving the bladder neck<sup>8,9,15</sup>. Ureterovaginal fistulae should be corrected as early as possible to avoid renal damage due to ureteric obstruction and ascending infection<sup>2</sup>. However, if there is a combined vesicovaginal

and ureterovaginal fistula, one should wait for 4-6 months before attempting to correct the vesicovaginal fistula. Attempts at early repair are usually difficult due to tissue edema and fragility, and a temporary percutaneous nephrostomy should be performed<sup>5</sup> in order to tide the patient over the waiting period.

In conclusion, thorough urological evaluation of complex urinary fistulae is recommended. The treatment should be individualized based on the existing pathology and may include bladder augmentation and construction of a bladder tube.

## REFERENCES

1. Blaivas JG, Heritz DM, Romanzi LJ. Early versus late repair of vesicovaginal fistulas: Vaginal and abdominal approaches. *J.Urol.* 1995; Apr;153(4):1110,2; discussion 1112-3.
2. Blandy JP, Badenoch DF, Fowler CG, Jenkins BJ, Thomas NW. Early repair of iatrogenic injury to the ureter or bladder after gynecological surgery. *J.Urol.* 1991; Sep;146(3):761-5.
3. Zinman L, Libertino JA. Techniques in the management of the recurrent vesicovaginal fistula. *Surg.Clin.North Am.* 1973; Apr;53(2):479-83.
4. Drutz HP, Mainprize TC. Unrecognized small vesicovaginal fistula as a cause of persistent urinary incontinence. *Am.J.Obstet.Gynecol.* 1988; Feb;158(2):237-40.
5. Gan E, Li MK. Repair of complex ureterovaginal and vesicovaginal fistulas with ileal cystoplasty and ureteric reimplantation into an antireflux ileal nipple valve- a case report. *Ann.Acad.Med.Singapore.* 1998; Sep;27(5):707-9.
6. Thuroff JW, Bazeed MA, Schmidt RA, Tanagho EA. Urodynamic evaluation of a bladder flap tube as urinary sphincter. *Neurology and Urodynamics.* 1982; May 16-20;1:113-22.
7. Naru T, Rizvi JH, Talati J. Surgical repair of genital fistulae. *J.Obstet.Gynaecol.Res.* 2004; Aug;30(4):293-6.
8. Smith GL, Williams G. Vesicovaginal fistula. *BJU Int.* 1999; Mar;83(5):564,9; quiz 569-70.
9. Arrowsmith SD. Genitourinary reconstruction in obstetric fistulas. *J.Urol.* 1994; Aug;152(2 Pt 1):403-6.
10. Tancer ML. A report of thirty-four instances of urethrovaginal and bladder neck fistulas. *Surg.Gynecol. Obstet.* 1993; Jul;177(1):77-80.
11. Turner WR. The use of the Omental Pedicle Graft in Urinary Tract Reconstruction. *J.Urol.* 1976;116(3):341-7.

12. O'Connor VIJ. Transperitoneal repair of vesicovaginal fistula with omentum interposition. AUA Update Series. 1991;10(Lesson 3):97-105.
13. Kiricuta I, Goldstein AM. The repair of extensive vesicovaginal fistulas with pedicled omentum: A review of 27 cases. J.Urol. 1972; Nov;108(5):724-7.
14. Raz S, Bregg KJ, Nitti VW, Sussman E. Transvaginal repair of vesicovaginal fistula using a peritoneal flap. J.Urol. 1993; Jul;150(1):56-9.
15. Leach GE. Urethrovaginal fistula repair with Martius labial fat pad graft. Urol.Clin.North Am. 1991; May;18(2):409-13.