

## Original Article **Pure Primary Small Cell Carcinoma of the Bladder- A propos of 5 Cases**

**S. Ketata<sup>1</sup>, H. FakhFakh<sup>1</sup>, H. Ketata<sup>1</sup>, A. Sahnoun<sup>1</sup>, A. Bahloul<sup>1</sup>,  
T. Boudawara<sup>2</sup> and M. N. Mhiri<sup>1</sup>**

*<sup>1</sup>Department of Urology, <sup>2</sup>Histopathology Laboratory, CHU Habib Bourguiba, Sfax, Tunisia*

### ABSTRACT

**Objective:** Pure primary small cell carcinoma (PSCC) of the bladder is a rare tumor, and patients commonly present with metastatic disease. No prospective studies evaluating the most efficient treatment have been published. We reviewed our experience with treating these tumors to evaluate their histopathological characteristics and clinical outcome.

**Patients and Methods:** This study presents our experience in 5 patients with PSCC of the bladder during a 7-year period. The patients' tumor characteristics, therapy, follow-up and survival status were documented.

**Results:** All patients were male with a mean age of 67 years. The main clinical presentation was macroscopic hematuria. All tumors were invasive at the time of diagnosis. Systemic chemotherapy was given in 4 patients, and one patient was treated by radical cystectomy. The overall median survival was 17 months.

**Conclusion:** PSCC of the bladder should be considered a systemic disease, because most patients present with metastases. Prospective studies are needed to determine the optimal treatment.

**Keywords:** bladder neoplasm, chemotherapy, chromogranin, small cell carcinoma, synaptophysin

**Corresponding Author:** Sabeur Ketata, MD Ph D, Service d'Urologie, Centre Hospitalier de Saint Malo, 1 rue de la merne, 35403, Saint Malo, FRANCE, Email: [sabeurketata@yahoo.fr](mailto:sabeurketata@yahoo.fr)

**Article Info:** Date received: 27/4/2007      Date accepted (after revision): 25/8/2007

## INTRODUCTION

Extrapulmonary small cell carcinoma is a highly malignant tumor. It occurs at different sites, such as the gastrointestinal tract, thymus, larynx, salivary gland, skin, breast, prostate and cervix<sup>1</sup>. In contrast to its frequent occurrence in the lung, pure primary small cell carcinoma (PSCC) of the bladder accounts for only 0.48 to 1% of all bladder malignancies<sup>2</sup>. The immunohistochemical characterization of this tumor is now well described<sup>3</sup>. PSCC of the bladder has an aggressive behavior pattern, similar to PSCC arising elsewhere in the body, with up to 90% of patients developing metastatic disease<sup>1</sup>.

The best treatment strategy for this rare tumor remains unknown. However, surgery,

chemotherapy and radiotherapy have all been used, either alone or in combination. Because of the rarity of this tumor, no prospective trials have been performed to evaluate the optimal treatment.

Based on our experience in 5 patients with PSCC of the bladder and a review of the literature, we outline some common clinical characteristics and the management of this disease.

## PATIENTS AND METHODS

From 2000 to 2006, 5 patients with a histopathologic diagnosis of PSCC of the

PURE PRIMARY SMALL CELL CARCINOMA OF THE BLADDER

Table 1: Summary of patient details.

Patient	Age (years)	Sex	Immunohistochemistry	Stage	Site of metastases	Treatment	Outcome
1	58	male	Synaptophysin + Chromogranin +	T <sub>2</sub> N <sub>1</sub> M <sub>1</sub>	pelvic lymph nodes, pulmonary	<ul style="list-style-type: none"> <li>chemotherapy: 2 cycles of 5- fluorouracil (1000 mg/m<sup>2</sup>)</li> <li>bilateral cutaneous ureterostomy</li> </ul>	alive with disease at 18 months
2	72	male	Synaptophysin + Chromogranin +	T <sub>2</sub> N <sub>2</sub> M <sub>1</sub>	pelvic lymph nodes, adrenal	<ul style="list-style-type: none"> <li>chemotherapy: 3 cycles of carboplatin (AUC = 5 mg x min/ml) and etoposide (100 mg/m<sup>2</sup>)</li> </ul>	no clinical evidence of disease at 24 months
3	75	male	Synaptophysin + Chromogranin +	T <sub>2</sub> N <sub>0</sub> M <sub>0</sub>		<ul style="list-style-type: none"> <li>cystoprostatectomy</li> <li>chemotherapy: 6 cycles of etoposide (100 mg/m<sup>2</sup>) and cisplatin (75 mg/m<sup>2</sup>)</li> </ul>	bone metastases at 9 months, alive with disease at 28 months
4	60	male	Synaptophysin + Chromogranin + Neuron-specific enolase +	T <sub>3</sub> N <sub>0</sub> M <sub>1</sub>	skeletal	<ul style="list-style-type: none"> <li>chemotherapy: 6 cycles of etoposide (100 mg/m<sup>2</sup>) and cisplatin (75 mg/m<sup>2</sup>)</li> </ul>	cancer death at 10 months
5	69	male	Synaptophysin + Chromogranin +	T <sub>2</sub> N <sub>1</sub> M <sub>1</sub>	skeletal	<ul style="list-style-type: none"> <li>chemotherapy: 1 cycle of carboplatin (AUC = 5 mg x min/ml) and etoposide (100 mg/m<sup>2</sup>)</li> </ul>	cancer death at 6 months

bladder made by transurethral resection of the bladder tumor (TURBT) were included in a prospective study. The incidence in our hospital was 1% (5 cases among 496 primary bladder tumors treated). In all patients, the lesion had the characteristic histological features of small cell carcinoma (SCC) such as a high nucleus to cytoplasm ratio with no appreciable cytoplasm, and coarse chromatin with absence of prominent nucleoli and nuclear molding. Immunohistochemistry (neuron-specific enolase, chromogranin and synaptophysin) was performed.

The patient records for all cases were retrieved, including patient age at diagnosis, gender, smoking history, presenting symptoms, histology and staging details, results of initial investigations, initial and subsequent management, disease status at last follow-up, date of death and whether death was disease-specific.

Blood biochemistry analyses including full blood count, renal and liver function tests and serum PSA were performed at presentation. The TNM stage was determined using all the sources available, including TURBT findings, clinical examination, histologic examination and radiographic studies. PSCC from other organs was excluded using computed tomography of chest, abdomen and pelvis and colonoscopy. Management details including any surgery, drugs and doses of chemotherapy were evaluated.

## RESULTS

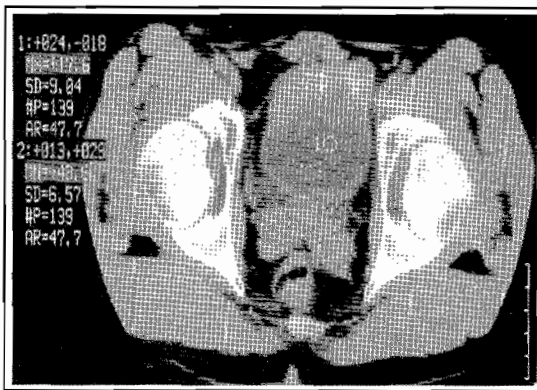
All patients were male with a mean age of 67 years (Table 1).

The main clinical presentation was macroscopic hematuria.

**Table 2:** Blood biochemistry analyses at presentation.

Serum PSA (< 4ng/mL) *	SGPT (10-45 UI/L)*	SGOT (10-40 UI/L) *	Serum creatinine (65-120 μM/L) *	Platelets (160-500 × 10 <sup>9</sup> /mL)*	WBC (4-10 × 10 <sup>9</sup> /mL)*	Hemoglobin (14-17 g/dL)*	Patient
1	13	24	276	332	6.2	12.8	1
0.1	25	18	63	258	7.1	13	2
0.36	38	18	79	268	6	14.5	3
0.65	17	26	85	321	7.5	14	4
1.2	28	33	82	198	5.7	15	5

\* normal values



**Fig. 1:** Case 5: Contrast-enhanced computed tomography scan revealing the bladder dome tumor, with irregular wall contours.

The blood biochemistry analysis was normal in all but one patient (case 1) who had renal dysfunction with an elevated serum creatinine (Table 2).

The medical history was insignificant in 3 patients (cases 2, 3, 4), while one patient (case 1) had a history of surgery for a bladder stone at the age of 32, and the remaining patient (case 5) was a heavy smoker (40 packages/year) and had had 2 episodes of urinary tract infection.

The diagnosis of bladder tumor was based on cystoscopy only in 3 patients, while in 2 patients it was based on ultrasound and CT (Fig. 1) and confirmed by cystoscopy. All patients were subjected to TURBT.

Histopathologic examination revealed:

- PSCC of the bladder (stage T<sub>2</sub>N<sub>1</sub>M<sub>1</sub>) in case 1,

- myoinvasive PSCC of the bladder (stage T<sub>2</sub>N<sub>2</sub>M<sub>1</sub>) in case 2 (Fig. 2),
- myoinvasive PSCC with negative immunohistochemical staining for prostate specific antigen, with involvement of the prostatic urethra (stage T<sub>2</sub>N<sub>0</sub>M<sub>0</sub>) in case 3 (Fig. 3),
- PSCC of the bladder (stage T<sub>3</sub>N<sub>0</sub>M<sub>1</sub>) in case 4 and ,
- invasive PSCC (stage T<sub>2</sub>N<sub>1</sub>M<sub>1</sub>) in case 5 (Table 1).

Computed tomography (CT) revealed bilateral ureteric obstruction in case 1. In case 3 no metastases could be detected after TURBT. The patient underwent radical cystoprostatectomy, urethrectomy and Bricker-type urinary diversion. Nine months post-operatively, the diagnosis of bone marrow metastases was made by bone scan and magnetic resonance imaging.

All patients were treated by chemotherapy as shown in Table 1. Case 5 received one cycle of carboplatin and etoposide only, as he developed an infection that precluded further chemotherapy; he died 6 months after diagnosis.

The overall mean survival was 17 months.

## DISCUSSION

Primary small cell carcinoma occurs at several sites along the urinary tract, but the

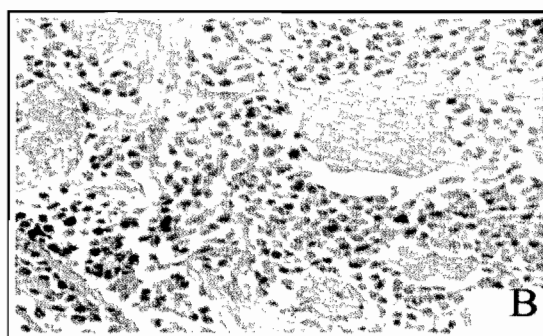
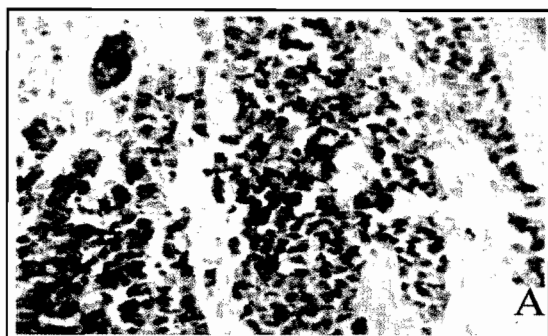


Fig. 2: Magnification of transurethral resection specimen with diffuse immunohistochemical staining for synaptophysin (A) and corresponding hematoxylin-eosin stain (B) from patient 2. Original magnification x 400.

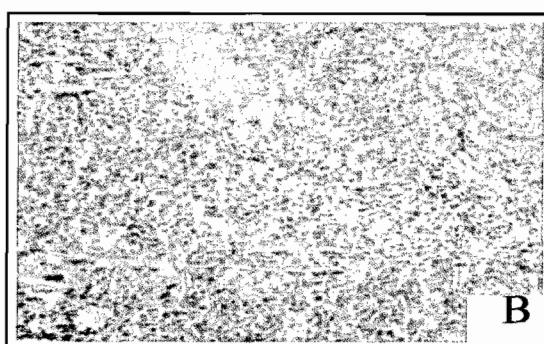
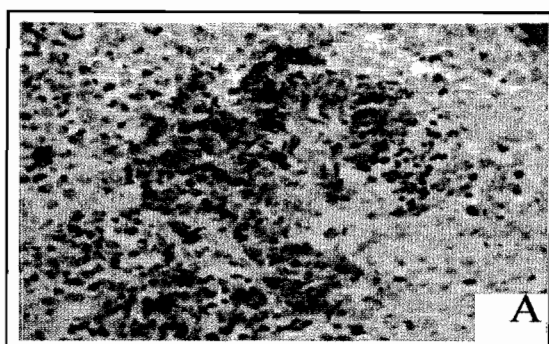


Fig. 3: Magnification of transurethral resection specimen with immunohistochemical staining for chromogranin (A) and corresponding hematoxylin-eosin stain (B) from patient 3. Original magnification x 400.

bladder is the most frequently reported<sup>1</sup>. PSCC of the bladder is a rare tumor, and should be suspected in older men presenting with gross hematuria. Patients suffering from this cancer usually present with an advanced stage of the disease<sup>2</sup>. Bladder PSCC metastasizes to local or distant lymph nodes, liver, bone, lung, brain, adrenal gland, spleen and abdominal cavity, and paraneoplastic syndromes are uncommon<sup>4</sup>.

The differential diagnosis of PSCC of the bladder includes small cell metastasis from a site outside the bladder, a poorly differentiated transitional cell carcinoma (TCC), and primary or secondary lymphoma. It is important to rule out other primary tumors with CT scans of the chest and abdomen. On gross pathology, the tumors tend to present as large, invasive, sessile or polypoidal, ulcerated, and frequently necrotic bladder lesions. The tumor shows a characteristic

microscopic appearance composed of sheets and nests of small round tumor cells containing hyperchromatic nuclei<sup>2</sup>. On electron microscopy intracytoplasmic neurosecretory granules can be found in SCC cells<sup>2</sup>. Immunohistochemically, they react to neuroendocrine markers (chromogranin, synaptophysin, or both). Neuron-specific enolase is almost always positive, although this marker is not regarded as specific<sup>1</sup>. The histopathologic findings in our patients confirmed the diagnosis of SCC.

The histogenesis of bladder PSCC remains unclear. There are two possible explanations for its origin<sup>2</sup>. The tumor may arise from a neuroendocrine Kultschitzky-like stem cell that exists in the urothelium of the bladder. The second possibility is that these tumors arise from poorly defined submucosal or muscularis cells of neural crest origin<sup>3</sup>.

The prognosis in patients with neuroendocrine tumors of the bladder remains poor despite an aggressive surgical approach and improvements in systemic multi-agent chemotherapy. Even though PSCC of the bladder is a rare tumor and optimal management has not been defined, it is clear that patients are at high risk for systemic metastases and should be considered for adjuvant protocols<sup>5</sup>.

Systemic chemotherapy is likely to have a significant role in the management of this high-risk disease. Although no standardized chemotherapeutic regimen was used in this study, etoposide and cisplatin or carboplatin appeared to provide better control of the small cell component than regimens typically reserved for TCC<sup>3</sup>. In a review of 1995, Abbas et al. observed that the best disease-free survival was obtained with cystectomy followed by chemotherapy (median survival 21.1 months)<sup>4</sup>. Given the small number of patients treated with chemotherapy in this study, it is not possible to account for other covariates, such as stage, which could affect response to chemotherapy. Etoposide-cisplatin based chemotherapy regimens had proven efficacy in patients with PSCC of the lung and were employed in the majority of cases of PSCC of the bladder treated with curative intent<sup>3</sup>.

We conclude that, because of the rarity of neuroendocrine tumors of the bladder, definitive conclusions regarding optimal management cannot be made. To our knowledge, only 25 cases of PSCC of the urinary bladder have been described in the literature<sup>5-8</sup>. These aggressive tumors tend to

present at an advanced stage and tend to recur and progress despite surgical resection and systemic chemotherapy<sup>5</sup>. The only long-term survivors appear to be patients in whom the tumor was organ-confined. There is clearly a need for methods of earlier detection of these tumors, when they are more likely to be localized. Prospective studies are necessary to define the impact of combined modality therapy for primary small cell bladder carcinoma.

## REFERENCES

1. Mangar SA, Logue JP, Shanks JH, Cooper RA, Cowan RA, Wylie JP. Small-cell carcinoma of the urinary bladder: 10-year experience. *Clin.Oncol.(R.Coll.Radiol)*. 2004; Dec;16(8):523-7.
2. Kim JC. CT features of bladder small cell carcinoma. *Clin.Imaging*. 2004; May-Jun;28(3):201-5.
3. Karpman E, Goldberg Z, Saffarian A, Gandour Edwards R, Ellison LM, deVere White RW. Analysis of treatment for small cell cancer of the bladder and report of three cases. *Urology*. 2004; Sep;64(3):494-8.
4. Abbas F, Civantos F, Benedetto P, Soloway MS. Small cell carcinoma of the bladder and prostate. *Urology*. 1995; Nov;46(5):617-30.
5. Quek ML, Nichols PW, Yamzon J, Daneshmand S, Miranda G, Cai J, et al. Radical cystectomy for primary neuroendocrine tumors of the bladder: The University of Southern California experience. *J.Urol*. 2005; Jul;174(1):93-6.
6. Tunc B, Ozguroglu M, Demirkesen O, Alan C, Durak H, Dincbas FO, et al. Small cell carcinoma of the bladder: A case report and review of the literature. *Int.Urol.Nephrol*. 2006;38(1):15-9.
7. Abrahams NA, Moran C, Reyes AO, Siefker Radtke A, Ayala AG. Small cell carcinoma of the bladder: A contemporary clinicopathological study of 51 cases. *Histopathology*. 2005; Jan;46(1):57-63.
8. Henno S, Guiraud P, Rioux Leclercq N, Caulet Maugeudre S, Kerbrat P, Lobel B, et al. Une tumeur vésicale rare: Le carcinome à petites cellules. [An uncommon tumor of the urinary bladder: The small cell carcinoma]. *Bull. Cancer*. 2000; Apr;87(4):307-10.