

Original Article

Hinged Transpubic Approach to Delayed Repair of Posterior Urethral Distraction Defects Complicating Pelvic Fractures – Preliminary Experience

A. Essiet¹, P.D. Ekwere¹ and I.A. Ikpeme²

¹Urology and ²Orthopedic Units, Department of Surgery, Faculty of Clinical Sciences, College of Medicine, University of Calabar, Calabar, Nigeria

ABSTRACT

Objective: To present our experience with a transpubic approach to the management of one of the most challenging injuries of the lower urinary tract.

Patients and Methods: Between January 2003 and December 2005, 7 patients presenting to our unit with complex urethral distraction defects due to type 2 or 3 posterior urethral disruption injuries complicating pelvic fracture were included in an ongoing evaluation of the transpubic approach to the repair of such defects. The patients had a mean age of 37.7 (range 22 – 56) years and were followed up for 1 – 4 years.

Results: After the follow-up period 4 patients had a very successful outcome with trouble-free voiding. Three developed strictures, two of which were successfully managed with regular dilatation, while the third patient became catheter-dependent following dilatation and inadvertent creation of a false passage. This patient underwent a successful re-operation with full recovery.

Conclusion: The transpubic approach to delayed repair of urethral distraction defects complicating pelvic fracture is feasible. It allows an effective dissection of the dense hematoma-fibrosis that commonly complicates these injuries at a later stage. The approach is particularly useful in complex long-standing defects where such dissection is made relatively easy by the ample working space provided. The successful outcome of treatment by this approach in 4 and ultimately 5 out of 7 patients offers a reasonable degree of salvage for patients with an otherwise poor prognosis. Further studies are warranted to confirm our positive results.

Key words : Urethra, rupture, stricture, distraction defect, pelvis, fracture.

Corresponding Author: A. Essiet, Urology Unit, Dept. of Surgery, College of Medicine, University of Calabar Calabar, Nigeria, Email: esheto4@yahoo.com

Article Info: Date received : 25/4/2007

Date accepted (after revision): 30/4/2008

INTRODUCTION

Complex urethral injury is one of the most daunting complications of pelvic fractures and often presents a management dilemma to the urologist. The site of injury is commonly the prostatomembranous junction¹. In the fully grown adult the prostatic urethra is seldom involved, whereas the more fragile prostatic urethra of the younger pre-pubescent male can be involved^{2,3}. Management of these injuries remains controversial especially as regards the timing of operative intervention and depends on the type of injury^{2,4}.

In type 1 injury where the urethra is merely stretched and not breached, immediate diversion of urine or placement of an aligning catheter may be all that is required for the urethra to heal virtually unscarred or with an easily managed stricture⁵. In types 2 and 3 injuries which are often associated with other injuries, extensive hematoma and urinary extravasation, a delay in definitive treatment of the urethral defect may sometimes be inevitable. Management options for these more serious injuries include delayed primary realign-

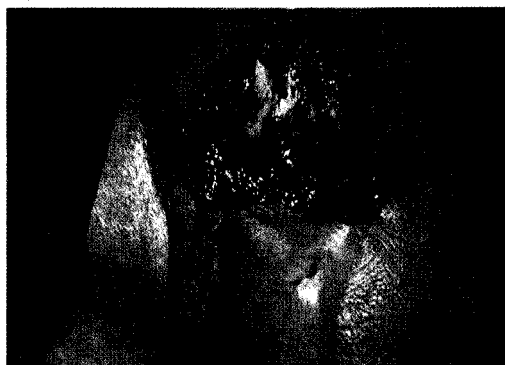

Fig 1: Flap of pubic bone reflected cephalad and held in place with a nylon suture. Note the ample working space

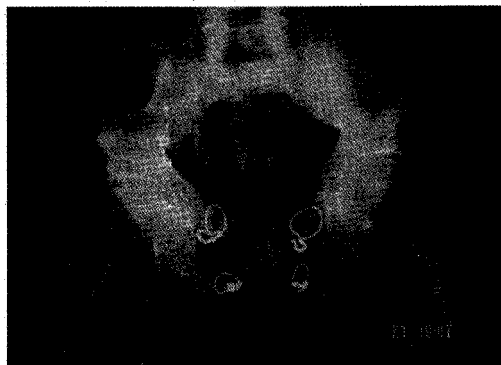


Fig. 2: Flap of pubic bone wired back into place.

ment of the urethra, in which case definitive repair is attempted 10 to 15 days post-injury⁶ or delayed repair where definitive surgery is not carried out until 3 months or more post-injury⁵.

The urethra is injured in only about 5-10% of pelvic fractures¹, which occur in only about 10% of major trauma cases. Major posterior urethral injury is thus a relatively rare condition. For this reason extensive cumulative experience in its management by a single urology unit is not commonplace. In his review of 145 cases treated during a 17-year period, Koraitim found that in selected patients anastomotic urethroplasty, whether performed by the perineal (95%) or transpubic (97%) approach, was almost always successful for the repair of posterior urethral strictures and disruptions complicating pelvic fracture urethral injury⁷.

Our preliminary experience with delayed treatment of some of these injuries, using a transpubic approach constitutes the subject of this report.

PATIENTS AND METHODS

Between January 2003 and December 2005, 12 patients with a mean age of 34.3 (range 22 – 56) years were referred to our service with different degrees of urethral distraction defects complicating bulbar or posterior urethral rupture injuries. Five patients (41.7%) who presented with less complex

distraction defects (<2 cm in length, no side tracking, no fistulation and no displacement of the distracted ends of the urethra) were treated by the perineal approach which is the standard procedure for such injuries in this centre.

Seven patients (58.3%) with complex defects were considered suitable for the hinged transpubic approach and are included in this study. The inclusion criteria were: a long defect (>2 cm), sidetracking, false passages, mal-alignment of the distracted ends of the urethra, stability of the pelvic fracture, absence of a bulbo-penile stricture and no previous history of bladder neck surgery. The availability of a combined retrograde and antegrade contrast study of the lower urinary tract was a basic prerequisite for inclusion in the study.

Repair of these complex defects was carried out starting from 6 months post-injury. The patients were operated under regional (epidural) anesthesia. Access to the pubic bone was achieved by an inverted 'Y' incision starting midway between the umbilicus and the pubic bone and bifurcating just proximal to the root of the penis. The periosteum of the pubic bone with the suspensory ligament was reflected downwards with the penis. The orthopedic surgeon using a Gigli saw raised a segment of the pubic bone hinged on the rectus muscles as flap. The flap so raised was reflected cephalad, thus offering a relatively generous access to the retropubic space for work on the injured posterior urethra (Fig. 1).

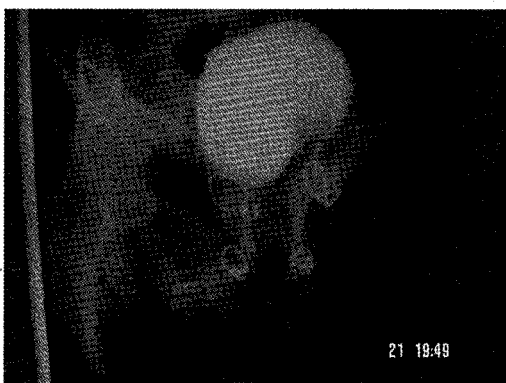

Fig 3: Free retrograde flow of contrast medium through false passage into bladder.

Repair entailed careful dissection and excision of the dense hematoma-fibrosis (result of organized hematoma and extravasated urine) until the proximal and distal ends of the distracted urethra identified by the passage of dilators became supple and mobile. Any malalignments were corrected and the blind distracted ends of the urethra were opened, spatulated and anastomosed end-to-end around a 14F or 16F Foley catheter, using 3-0 to 5-0 coated vicryl (polyglactin 910) sutures. The pubic bone flap was wired back in place and the wound closed with a drain to the repair site (Fig. 2). All the patients were given adequate antibiotic cover based on urine culture and sensitivity reports. Peri-catheter urethrograms were obtained 3 weeks post-repair and if no extravasation occurred the catheters were removed. The patients were followed up for between 1 and 4 years.

RESULTS

Complications following the procedure are presented in Table 1. One patient (14.3%) developed transient incontinence which was cured with targeted physiotherapy. Another patient in whom the pubic bone flap was inadvertently detached from the rectus muscles during surgery developed osteitis pubis with loss of the pubic bone flap which fortunately did not affect his gait.

After the follow-up period 4 patients had a very successful outcome with trouble-free voiding. Three patients developed

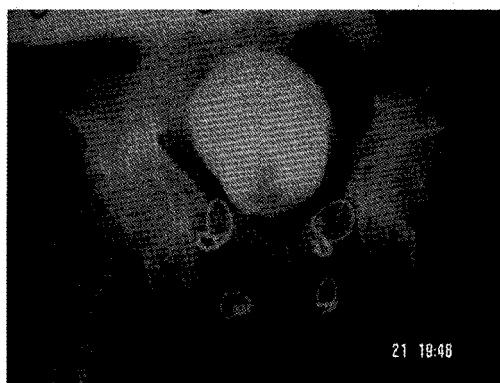


Fig 4: Attempt at micturating cystourethrogram – the patient was unable to void.

membranous strictures at the point of anastomosis. Two of them were doing well on regular dilatation. The third patient became catheter-dependent after the first dilatation. The catheter would go in easily without any hindrance, but upon removal the patient could not void. It was suspected that a false passage had been created during dilatation. Retrograde urethrography showed free flow of contrast into the bladder (Fig.3), but an attempt at micturating cysto-urethrography was unsuccessful (Fig. 4). The false passage was confirmed at re-operation, which was carried out by an up-and-down abdominoperineal approach. The prostatic-bulbar anastomosis was revised and the patient recovered normal voiding function. The patients' characteristics, outcome of treatment as well as complications are summarized in Table 2.

DISCUSSION

Posterior urethral injuries complicating pelvic fractures are not common, yet they attract much attention because of the management challenge they pose. Many urologists prefer to offer suprapubic diversion of urine alone in the acute phase of the injury, fearing that passage of a catheter per urethram may cause infection or convert a partial to a complete rupture. Some attempt to realign the urethra in the acute phase of the injury, believing that this may minimize the risk of subsequent stricture formation⁸. Others adopt the approach of offering delayed primary re-

Table 1: Complications of hinged transpubic repair of urethral distraction defects (n=7).

Complications	No of Patients	%
Transient incontinence	1	14.3%
Stricture	3	42.8%
Osteitis pubis	1	14.3%
Impotence	1	14.3%
Mortality	Nil	Nil

alignment⁶. More recently, early endoscopic realignment has been undertaken⁹.

Definitive surgery in the acute phase of injury minimizes the risk of subsequent stricture formation, and anastomotic repair is also relatively easier during this period because the distracted ends of the urethra are supple and mobile, having not yet been incarcerated by fibrosis. However, the risk of severe bleeding necessitating blood transfusion when surgery is undertaken at this time is quite high. Such situations are best avoided in our setting where blood for transfusion is usually not readily available¹⁰. Even if blood were readily available, the scourge of HIV-AIDS in recent times has increased caution in the use of homologous blood transfusion. On the other hand, primary suturing of the disrupted ends of the urethra is reported to have significant complication rates of incontinence and erectile dysfunction (21% and 56%, respectively)^{2,11}.

A fractured pelvis complicated by posterior urethral rupture usually results from severe trauma. As such, apart from instability of the pelvic fracture, the patients often have serious associated injuries to abdominal structures and bones of the extremities. Immediate exploration of the retropubic space therefore carries a high risk in terms of morbidity and even mortality. Immediate alignment or delayed primary alignment is often not expedient, leaving delayed repair as the safer option of management. By the 4th to 6th month of injury, the minimum period recommended for delayed repair⁴, associated

injuries would have resolved and the pelvic fracture healed, restoring pelvic stability, a necessary condition for the transpubic approach that was used in this study.

Most defects from posterior urethral rupture are not long, and are therefore amenable to a technically straightforward perineal approach. In this series about half of the patients seen during the period were treated by this approach, which is our standard approach for uncomplicated distraction defects. The transpubic route pioneered by Waterhouse and co-workers¹² is not widely practiced. It has even been considered unnecessary for the repair of distraction injury of the posterior urethra⁵. However, we find that for those presenting with complex distraction injuries, associated with sidetracking and fistulas, the transpubic route provides better access for effective and careful dissection of the dense hematoma-fibrosis that usually results from resolved hematoma of the injury and extravasated urine. To adequately free the incarcerated distracted ends of the urethra this dissection is crucial for the effective mobilization necessary for tension-free anastomosis¹³.

The 7 patients in this series who presented with long-standing complex distraction defects were thus treated by the transpubic approach. They were operated between 6 and 15 (average 9) months post-injury, chiefly because of their delayed presentation. The longer the interval between injury and operation, the more tenacious the incarceration of the distracted ends of the urethra and the

Table 2: Patients' characteristics, outcome and complications of transpubic repair of complex urethral distraction defects (n=7)

S/N	Age (Yrs)	Time elapsed since injury (months)	Associated injuries	Result of treatment	Complications of treatment
1	22	7	Bruises	Successful voiding	Nil
2	29	6	Bladder rupture	Successful voiding	Osteitis pubis
3	33	6	Fracture humerus	Successful voiding	Nil
4	35	8	Splenic rupture	Dilatation required	Stricture at point of anastomosis
5	42	15	Bilateral femur fracture	Dilatation required	Stricture at point of anastomosis
6	47	9	Scrotal laceration	Successful voiding	Transient incontinence
7	56	11	Bladder rupture	False passage on dilatation; successful voiding after reoperation	Stricture at point of anastomosis, impotence

more difficult and demanding the dissection. This is where the transpubic approach proves advantageous because of the ample working space provided.

The procedure in our patients was safe and straightforward. Appropriate antibiotic prophylaxis was used in all cases. Operation time was between 2 and 4 hours depending on how complex the injury was. Two of the patients required blood transfusion in the peri-operative period, even though a deliberate policy of 'bloodless' surgery and therefore adequate pre-emptive hematinic therapy was adopted in all cases. The one patient who underwent reoperation reported impotence. Whether this was as a result of the operations for treatment or the primary injury is difficult to say, but an impotence rate of up to 30% has been reported even with primary endoscopic management of these cases¹⁴. The patients all recovered with normal gait on discharge, including the one with osteitis pubis. There was no mortality and during follow up for 1 - 4 years four patients had normal trouble-free voiding, giving a success rate of 57% - or 71% if the successful re-operation with spatulated anastomosis is added.

The results of this small, preliminary series indicate that the transpubic approach promises a reasonable degree of salvage for patients with an otherwise poor prognosis. It is recommended for delayed repair of complex posterior urethral distraction defects that may follow urethral rupture, complicating pelvic fracture.

REFERENCES

1. McAninch JW. Traumatic injuries to the urethra. *J.Trauma*. 1981; Apr;21(4):291-7.
2. Koraitim MM. Pelvic fracture urethral injuries: The unresolved controversy. *J.Urol*. 1999; May;161(5):1433-41.
3. Al Rifaei MA, Al Rifaei AM. Management of urethral injuries secondary to pelvic fracture in the male. *Afr.J.Urol*. 2006;12(4):170-6.
4. Colapinto V, McCallum RW. Injury to the male posterior urethra in fractured pelvis: A new classification. *J.Urol*. 1977; Oct;118(4):575-80.
5. Jordan GH, Schollsberg SM, Devine CJ. Surgery of the penis and urethra. In: Campbell MF, Retik AB, Vaughan ED, Walsh PC, editors. *Campbell's urology*. 7th ed. : W.B. Saunders Company; 1997. p. 3362-9.

6. Shittu OB, Okeke LI, Kamara TB, Adebayo SA. Delayed primary realignment of posterior urethral rupture. *West Afr.J.Med.* 2003; Jun;22(2):133-5.
7. Koraitim MM. The lessons of 145 posttraumatic posterior urethral strictures treated in 17 years. *J.Urol.* 1995; Jan;153(1):63-6.
8. Myers RP, Deweerdt JH. Incidence of stricture following primary realignment of the disrupted proximal urethra. *J.Urol.* 1972; Feb;107(2):265-8.
9. Moudouni SM, Patard JJ, Manunta A, Guiraud P, Lobel B, Guille F. Early endoscopic realignment of post-traumatic posterior urethral disruption. *Urology.* 2001; Apr;57(4):628-32.
10. Emeribe AO, Ejele AO, Attai EE, Usanga EA. Blood donation and patterns of use in southeastern Nigeria. *Transfusion.* 1993; Apr;33(4):330-2.
11. Aboutaieb R, Sarf I, Dakir M, el Moussaoui A, Joual A, Meziane F, et al. Le traitement chirurgical des ruptures traumatiques de l'urethre posterieur. [Surgical treatment of traumatic ruptures of the posterior urethra]. *Prog.Urol.* 2000; Feb;10(1):58-64.
12. Waterhouse K, Abrahams JI, Gruber H, Hackett RE, Patil UB, Peng BK. The transpubic approach to the lower urinary tract. *J.Urol.* 1973; Mar;109(3):486-90.
13. Koraitim MM. Failed posterior urethroplasty: Lessons learned. *Urology.* 2003; Oct;62(4):719-22.
14. Jepson BR, Boullier JA, Moore RG, Parra RO. Traumatic posterior urethral injury and early primary endoscopic realignment: Evaluation of long-term follow-up. *Urology.* 1999; Jun;53(6):1205-10.