

CASE REPORTS

NORMAL SERUM ALKALINE PHOSPHATASE IN THE PRESENCE OF EXTENSIVE SKELETAL METASTASES OF PROSTATE CANCER

A. ABDUL-MOHSEN¹, E. O. KEHINDE¹, I. LOUTFI², Y. ALI AND O. O. ROBERTS³

¹Departments of Surgery (Division of Urology), ²Nuclear Medicine and ³Radiology.
Mubarak Al-Kabeer Hospital, Faculty of Medicine, Kuwait University, Kuwait.

Alkaline phosphatase (ALP) is a nonspecific tumor marker as it is neither organ nor tumor specific. An elevation of the enzyme in relation to carcinoma of the prostate is usually due to bone or liver involvement, or both, by metastatic disease. We report the case of a 91-year-old man who presented with chronic urinary retention. Investigations revealed prostate specific antigen (PSA) of 831.4 ng/ml, biochemical evidence of moderate renal impairment, normal liver function tests and normal alkaline phosphatase. Whole body skeletal scintigraphy with ^{99m}Tc-MDF showed widespread skeletal metastases. Transrectal ultrasound of the prostate revealed a 40 gm prostate gland with a hypoechoic defect in the periphery of the gland. Prostate biopsy revealed prostate cancer (Gleason's score 8). Total serum testosterone, zinc and magnesium were below the normal range. Bone densitometry revealed osteoporosis. Channel transurethral resection of the prostate was performed together with bilateral orchidectomy. Testicular histology revealed atrophic testes. Normal serum alkaline phosphatase in this patient in the presence of extensive skeletal metastases may be due to the combination of the following factors: relative hypogonadism, osteoporosis, low serum zinc and magnesium. This case report may provide a possible explanation for the observation that about 10% of men with widespread skeletal metastases from prostate cancer may not have elevated serum alkaline phosphatase.

Key Words: serum alkaline phosphatase, tumor marker, prostate cancer, skeletal metastases.

INTRODUCTION

The alkaline phosphatases are a group of enzymes that hydrolyze phosphate esters at pH greater than 7. Alkaline phosphatase (ALP) is a nonspecific tumor marker as it is neither organ nor tumor specific¹. An elevation of the enzyme in relation to carcinoma of the prostate is usually due to bone or liver involvement, or both, by metastatic disease². Total ALP is increased in approximately 60% of patients with untreated prostatic carcinoma, but in only 6% of patients free of prostatic malignancy³. In the latter group, there is usually an obvious clinical explanation for the elevation of ALP³. 91% of all patients with prostatic carcinoma with radiographically documented bone metastases have an elevated serum level of total ALP¹. The bone isoenzyme is most frequently positive in patients with prostatic carcinoma and is felt to be the more accurate

ALP marker for this disease¹. An increased level of this isoenzyme can be demonstrated in approximately 44% of patients with stage C prostatic carcinoma and a normal total serum ALP⁴. Elevation or decrease of total ALP and its isoenzymes have been demonstrated to follow closely the course of a patient's disease^{5,6}.

We report a case of a 91-year-old patient with prostate cancer who had normal serum total ALP despite having widespread skeletal metastases. We try to provide an explanation for this apparent dissociation between serum total ALP and the presence of increased osteoblastic bone activity secondary to metastases from prostate cancer.

CASE REPORT

A 91-year-old man presented with chronic retention of urine with overflow incontinence.

He was bedridden because of orthopedic problems, with a past history of trauma to the back. Physical examination revealed a frail elderly man. The abdomen was soft and lax with a palpable painless bladder. Digital rectal examination revealed an irregular, nodular and mildly enlarged prostate gland. The retention of urine was relieved by insertion of a urethral catheter.

Laboratory investigations on admission revealed the following: Blood urea 30.3 mmol/L (normal 2-6), creatinine 612 $\mu\text{mol/L}$ (normal 60-110), PSA 831.4 ng/ml, ALP 71 IU/L (normal 26-88), hemoglobin (Hb) 11.2 g/dL (low). His serum zinc (Zn) was 584 $\mu\text{g/L}$ (normal: 800-1,200), the serum magnesium (Mg) was 18.5 mg/L (normal 18-24) and total serum testosterone 6.6 nmol/L (normal 8-35). His serum Zn was 570 $\mu\text{g/L}$ and the serum Mg was 18.0 mg/L, 3 months after bilateral orchidectomy and multivitamin supplements.

Abdominal ultrasound revealed a decrease in size of both kidneys with a diffuse increase in echogenicity but a normal pelvicalyceal system. The bladder was trabeculated and thick walled. Transrectal ultrasound (TRUS) of the prostate revealed a 40 gm prostate with heterogeneous texture and few hypoechoic lesions in the periphery. Biopsies were taken from the prostate gland and revealed adenocarcinoma with a Gleason score of 8. Whole body skeletal scintigraphy with $^{99\text{m}}\text{Tc-MDP}$ showed multiple focal areas of radiotracer uptake scattered throughout the skeleton including the ribs, thoracic and lumbar spine and pelvis (Fig. 1). The patient's bone mineral densitometry (BMD) revealed severe osteoporosis and high fracture risk (Fig. 2).

Initial management consisted of channel transurethral resection of the prostate (TURP) and bilateral simple orchidectomy in view of the patient's age. Histology of both testes showed extensive testicular atrophy with only few tubules showing evidence of spermatogenesis (Fig. 3). The patient's post operative course was uneventful. Four weeks and 6 months after bilateral orchidectomy, the patient's serum PSA was 3.8 and 1.9 ng/ml, respectively.

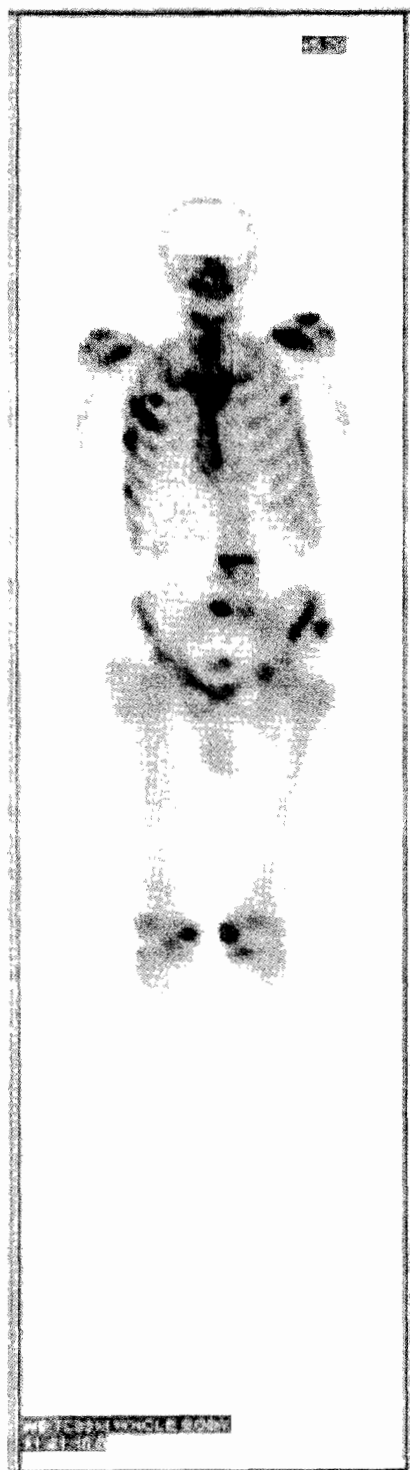


Fig. 1: Whole body skeletal scintigraphy with $^{99\text{m}}\text{Tc-MDP}$ showing multiple bone metastases.

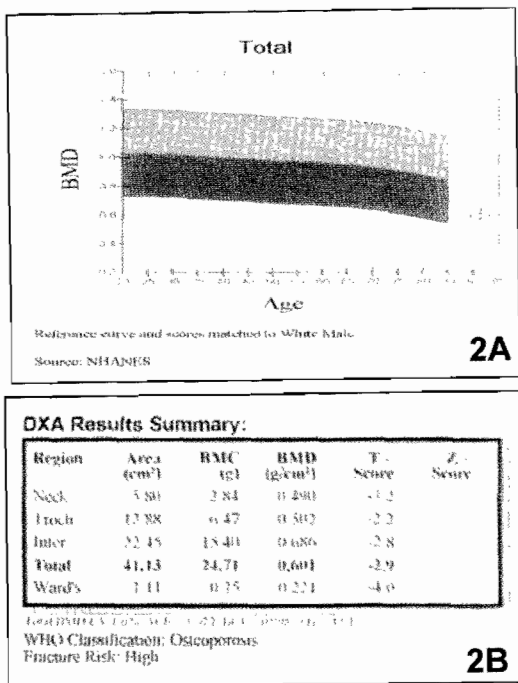


Fig. 2: Bone mineral densitometry of the patient (BMD) showing severe osteoporosis.

DISCUSSION

Prostate cancer is the fourth most common male malignancy worldwide. The skeleton is the most common site of tumor metastasis, and skeletal complications from bone metastases present a major challenge in disease management⁷. Such complications include pathologic fractures, spinal cord compression and severe bone pain. Each of these complications may substantially reduce the quality of life and, in some cases, hasten death⁷. The median survival after diagnosis of bone metastases ranges from 12 to 53 months⁸. The bones are also a relatively frequent site for symptomatic metastases in patients with other solid tumors, including lung, breast, thyroid, renal and bladder cancers⁷.

Metastatic bone disease disturbs the tightly coordinated processes of coupled and balanced osteoclast-mediated bone resorption and osteoblast-mediated bone formation that are involved in repair and

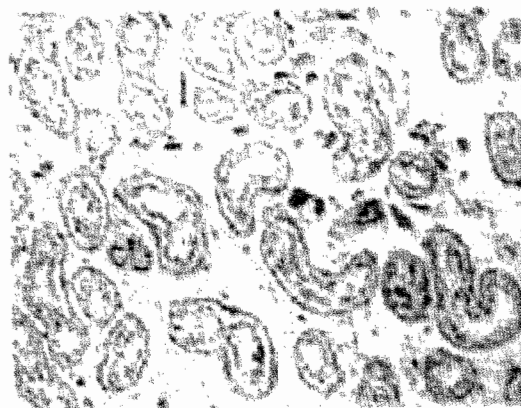


Fig. 3: Histopathology of the patient's testis showing severe atrophic changes, a thickened basement membrane and little evidence of spermatogenesis (H&E x 400).

maintenance of normal bone tissue⁹. Total and bone-specific ALP estimations are often found to be elevated in metastatic disease and may be used along with PSA for the evaluation of prostatic cancer metastases. The success of androgen deprivation therapy (ADT) in the treatment of cancer is related closely to the initial tumor burden. It has been found that the estimation of total and bone-specific ALP at the beginning of the treatment may aid in predicting the response to some of the ADT agents used. The higher the level of ALP, the smaller are the chances of obtaining a good clinical response¹. Thus, the ALP levels indirectly may measure the tumor burden. With clinical response, the levels of ALP diminish and sometimes a gradual increase of total or bone ALP is noticed before any objective or subjective clinical sign of progression of the disease may be seen¹.

Although ALP is an indicator of bone formation and may represent bone healing, a strikingly increased phosphatase activity of bone at the site of osteoblastic skeletal metastases has been observed in patients with carcinoma of the prostate. It is a function of increased osteoblastic activity and leakage into serum. This would provide an indirect marker of clinical progression of the disease. With clinical stabilization or regression of the disease, ALP production diminishes with resultant lower levels as found in some studies^{1,10}.

Our patient presented with chronic urinary retention with overflow incontinence of urine which revealed late presentation due to a slowly progressive disease. The results of investigations in the form of PSA, bone scan and prostatic biopsy supported that impression. The serum level of ALP was inappropriately 71 IU/L which was within the normal range although it was expected to be high in view of the age of the patient and the presence of multiple skeletal metastases from prostate cancer. The patient also had low Zn and Mg levels. The normal ALP in this patient may therefore be related to zinc deficiency, as zinc is a cofactor for this enzyme's activity¹⁰. Also the presence of multiple bone metastases in the presence of a low level of ALP may be explained by the presence of widespread osteoporosis demonstrated in Fig. 2 showing a low bone turnover and low osteoblastic activity and hence low levels of ALP. Osteoporosis and the risk of fracture seen after ADT may be due to a combination of the following factors:

- increasing age leading to increasing osteoporosis and,
- the effect of ADT on bone regeneration in old age accentuated by the absence of the trophic effect of testosterone in patients undergoing ADT.

Our patient had a low serum testosterone on admission.

This case report demonstrates that in very old men malnutrition combined with low levels of trace elements and low testosterone may lead to normal levels of ALP in the presence of widespread skeletal metastases. These findings may provide a rational explanation for previous observations that about 10% of patients with metastatic prostate cancer may present with normal serum ALP.

We conclude that elderly patients with late stage advanced prostatic cancer and

widespread skeletal metastases may have a normal serum level of ALP as a consequence of low serum Zn and Mg, osteoporosis and hypogonadism.

REFERENCES

1. Wajzman Z, Chu TM, Bross D, Saroff J, Murphy GP, Johnson DE, et al. Clinical significance of serum alkaline phosphatase isoenzyme levels in advanced prostatic carcinoma. *J.Urol.* 1978 Feb;119(2):244-6.
2. Killian C, Chu TM, Drzewiecki G, Schmidt K, Kajdasz R, Santalucia J, et al. A simple and reliable method for alkaline phosphatase isoenzymes in prostatic cancer. *Clin.Chem.* 1976;22(7):1174.
3. Goldberg DM, Ellis G. An assessment of serum acid and alkaline phosphatase determinations in prostatic cancer with a clinical validation of an acid phosphatase assay utilizing adenosine 3'-monophosphate as substrate. *J.Clin.Pathol.* 1974 Feb;27(2):140-7.
4. Sullivan TJ, Gutman EB, Gutman AB. Theory and application of the serum "acid" phosphatase determination in metastasizing prostatic carcinoma: Early effects of castration. *J.Urology.* 1942;48:426-58.
5. Grayhack JT, Lee C, Kolbusz W, Oliver L. Detection of carcinoma of the prostate utilizing biochemical observations. *Cancer.* 1980 Apr 15;45(7 Suppl):1896-901.
6. Pontes JE. New assays for prostatic acid phosphatase and alkaline phosphatase isoenzymes. *Urology.* 1981 Mar;17(Suppl 3):38-9.
7. Coleman RE, Rubens RD. Bone metastases. In: Abeloff MD, Armitage JO, Niederhuber J, Kastan M, McKenna WG (editors). *Clinical Oncology*. 3rd ed., New York:Churchill Livingstone;2004. p.1091-128.
8. Coleman RE. Metastatic bone disease: Clinical features, pathophysiology and treatment strategies. *Cancer Treat.Rev.* 2001 Jun;27(3):165-76.
9. Mundy GR, Guise TA. Pathophysiology of bone metastasis. In: Rubens RD, Mundy GR, editors. *Cancer and the Skeleton*. 1st ed. London: Martin Dunitz Ltd;2000. p.43-64.
10. Gutman EB, Sproul EE, Gutman AB. Significance of increased phosphatase activity at the site of osteoplastic metastases secondary to carcinoma of the prostate gland. *Am.J.Cancer.* 1936;28:485-95.

RESUME

Phosphatase alcaline sérique normale en cas de métastases osseuses étendues du cancer de prostate

La phosphatase alcaline (ALPES) est un marqueur non spécifique de tumeur. Une élévation de l'enzyme en cas de carcinome de la prostate est habituellement due à la sécrétion par l'os ou le foie, ou les deux, par la maladie métastatique. Nous rapportons le cas d'un homme de 91 ans qui s'est présenté avec rétention urinaire chronique. Les examens ont montré un antigène spécifique de prostate (PSA) de 831.4 ng/ml, une insuffisance rénale modérée, une fonction hépatique normale et un taux de phosphatase alcaline normal. La scintigraphie osseuse du corps entier a montré des métastases osseuses étendues. L'échographie transrectale de la prostate a montré une prostate de 40 g avec une lésion hypo-échogène dans la périphérie de la glande. La biopsie de prostate a confirmé le cancer de prostate (score 8 de Gleason). La testostérone, le zinc et le magnésium totaux du sérum étaient au-dessous de la normale. La densitométrie osseuse a montré une ostéoporose. La résection trans urétrale de la prostate a été réalisée ainsi qu'une orchidectomie bilatérale. L'histologie testiculaire a montré des testicules atrophiques. La phosphatase alcaline normale chez ce patient en présence des métastases osseuses étendues peut être due à la combinaison des facteurs suivants : hypogonadisme relatif, ostéoporose, taux bas de zinc et de magnésium dans le sérum. Ce cas peut fournir une explication possible pour l'observation qu'environ 10% des hommes avec métastases osseuses de cancer de prostate ne présentent pas une élévation de la phosphatase alcaline dans le sérum.

Corresponding author:
Prof. E.O. Kehinde
Department of Surgery
Division of Urology
Faculty of Medicine,
Kuwait University
P. O. Box 24923
13110 Safat
Kuwait.

e-mail: ekehinde@hsc.edu.kw