

THE MANAGEMENT OF UPPER URINARY TRACT OBSTRUCTION IN RESOURCE-POOR SETTINGS

V.M. RAMYIL , N.K. DAKUM AND E.I. OGWUCHE

Urology Unit, Department of Surgery, Jos University Teaching Hospital (JUTH),
Jos, Nigeria

Objective: The management of upper urinary tract obstruction in the absence of modern facilities presents a major challenge to Urologic practice in developing countries. The aim of this study was to describe the etiology, presentation and treatment of upper urinary tract obstruction at the Jos University Teaching Hospital, Nigeria.

Patients and Methods: This is a prospective analysis of 37 consecutive patients (18 males, 19 females) with a mean age of 35.5 years (range 3-55) who were managed for upper urinary tract obstruction at our department between January 2001 and December 2005. Two of them presented with a second pathology, so that we treated 39 pathologies in total. Flank pain was the most common clinical feature, being present in 35 patients (94.6%). Other clinical features were gross hematuria in 12 (32.4%), an enlarged kidney in 5 (13.5%), renal impairment in 4 (10.8%) and hypertension in 3 (8.1%) patients. Diagnostic work-up consisted of plain radiography, abdominal ultrasound scan, intravenous urography and retrograde pyelography. Renal pelvic stones were the leading cause of obstruction (13 patients;

35.1%), while congenital pelvi-ureteric junction (PUJ) obstruction was found in 7 (18.9%) and ureteric stricture and vesical schistosomiasis in 4 (10.8%) and 3 (8.1%) patients, respectively. Two patients had bilateral obstruction from two different causes.

Results: Twenty-nine open surgical procedures were carried out. They consisted of pyelolithotomy (n=12), pyeloplasty (n=6), ureteroureterostomy (n=4), ureteroneocystostomy (n=3), nephrectomy (n=2) and ureterolithotomy (n=2). Eight patients were treated non-surgically. Two patients are awaiting definitive surgical treatment. A total of 4 (13.8%) complications following 29 operative procedures was encountered: two cases of migration of double-J ureteric stents and one case each of prolonged urine leakage and wound infection.

Conclusions: Upper urinary tract obstruction is not uncommon in our environment. In the absence of modern facilities, open surgery remains our main option of treatment; and it is relatively safe.

Key Words: upper urinary tract obstruction, management, resource-poor setting.

INTRODUCTION

Advances in technology have had a significant impact on both diagnostic and therapeutic aspects in the management of upper urinary tract obstruction¹. The etiology of the obstructive process ranges from congenital to acquired problems, and the cause of obstruction may not be immediately evident. The diagnosis

and treatment of upper urinary tract obstruction cover a spectrum from relatively non-invasive procedures to complex open surgery².

The multitude of treatment options for this condition requires the availability of appropriate equipment and knowledge of the indications for and risks associated with the various procedures^{1,3,4}. Such equipment is not readily

available in most centers in the developing world, and where they are available, the costs are prohibitive. The aim of this paper is to report our experience with the management of upper urinary tract obstruction in a resource-poor setting.

PATIENTS AND METHODS

Between January 2001 and December 2005, 37 patients (18 males, 19 females) with a mean age of 35.5 years (range 3 – 55) presenting with upper urinary tract obstruction were managed at the Urology unit of the Jos University Teaching Hospital, a tertiary health institution in the Middle Belt region of Nigeria. The presenting clinical features are shown in Fig. 1.

Each patient had a full clinical evaluation, followed by investigations to determine the presence and the probable cause of the obstruction. The available investigative modalities included plain abdominal radiography (“kidney, ureters, bladder” or KUB), abdominal and pelvic ultrasonography, intravenous urography, cystoscopy and retrograde pyelography. All patients were subjected to the first three diagnostic modalities. Cystoscopy and ureteric catheterization for retrograde urographic studies were carried out only when indicated, when the first three modalities were not conclusive and when the patient could afford to pay. Renal function was assessed by measuring serum levels of electrolytes, urea and creatinine.

The causes of obstruction and the management are summarized in Table 1. Two patients had bilateral obstruction of different etiologies, so that, in total, 39 pathologies were treated.

RESULTS

Table 2 summarizes the methods of surgical treatment and the complications. All patients treated surgically were subjected to open surgery. Twelve of 13 patients with

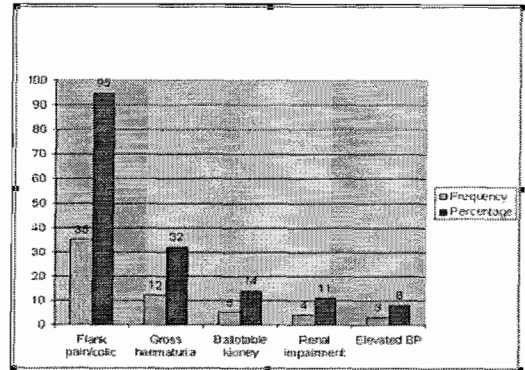


Fig. 1: Clinical features of upper urinary tract obstruction.

renal pelvic stones had open pyelolithotomy, while 6 of 7 patients with congenital pelviureteric junction obstruction were offered open pyeloplasty. Two patients had unilateral nephrectomy. Other open procedures were ureteroureterostomy in 4, ureteroneocystostomy in 3 and ureterolithotomy in 2 patients. One of the 13 patients with renal pelvic stones, and the only case of vesico-ureteric obstruction are awaiting definitive surgical intervention (Table 1).

The remaining 8 patients were treated non-surgically. The two cases of duplex collecting system and the ectopic kidney had symptomatic treatment and antibiotic prophylaxis. Both cases of prostate cancer have been doing well on hormonal manipulation (one had bilateral orchidectomy while the other was placed on luteinizing hormone releasing hormone analogue) for the second year running. One of the 3 patients with vesical schistosomiasis was treated with anti-schistosomal drugs only. The case of cervical cancer and that of bladder cancer received palliative treatment in addition to nephrostomy tube drainage.

There were four postoperative complications: two cases of upward migration of the vesical end of double-J stents, and one case each of prolonged urine leakage and wound infection. There was no death attributable to surgery. Two patients died from the advanced nature of primary pathology (bladder and cervical cancers) despite nephrostomy.

Table 1: Etiology and management of upper urinary tract obstruction in 37 patients with a total of 39 pathologies*

Etiology	No. Pts.	%	Surgical Treatment		Awaiting Operation No.	Non surgical Treatment	
			No.	Procedure		No.	Modality
Renal pelvic stone	13	33.3	12	pyelolithotomy	1		
PUJ Obstruction**	7	17.9	6 1	pyeloplasty nephrectomy			
Ureteric stricture	4	10.2	3 1	ureteroureterostomy ureteroneocystostomy			
Vesical schistosomiasis	3	7.7	2	ureteroneocystostomy/ antischistosomal drugs		1	antischistosomal drugs only
Ureteric stone	2	5.1	2	ureterolithotomy			
Duplex collecting system	2	5.1				2	symptomatic and antibiotics
Prostate cancer	2	5.1				2	hormonal manipulation
Ectopic kidney	1	2.6				1	symptomatic and antibiotics
Bladder cancer	1	2.6				1	palliative nephrostomy
Congenital megaureter	1	2.6	1	nephrectomy			
Aganglionic ureter	1	2.6	1	ureteroureterostomy			
Vesico-ureteric obstruction	1	2.6			1		
Cervical cancer	1	2.6				1	palliative nephrostomy
Total	39	100	29		2	8	

* Two patients had bilateral pathologies of different etiology, ** PUJ = pelvi-ureteric junction

Table 2: Surgical treatment and complications in upper urinary tract obstruction.

Surgical procedure	No. patients	Stenting			Complication (n)
		int	ext	none	
Pyelolithotomy	12	5	3	4	Prolonged leak (1)
Pyeloplasty	6	3	2	1	stent migration (1)
Ureteroneocystostomy	3	1	2	-	-
Ureteroureterostomy	4	4	-	-	wound infection (1)
Nephrectomy	2	na	na	-	-
Ureterolithotomy	2	2	-	-	stent migration (1)
Total	29*	15	7	5	(4)

(int: internal; ext: external; (n): frequency; na: not applicable)

*: one patient had 2 different procedures.

DISCUSSION

Obstruction of the upper urinary tract is not uncommon in our environment and the causes of the obstructive process range from congenital to acquired problems. The leading cause of obstruction in this report was calculous disease, especially stones located in the renal pelvis. Only two of 15 cases of upper tract calculi were located in the ureter in contrast to 315 ureteric calculi reported from a center in India over a three-year period⁵.

Congenital PUJ obstruction was the second leading cause of obstruction in our study. All except one of the cases of congenital PUJ obstruction occurred in adults. The only child in our series was a 3-year-old girl who presented with an enlarging left flank mass which was noticed when she was 6 months old. The late presentation of PUJ obstruction is not unusual, as obstruction in these patients may not become apparent until later in life⁶. Antenatal diagnosis holds the key to early detection and treatment in order to prevent significant renal damage. This is not routine in our setting due to lack of appropriate equipment and expertise.

Four (10.8%) of our patients had ureteric strictures, two of which were secondary to ureteric injury during gynecologic operations. The causative factor in the remaining two was not known, and none gave a history of previous passage of stones.

Vesical schistosomiasis affecting the trigone and lower ureter was the cause of obstruction in 3 (8.1%) of our patients. Prostate cancer accounted for obstruction of the lower ureters in only 2 patients in the five-year period under review, despite the fact that management of advanced prostate cancer constitutes a major part of Urologic cases in our practice. In another center in the same region, over an eight-year period, 44 patients presented with renal insufficiency secondary to low ureteric obstruction due to carcinoma of the prostate⁷. The reason for this difference is not obvious, but may not be unrelated to the time of presentation in the 2 groups.

One rare cause of ureteric obstruction worth mentioning is the case of a 22-year-old female student who presented with features of right lower-third ureteric obstruction suspected to be a stricture on intravenous urogram (IVU). Exploration of the ureter revealed a 2 cm hard and cord-like segment of the ureter which was resected, after which end-to-end ureteroureterostomy was performed. Histology reported an aganglionic segment of the ureter. The patient did well after uretero-ureterostomy but presented with an obstructing renal pelvic stone on the contra-lateral side 18 months later. Attempts at stenting with a double-J stent failed and she is waiting for open pyelolithotomy.

The commonest presenting feature in our study was flank pain or colic which was present in all patients (94.6%) except two. These two exceptions were the 3-year-old girl with congenital PUJ obstruction and a 20-year-old male with congenital megaureter.

Our diagnostic armamentarium was limited to plain radiography, ultrasonography, intravenous urography and cystoscopy and ureteric catheterization for retrograde pyelography, with no facility for fluoroscopy. All patients had plain abdominal radiography (KUB), ultrasonography and intravenous urography. The IVU served both as a diagnostic tool and the only objective measure of renal function, particularly of the contralateral kidney, prior to surgery. Plain radiography (KUB) was diagnostic in 12 of 15 calculi (80%); it detected 11 renal pelvic stones and one ureteric stone, thus confirming the reported 80% - 90% sensitivity of plain X-rays in diagnosing urinary calculi⁸.

Ultrasonography revealed all 13 pelvic stones, but did not detect the two ureteric stones. Ultrasound diagnosis of ureteric stones is difficult and operator-dependent. A combination of IVU and retrograde pyelography was useful in the diagnosis of PUJ obstruction, ureteric stricture and ureteric calculi. The diagnosis was determined only at operation in 4 patients. These limitations underscore the value of flexible ureteroscopy in the management of upper urinary tract pathology^{2,4}.

Ureteric stent placement was considered necessary in 7 patients, either for temporary decompression of the obstructed upper tract or as a palliative measure. All attempts to place a ureteric stent in the absence of fluoroscopy and flexible ureteroscopy failed. One such case was a 7 months pregnant woman who presented with pain secondary to congenital PUJ obstruction in a solitary kidney. She was treated conservatively until she delivered after which an open pyeloplasty was done.

Definitive treatment consisted of open surgery in all patients who needed surgical intervention. Twelve patients had open pyelolithotomy. Six out of seven patients with congenital PUJ obstruction had open pyeloplasty. The only child in this group had a nephrectomy because of lack of function on IVU, gross calyceal dilatation and loss of cortical tissue found at operation. The second nephrectomy was carried out in a young man with unilateral congenital megaureter. The ipsilateral kidney showed no function on IVU and at operation was found to contain pus. Three patients with ureteric strictures were subjected to resection and ureteroureterostomy while the fourth had a ureteroneocystostomy. Two of the three cases of vesical schistosomiasis had ureteroneocystostomy in addition to anti-schistosomal treatment, while the third had only anti-schistosomal therapy and has remained symptom-free. The 2 patients with ureteric calculi were offered open ureterolithotomy. Although the literature is full of modern treatment modalities for the management of upper tract obstructive lesions^{2,3,9-15}, these facilities are not available in most centers in the developing world.

Internal stents (double-J stents) were placed intraoperatively in 15 patients. In total, 22 stents were placed in 27 stentable procedures. Though the use of internal stents and nephrostomy tubes remains controversial, the provision of external drainage is generally accepted as mandatory for the prevention of urinoma formation with possible disruption of the suture line, scarring and sepsis¹. All 29 open procedures had

passive drains brought out through different stab incisions.

Four complications (13.8%) were encountered in the 29 surgical interventions. Two patients had retrograde migration of the vesical end of double-J stents. After eight weeks of expectant management, one of the stents descended into the bladder and was removed cystoscopically. In the second patient, the stent was extracted through an open pyelotomy; an unnecessary procedure, if a flexible ureteroscope had been available. The other two complications were wound infection which was managed with antibiotic administration, and prolonged urine leakage which resolved on conservative management. There was no mortality from benign obstruction of the upper tract or from the operations. The two patients who had palliative nephrostomy tubes for malignant obstruction secondary to cervical and bladder cancers died within one week due to the advanced nature of the primary pathology.

We conclude that careful clinical evaluation and the use and correct interpretation of simple radiologic investigations are essential in diagnosis and planning treatment for upper tract obstruction. In the absence of modern equipment, open surgery is relatively safe in selected patients and remains the main stay of treatment for upper urinary tract obstruction in resource-poor settings.

REFERENCES

1. Strem SB, Franke JJ, Smith JA Jr. Management of upper urinary tract obstruction. In: Walsh PC, Retik AB, Vaughan ED, Wein AJ, Kavoussi LR, Novick AC, et al, editors. *Campbell's Urology*. 8th ed. Philadelphia: WB Saunders;chapt. 13 (e-version), 2003.
2. Sadek M, Abdelaal A, Maged W, El Zayat T. Role of flexible ureterorenoscopy in the management of lateralizing essential haematuria. *Afr.J.Urol.* 2004;10(1):45-9.
3. Abdel Latif AM, Abdel Moniem A, El-Haggagy A, El-Tary A. Extracorporeal shock wave lithotripsy versus lasertripsy for the treatment of upper ureteric calculi. *Afr.J.Urol.* 2004;10(1):15-21.
4. Mbibu NH, Mourad M, Khalaf I. Injuries encountered during rigid ureteroscopy in training centers. *Afr. J.Urol.* 2005;11(4):275-81.

5. Andankar MG, Maheshwari PN, Shah HN, Trivedi NN, Kausik VB, Jain R. Bilateral single session ureteroscopy for ureteral calculi: Is it safe and effective? *Afr.J.Urol.* 2003;9(3):129-32.
6. Jacobs JA, Berger BW, Goldman SM, Robbins MA, Young JD, Jr. Ureteropelvic obstruction in adults with previously normal pyelograms: A report of 5 cases. *J.Urol.* 1979; Feb;121(2):242-4.
7. Aghaji AE. Ureteroneocystostomy in the management of lower ureteric obstruction by carcinoma of the prostate. *Nigerian Journal of Surgical Sciences* 1998, 5:55-59.
8. Pahira JJ, Razack AA. Nephrolithiasis. In: Hanno PM, Malkowicz SB, Wein AJ, editors. *Clinical Manual of Urology*. 3rd ed. New York: McGraw-Hill Professional; 2001. p. 231-52.
9. Gaur DD, Trivedi S, Prabhudesai MR, Madhusudhana HR, Gopichand M. Laparoscopic ureterolithotomy: Technical considerations and long-term follow-up. *BJU Int.* 2002; Mar;89(4):339-43.
10. Davis D. Intubated ureterotomy: A new operation for ureteral and ureteropelvic stricture. *Surg.Gynecol. Obstet.* 1943;76:513-23.
11. Chen RN, Moore RG, Kavoussi LR. Laparoscopic pyeloplasty. *J.Endourol.* 1996; Apr;10(2):159-61.
12. Chertin B, Rolle U, Farkas A, Puri P. Does delaying pyeloplasty affect renal function in children with a prenatal diagnosis of pelvi-ureteric junction obstruction? *BJU Int.* 2002; Jul;90(1):72-5.
13. Hellawell GO, Cowan NC, Holt SJ, Mutch SJ. A radiation perspective for treating loin pain in pregnancy by double-pigtail stents. *BJU Int.* 2002; Dec;90(9):801-8.
14. Nishino S, Goya N, Ishikawa N, Tomizawa Y, Toma H. An experimental study of self-expanding ureteric metallic stents: Macroscopic and microscopic changes in the canine ureter. *BJU Int.* 2002; Nov;90(7):730-5.
15. Hofmann R, Olbert P, Weber J, Wille S, Varga Z. Clinical experience with a new ultrasonic and LithoClast combination for percutaneous litholapaxy. *BJU Int.* 2002; Jul;90(1):16-9.

RESUME

La prise en charge de l'obstruction du haut appareil urinaire dans les milieux pauvres en ressources

Objectif: La prise en charge de l'obstruction du haut appareil urinaire en l'absence des équipements modernes présente un défi important de la pratique urologique dans les pays en voie de développement. Le but de cette étude était de décrire l'étiologie, la présentation clinique et le traitement de l'obstruction du haut appareil urinaire à l'hôpital universitaire de Jos, Nigéria .

Patients et méthodes: C'est une analyse prospective de 37 patients consécutifs (18 mâles, 19 femmes) présentant un âge moyen de 35.5 ans (3-55 ans) qui ont été contrôlés pour obstruction du haut appareil urinaire à notre service entre janvier 2001 et décembre 2005. Deux ont présenté une deuxième obstruction après qu'ils aient été traités pour la première, de sorte qu'en fait nous avons traité 39 cas. La douleur du flanc était la présentation clinique la plus commune, étant présente chez 35 patients (94.6%). Les autres manifestations cliniques étaient : hématurie chez 12 (32.4%), un gros rein chez 5 (13.5%), insuffisance rénale chez 4 (10.8%) et hypertension chez 3 (8.1%) patients. La démarche diagnostique est faite de ASP, échographie abdominale, urographie intraveineuse et pyélographie rétrograde. Les lithiases urétérales pelviennes étaient la principale cause de l'obstruction (13 patients ; 35.1%), alors que l'obstruction congénitale de la jonction pyélo-urétérale (PUJ) était diagnostiquée chez 7 (18.9%) et le rétrécissement urétéral et schistosomiase vésicale chez 4 (10.8%) et 3 (8.1%) patients, respectivement. Deux patients ont eu une obstruction bilatérale de deux causes différentes.

Résultats: 29 cures chirurgicales à ciel ouvert ont été réalisées : pyélolithotomie (n=12), pyéloplastie (n=6), urétérourétostomie (n=4), urétéronéocystostomie (n=3), néphrectomie (n=2) et urétérolithotomie (n=2). Huit patients ont été traités d'une façon non chirurgicale. Deux patients attendent le traitement chirurgical définitif. Un total de 4 (13.8%) complications sur 29 cures effectives ont été notées : deux cas de migration de sondes urétérales en double-J, un cas de fuite prolongée d'urine et un cas d'infection.

Conclusion: L'obstruction du haut appareil urinaire n'est pas rare dans notre environnement. En l'absence des équipements modernes, la chirurgie ouverte demeure notre option principale de traitement; et c'est relativement sûr.

Editorial Comment:

The authors are to be congratulated on their successful management (by open surgery) of a variety of causes of upper urinary tract obstruction.

Two important forms of treatment in the management of acute upper urinary tract obstruction were not available to the authors:

1. fluoroscopy in theatre – facilitating the placement of a DJ stent (however a ureteric catheter can be used to bypass the obstruction, confirmed by a "post hydronephrotic drip").
2. facilities for percutaneous nephrostomy (an interventional Radiologist)

In my view, flexible ureteroscopy has a small place in the management of upper urinary tract obstruction (except for laser treatment of stones).

An uncomplicated pyelolithotomy, pyeloplasty or ureterolithotomy needs only a drain, not a DJ stent (2 patients in this series had stent migration).

I think this is an important article, as many areas of Africa lack first world facilities.

Dr. Richard Barnes
Groote Schuur Hospital, University of Cape Town, South Africa

Corresponding Author:

Dr. V.M. Ramyil
Urology Unit, Department of Surgery
Jos University Teaching Hospital (JUTH)
PMB 2076
Jos
Nigeria

e-mail: vramyil@yahoo.com