

CLINICAL PRESENTATION AND OUTCOME OF MANAGEMENT OF PATIENTS WITH SYMPTOMATIC SPINAL METASTASIS FROM PROSTATE CANCER: A FIVE-YEAR EXPERIENCE

L.I. OKEKE, S.O. IKUEROWO, A.A. POPOOLA, O.B. SHITTU AND E.O. OLAPADE-OLAOPA,
Urology Division, Department of Surgery, College of Medicine,
University College Hospital, Ibadan, Nigeria

Objective: The aim of this study was to describe the clinical presentation and outcome of management of the patients who presented to our division with symptomatic spinal metastasis from carcinoma of the prostate.

Patients and Methods: Thirty-two patients (mean age: 68 ± 10 years) with symptomatic spinal metastasis from carcinoma of the prostate gland were retrospectively studied over a 5-year period. Data on their clinical and radiological presentation, treatment and outcome of treatment were retrieved from their clinical records and analyzed.

Results: Lower back pain, lower limb weakness, significant lower urinary tract symptoms and anemia were the commonest clinical presenting symptoms. Pure osteo-

blastic bone lesions involving mainly the lumbar spinal vertebrae were seen in 75% of the patients. The cervical vertebrae were not involved. All the patients were offered bilateral orchidectomy. Sixteen (50%) became ambulant while 2 (6%) showed no significant improvement of their neurological status and 14 (44%) died within 6 months of presentation.

Conclusions: The neurological status prior to treatment is the major determinant influencing outcome. Spinal metastasis should be considered in the differential diagnosis of a new-onset lower back pain in men above the age of 50.

Key words: prostate cancer, spinal metastasis, management.

INTRODUCTION

Prostate cancer is a major factor in the health of the aging male population both in the developed world and developing countries^{1,2}. It is the most commonly diagnosed cancer among Nigerian males² and one of the most common causes of male cancer-related deaths. The skeleton (axial and appendicular) is the most common location for hematogenous metastatic spread from prostate cancer and the spine is the most common location for skeletal spread³. The symptoms of metastatic spread to the spine vary widely with many patients being relatively asymptomatic while others at the end of the spectrum develop paraplegia or quadriplegia from spinal cord or neural compression⁴.

A patient with prostate cancer who is paralyzed from metastatic spinal cord or neural compression will be continually dependent on caregivers and have frequent morbidities from bladder catheterization, decubitus ulcers and infection leading to a poor quality of life. The goals of treatment therefore are prevention of spinal cord compression, early detection and prompt treatment of spinal cord compression before paralysis becomes complete and further supportive treatment to improve the patient's quality of life⁵. Since the clinical presentation of this condition and the outcome after treatment in our environment have not yet been described, the present study was carried to retrospectively evaluate the patients with symptomatic spinal metastasis from prostate cancer presenting to our unit between 1997 and 2001.

Table 1: Clinical and Radiological Features of Symptomatic Spinal Metastasis from Prostate Cancer.

Clinical/radiological features	Number of patients	%
Back pain	26	81 %
Radicular pain	8	25 %
Lower limb weakness	20	63 %
Loss of sensation in lower limb	8	25 %
Bladder and bowel dysfunction	12	38 %
Lower urinary tract symptoms (LUTS)	18	56 %
Anemia	20	63 %
Renal insufficiency	10	31 %
Osteoblastic deposits	24	75 %
Osteolytic deposits	0	0 %
Mixed osteoblastic and osteolytic	6	19 %
No changes on X-ray	2	6 %

MATERIAL AND METHODS

In the course of a retrospective review of the case notes of all the patients admitted to our unit with a diagnosis of symptomatic spinal metastasis from prostate cancer between 1997 and 2001, we collected data on the patients' age, the clinical and radiological presentations, treatment and outcome of treatment and surgical out-patient follow-up visits. These data were analyzed using the SPSS 11.0 for Windows. Comparison of means was done using the Levene's statistical test with $p \leq 0.05$ considered significant.

RESULTS

In total, 41 patients with a diagnosis of symptomatic spinal metastasis from prostate cancer presented to our department during the study period. The case files of 32 patients (82%) were available for review. The other nine patients whose files could not be retrieved were excluded from the evaluation. The mean age at presentation was 68 ± 10 years.

As shown in Table 1, lower back pain was the most frequent presenting symptom occurring in 26 (81%) patients. In 8 (25%)

of these patients, the lower back pain was accompanied by radicular pain radiating to the lower limbs, suggestive of nerve root compression. Twenty (63%) patients presented with weakness of the lower limbs: 12 (38%) of them had paraparesis and 8 (25%) paraplegia defined as power of grade 0 in both lower limbs. None of the patients presented with weakness of the upper limbs. An associated complete loss of sensation in the lower limbs was documented in 8 (25%) patients, namely those with paraplegia. Significant lower urinary tract symptoms (LUTS) were a common feature and occurred in 18 (56%) patients. Autonomic dysfunction of the bladder and the bowel presenting as chronic urinary retention from atonic bladder and constipation with a lax anal sphincter and loss of bulbocavernous reflex was found in 12 (38%) patients. Anemia was encountered in 20 (63%) patients. Twelve (38%) patients had a packed cell volume less than 18% and required blood transfusion. Renal insufficiency, defined as elevated serum creatinine and urea, was present in 10 (31%) patients, among them 8 with paraplegia.

All the patients were subjected to X-ray of the lumbosacral spine as well as the thoracic spine when there were symptoms

Table 2: Outcome after bilateral orchidectomy for symptomatic spinal metastasis from prostate cancer.

Degree of lower limb weakness	Post-Orchidectomy Status							
	Dead n (%)		Ambulant n (%)		Non-ambulant n (%)		Total	
	n	%	n	%	n	%	n	%
No weakness	8	67 %	4	33 %	0	0 %	12	38 %
Paraparesis	2	17 %	10	83 %	0	0 %	12	38 %
Paraplegia	4	50 %	2	25 %	2	25 %	8	24 %
Total (%)	14	44 %	16	50 %	2	6 %	32	100 %

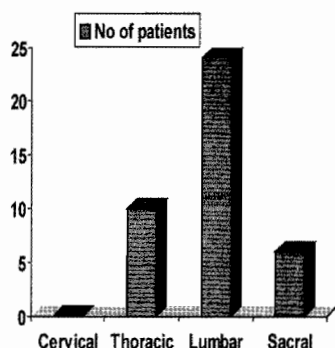


Fig. 1: Frequency of metastasis at the various vertebral levels

suggesting thoracic spine involvement. None of the patients had symptoms involving the cervical spine and, hence, no cervical spine X-ray was done. Of the 32 patients reviewed, 24 (75%) had pure osteoblastic secondaries involving the spine, while 6 (19%) had mixed osteoblastic and osteolytic deposits in the spine. No pure osteolytic deposits were found in any of the patients, and in 2 (6%) patients no changes in the spine could be seen on X-ray. The lumbar vertebrae were the most frequently involved site (24 patients, 75%). Metastases in the thoracic and sacral vertebrae were found in 10 (31%) and 6 (19%) patients, respectively (Fig. 1).

CT and MRI which are the gold-standard imaging modalities in the developed countries were not performed in our patients due to their high cost.

All the patients with symptomatic spinal metastasis from prostate cancer were offered bilateral simple orchidectomy. Eight patients had adjuvant radiotherapy to the spine for the purpose of pain palliation. Otherwise, the pain was treated with non-steroidal anti-inflammatory agents and opiates. All the patients with lower limb motor paralysis were also offered limb physiotherapy following orchidectomy. The 10 (31%) patients with renal insufficiency were placed on continuous catheterization, and their serum creatinine levels returned to normal. Follow-up at the surgical outpatient clinic consisted of an assessment of the patients' clinical condition and their biochemical status: serum acid phosphatase in the pre PSA era and serum PSA later in the review period.

Sixteen patients (50%) became ambulant, 2 (6%) showed no significant improvement of their neurological status and 14 (44%) died within six months of presentation. The causes of death were extensive pulmonary metastasis, severe intractable anemia, cerebro-vascular accident and pulmonary embolism. The patients that were still alive at the end of the study period continued to be followed up at the surgical outpatient clinic.

Table 2 illustrates the neurological outcome following orchidectomy. Owing to the fact that patients with paraparesis presented in an earlier stage of disease progression, the chance of recovery of neurological func-

tion after orchidectomy was significantly higher among patients with paraparesis (10 out of 12 patients: 83%) compared to those with paraplegia (2 out of 8 patients: 25%). The duration of back pain before hormonal therapy was shorter in the patients who were alive at six months after commencement of hormonal therapy (mean: 12±8.3 weeks) compared to the patients who died (mean: 16.6±9.0 weeks), but this was not statistically significant ($p=0.48$, Levene's test).

DISCUSSION

The most frequent site of systemic metastasis from prostate cancer is the skeleton with the spine being involved most frequently⁴. Spinal cord compression occurs in approximately 7% of men with prostate cancer^{4,5}. Back pain is almost universal in men with symptomatic metastasis from prostate cancer and it often heralds the diagnosis of spinal cord or neural compression⁶. In addition to classical hematogenous tumor spread via the vena cava to the systemic circulation, several lines of evidence suggest the existence of a backward metastatic pathway through Batson's venous plexus from the prostate to the spine⁷. This metastatic route may account for up to 15-30% of metastatic spread from prostate cancer⁸. In our study, the lumbar vertebrae were the most commonly involved site followed by the thoracic and then sacral vertebrae. We had no case of cervical metastasis. This is consistent with the fact that there is a subsequent metastatic spread along spinal veins after an initial lumbar metastasis³. Some earlier studies identified the thoracic vertebrae as the most common site of metastatic spread from prostate cancer^{5,9}. More recent studies, however, report that the lumbar vertebrae are the most frequent site of spinal metastasis from prostate cancer³ and this is consistent with the finding in our study. The reason for this observed change of pattern has not yet been clarified.

The neurological status prior to treatment is the major determinant influencing outcome^{4,6}. Recovery of neurological function is more likely in those patients with paraparesis when compared with the patients who had

paraplegia⁴ owing to the fact that paraparesis occurs in an earlier stage of the disease. In addition, the 6 month survival rate among the patients with paraparesis was better than among the patients with paraplegia (83% versus 50%).

Because neurological complications of metastatic prostate cancer require prompt treatment, early recognition is important. Spinal metastasis should be considered in the differential diagnosis of a new-onset lower back pain in men above the age of 50 before the appearance of symptoms of spinal cord or cauda equina compression. Treatment options include hormonal therapy, inhibitors of bone metabolism, glucocorticoid therapy, radiotherapy, halo-vest, surgical debridement, decompression and stabilization, and appropriate pain management and support. Our patients presented very late and were generally not suitable for any heroic surgical measures. In view of our patients' very advanced disease, we also refrained from the administration of high-dose intravenous dexamethasone which usually would have a place in patients with clinical signs and symptoms or MR findings suggesting cord compression. One must not lose sight of the fact that the goal is palliation and that ultimate demise is unavoidable in patients with metastatic prostate cancer¹⁰.

REFERENCES

1. Osegbe, D. N. Prostate cancer in Nigerians: facts and nonfacts. *J.Urol.* 1997 Apr; 157(4)1340-3.
2. Ogunbiyi, J. O. and Shittu, O. B. Increased incidence of prostate cancer in Nigerians. *J.Natl. Med.Assoc.* 1999 Mar; 91(3)159-64.
3. Bubendorf, L., Schopfer, A. and Wagner, U., et al. Metastatic patterns of prostate cancer: an autopsy study of 1,589 patients. *Hum.Pathol.* 2000 May; 31(5)578-83.
4. Osborn, J. L., Getzenberg, R. H. and Trump, D. L. Spinal cord compression in prostate cancer. *J.Neurooncol.* 1995; 23(2)135-47.
5. Kuban, D. A., el Mahdi, A. M., Sigfred, S. V., Schellhammer, P. F. and Babb, T. J. Characteristics of spinal cord compression in adenocarcinoma of prostate. *Urology.* 1986 Nov; 28(5)364-9.
6. Cereceda, L. E., Flechon, A. and Droz, J. P. Management of vertebral metastases in prostate

- cancer: a retrospective analysis in 119 patients. Clin.Prostate Cancer.2003 Jun;2(1)34-40.
7. Suzuki, T., Shimizu, T., Kurokawa, K., Jimbo, H., Sato, J. and Yamanaka, H. Pattern of prostate cancer metastasis to the vertebral column. Prostate.1994 Sep;25(3)141-6.
 8. Benjamin, R. Neurologic complications of prostate cancer. Am.Fam.Physician.2002 May 1;65(9)1834-40.
 9. Liskow, A., Chang, C. H., DeSanctis, P., Benson, M., Fetell, M. and Housepian, E. Epidural cord compression in association with genitourinary neoplasms. Cancer.1986 Aug 15;58(4)949-54.
 10. Bridwell, K. H. Treatment of metastatic prostate cancer of the spine. Urol.Clin.North.Am.1991 Feb;18(1)153-9.

RESUME

PRESENTATION ET RESULTATS CLINIQUES DE LA PRISE EN CHARGE DES PATIENTS AVEC METASTASES RACHIDIENNES SYMPTOMATIQUES DU CANCER DE PROSTATE : UNE EXPERIENCE DE CINQ ANS

Objectif : Le but de cette étude était de décrire la présentation et les résultats cliniques de la prise en charge des patients qui se sont présentés à notre division avec métastases rachidiennes symptomatiques du carcinome prostatique. **Patients et méthodes :** Trente deux patients (âge moyen : 68 ± 10 ans) avec métastases rachidiennes symptomatiques du carcinome de la glande prostatique ont été rétrospectivement étudiés sur une période de cinq ans. Leur présentation, traitement et résultats cliniques et radiologiques de traitement ont été recherchés et analysés. **Résultats :** La lombalgie, la faiblesse de membre inférieure, les symptômes du bas appareil urinaire significatifs et l'anémie étaient les symptômes de la présentation cliniques les plus communs. Des lésions osteoblastiques pures impliquant principalement les vertèbres lombaires ont été vues chez 75% des patients. Les vertèbres cervicales n'étaient pas impliquées. Tous les patients ont subi une orchidectomie bilatérale. Seize (50%) ont reçu un traitement en ambulatoire tandis que 2 (6%) ne montraient aucune amélioration significative de leur manifestations neurologiques et 14 (44%) sont morts dans les 6 mois de la présentation. **Conclusions :** Les manifestations neurologiques avant le traitement sont les principaux facteurs déterminants pour les résultats. La métastase rachidienne devrait être considérée dans le diagnostic différentiel d'une lombalgie de novo à son début chez les hommes au-dessus de l'âge de 50.

Editorial Comment:

This paper is well-written. My only and main concern relates to not treating some of the study patients with high-dose intravenous steroid. The authors indicate in their discussion that "in view of our patients' very advanced disease, we also refrained from the administration of high-dose intravenous dexamethasone which usually would have a place in patients with clinical signs and symptoms or MR findings suggesting cord compression". One would argue that the 25% of patients with radicular pain, 63% with hemiparesis, 12 with paraparesis and 8 with paraplegia are patients with clear indication of cord compression who would essentially have benefited from high-dose steroids.

Dr. Ofer Yossepowitch
Memorial Sloane-Kettering Cancer Center,
New York, USA

Corresponding Author:

Dr. L. I. Okeke, FICS , Urology Division,
Department of Surgery, College of Medicine/University College Hospital
PMB 5116, Ibadan, Nigeria.
Email: liokeke@yahoo.com