

## VALUE OF TRANSRECTAL ULTRASONOGRAPHY IN PATIENTS PRESENTING WITH HEMOSPERMIA

A. MESHREF, A. ABOU-ELELA, A. ZIADA AND A. EHSAN

Department of Urology, Kasr El-Aini Faculty of Medicine, Cairo University, Cairo, Egypt

**Objective:** The aim of this study is to evaluate the transrectal ultrasound (TRUS) findings in patients presenting with hemospermia.

**Patients and Methods:** We retrospectively reviewed the TRUS findings in 41 patients presenting with hemospermia. The patients' age ranged from 19 to 70 years (mean age  $46.6 \pm 14$  years).

**Results:** Due to an overlap of TRUS findings, relevant abnormalities of the prostate or seminal tract were found in 34 patients (83%). Abnormalities of the prostate, the ejaculatory duct and the seminal vesicles were found in 10 (24.4%), 17 (41.5%) and 16 (39%) patients, respectively. However, when considering the TRUS findings of the prostate less relevant in these cases and the seminal tract abnormalities highly relevant, TRUS would be of value in 25 patients (61%) with seminal tract abnormalities. Prostate abnormalities included mottled hyperechoic appearance

suggestive of prostatitis in 5 patients, prostatic calculi in 4 and multiple cysts in 1 case. Ejaculatory duct abnormalities included calcification with no definite obstruction in 9 patients, midline cyst in 4, unilateral dilated ejaculatory duct in 3, and bilateral dilatation in one patient. Seminal vesicle abnormalities included bilateral cystic dilatation in 7 patients, unilateral dilatation in 5 and calcification, calcification with dilatation, infection with tenderness and seminal vesicle adenocarcinoma in one patient each.

**Conclusions:** TRUS is a useful non-invasive and cost-effective tool to investigate the causes of hemospermia, which in our study helped in providing patient assurance by finding relevant findings in 83% of the cases. Positive seminal tract findings were found in 61% of the cases.

**Key words:** hemospermia, TRUS, prostate, seminal vesicles.

### INTRODUCTION

Even though physicians regard hemospermia or hematospermia as of little clinical significance, blood in the ejaculate causes great concern and anxiety for many men. Hemospermia is not an uncommon condition. It is benign in most instances, but its exact prevalence remains unknown because it usually passes unnoticed. It is often overlooked because the symptom is usually intermittent and self-limited<sup>1</sup>.

Hemospermia in urological practice poses a diagnostic and therapeutic challenge

associated with various genital and seminal tract abnormalities. The etiology has been reported to be idiopathic in as many as 70% of the cases<sup>2</sup>. In a review of multiple series, 46% of patients had an idiopathic etiology probably reflecting incomplete evaluation. Infections or inflammatory disorders accounted for 39% of cases, malignancies and trauma for 2% each and a variety of disorders and pathologic conditions in the remaining 11% of cases<sup>3,4</sup>.

Lesions of the prostate and seminal tract account for a large number of cases of hemo-

spermia and include polyps, vascular lesions, calculi, inflammatory disorders and malignancies. Prostate cancer is rarely associated with hemospermia. However hemospermia may occur as a complication associated with TRUS biopsies in 10-40% of patients<sup>5</sup>. Congenital and acquired seminal vesicular cysts resulting from infectious processes have been reported to cause hemospermia. Malignancies of the seminal vesicles are a rare cause of hemospermia. Infections including tuberculosis, cytomegalovirus and schistosomiasis have all been reported as causes. Other causes include urethritis and urethral stricture as well as systemic causes including hypertension, liver disease and bleeding disorders<sup>5</sup>.

In the past vaso-vesiculography was extensively used to visualize the seminal tract until transrectal ultrasonography (TRUS) replaced vasography as the premier noninvasive diagnostic modality<sup>6</sup>. The advent of TRUS and later on magnetic resonance imaging (MRI) provided the opportunity to visualize the prostate, seminal vesicles and vasa deferentia. Both imaging modalities therefore play an important role in the detection of anatomic lesions. MRI shows an enhanced resolution of prostatic and seminal vesicular anatomy using an endorectal coil. It may play a valuable role in the evaluation of patients with ejaculatory dysfunction, including infertility, hemospermia and painful ejaculation<sup>7,8</sup>.

Traditionally watchful waiting or reassurance has been widely practised but the patient and physician were not certain of the exact nature of the disease.

#### PATIENTS AND METHODS

In this retrospective review of our records of patients with hemospermia, we evaluated the prostate and seminal tract in 41 patients with a mean age of 46.6 ± 14 years (range: 19 - 70 years). All patients complained of hemospermia. Additional symptoms in the form of dysuria, left inguinal pain, mild lower uri-

nary tract obstructive symptoms, secondary azoospermia and primary infertility with low semen volume were reported by one patient each.

All patients were referred to our centre for TRUS examination only. In all cases, the treating urologist continued the patient's treatment. Therefore no other imaging or laboratory findings or details on the treatment of the patients were available for this study.

Each of the 41 subjects provided a urological history and underwent physical examination. TRUS findings considered abnormal were recorded. Initial diagnostic TRUS was performed with the patient in the lateral decubitus position using a high resolution 6.5 - 7.5 MHz biplanar or multiplanar transrectal probe (Siemens Versa Pro or Bruel & Kjaer or Hitachi EUB 405 machines). The prostatic echopattern and size, the width and texture of the seminal vesicles and the diameter of the ejaculatory duct were assessed.

Prostate specific antigen (PSA) was elevated in 2 patients (6.4 ng/ml and 6.9 ng/ml). The first patient was 60 years old with a prostate measuring 105 cc whole gland volume and 70 cc transition zone volume. The second patient was 62 years old with a prostate measuring 81 cc whole gland volume and 53 cc transition zone volume. Both had an enlarged middle lobe. The second patient had a calcification in the prostate. In both patients, the further work up did not reveal any malignancy.

#### RESULTS

Transrectal ultrasound revealed abnormalities in 34 of the 41 patients (83%). Abnormalities were found in the prostate in 10 (24.4%) (Table 1, Fig. 1), in the ejaculatory duct in 17 (41.5%) (Table 2, Fig. 2) and in the seminal vesicles in 16 patients (38.9%) (Table 3, Fig. 3).

Due to an overlap of the TRUS findings, relevant abnormalities of the prostate or

Table 1: Relevant Abnormalities of the Prostate Detected by TRUS

TRUS Abnormalities of the Prostate	No of Patients	%
Mottled hyperechoic appearance suggestive of prostatitis	5	12.2%
Prostatic calculi	4	9.8%
Multiple cysts replacing the whole prostate	1	2.4%
<b>Total</b>	<b>10</b>	<b>24.4%</b>

Table 2: Ejaculatory Duct Abnormalities Detected by TRUS

TRUS Abnormalities of the Ejaculatory Ducts	No of Patients	%
Calcification with no definite obstruction	9	22.0%
Midline Cyst	4	9.8%
Unilateral dilated ejaculatory duct	3	7.3%
Bilateral dilatation of ejaculatory ducts	1	2.4%
<b>Total</b>	<b>17</b>	<b>41.5%</b>

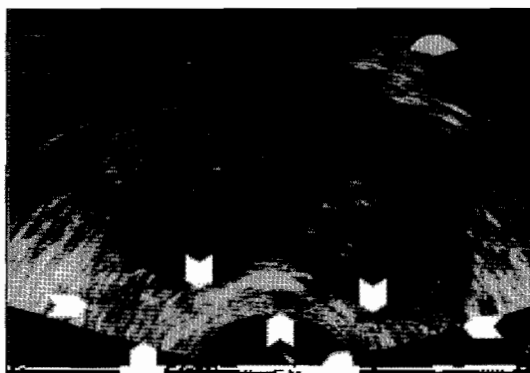

Fig. 1A: Mottled hyperechoic appearance of peripheral zone suggestive of prostatitis (arrows).



Fig. 1B: Excessive calcification in the prostate (transverse section).

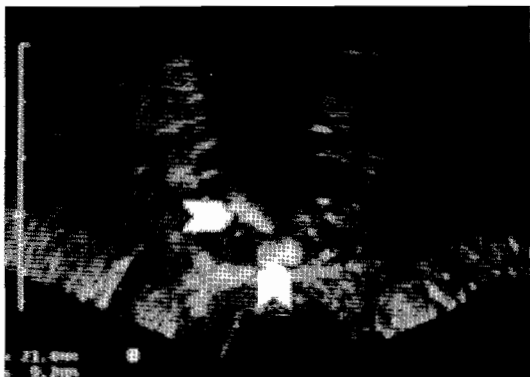


Fig. 1C: Two areas of excessive calcification in the prostate (transverse sec.).

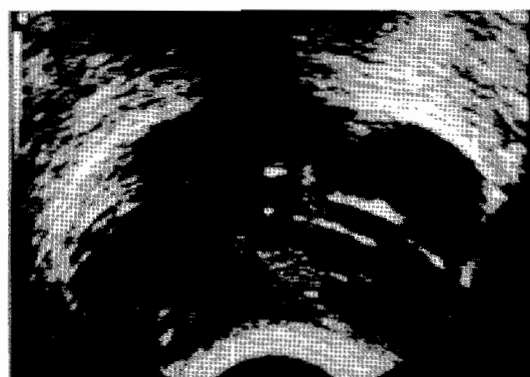

Fig. 1D: Multiple cysts replacing the whole prostate.

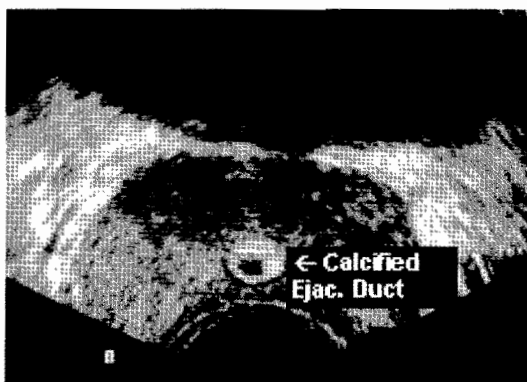


Fig. 2A: Transverse section showing calcified ejaculatory duct.

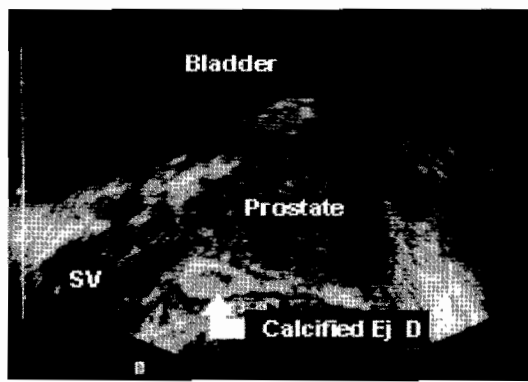


Fig. 2B: Longitudinal section of same case as in Fig. 2A showing calcified ejaculatory duct.

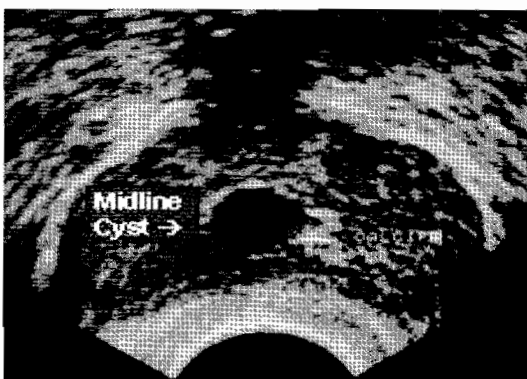


Fig. 2C: Transverse section showing midline cyst.

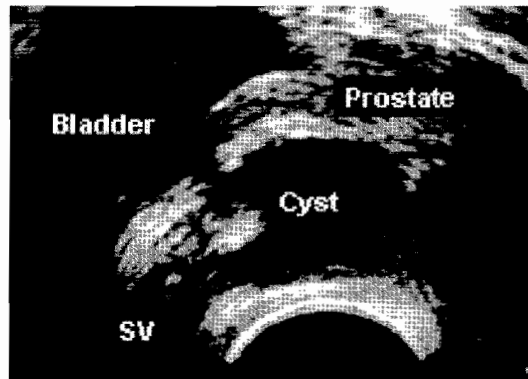


Fig. 2D: Longitudinal section of the same case as in Fig. 2C showing midline cyst.

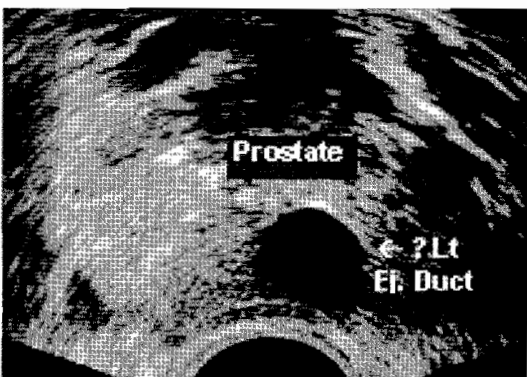


Fig. 2E: Transverse section showing dilated left ejaculatory duct.

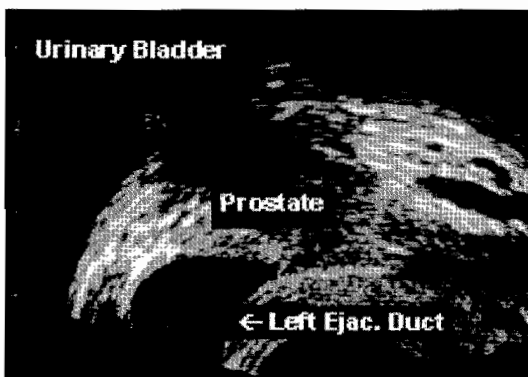


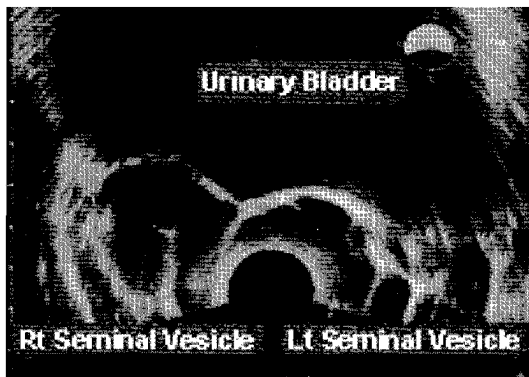
Fig. 2F: Longitudinal section of the same case as in Fig. 2E showing dilated left ejaculatory duct.

**VALUE OF TRANSRECTAL ULTRASONOGRAPHY IN PATIENTS PRESENTING WITH HEMOSPERMIA**

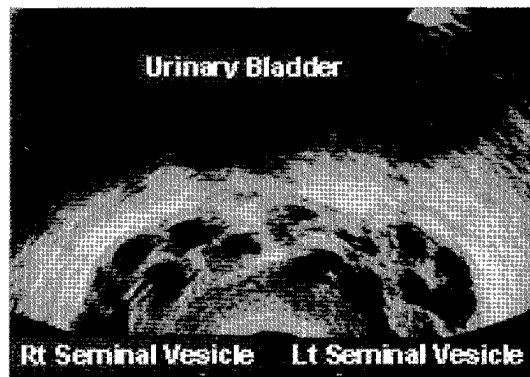
**Table 3: Seminal Vesicle Abnormalities Detected by TRUS**

TRUS Abnormalities of the Seminal Vesicles	No of Patients	%
Bilateral cystic dilatation	7	17.1%
Unilateral cystic dilatation	5	12.2%
Calcified seminal vesicles (bilharzial)*	1	2.4%
Calcified and dilated seminal vesicles	1	2.4%
Infection with tenderness	1	2.4%
Adenocarcinoma of the seminal vesicles**	1	2.4%
<b>Total</b>	<b>16</b>	<b>38.9%</b>

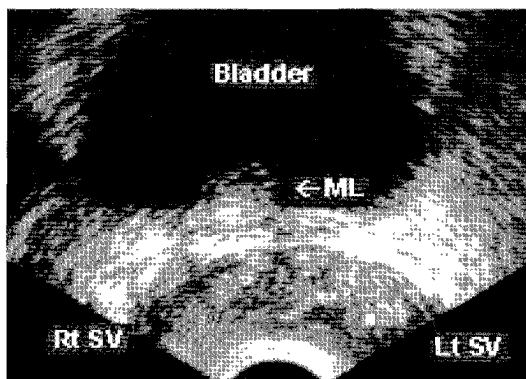
\* proven by biopsy



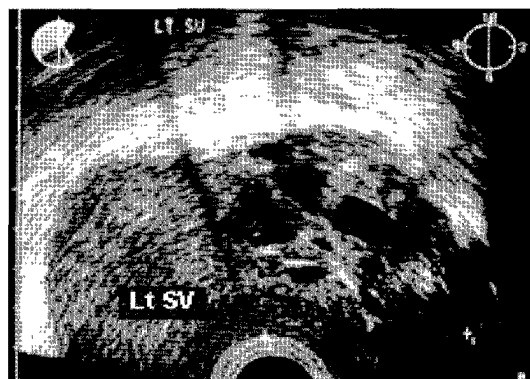
**Fig. 3A:** Cystic dilatation of both seminal vesicles



**Fig. 3B:** Cystic dilatation and calcification of both seminal vesicles



**Fig. 3C:** Calcification of both seminal vesicles (bilharzial as proven by biopsy)



**Fig. 3D:** Left seminal vesicle adenocarcinoma (proven by biopsy)

seminal tract were found in 34 patients (83%). A breakdown of the abnormalities showed prostate abnormalities in 10 (24.4%), ejaculatory duct abnormalities in 17 (41.5%) and seminal vesicle abnormalities in 16 patients (38.9%).

However, when considering the TRUS findings of the prostate less relevant in these cases and only the seminal tract abnormalities as highly relevant, TRUS was of value in 25 patients (61%) with seminal tract abnormalities.

### DISCUSSION

The primary goal of the urologist is to alleviate the related anxiety since hemospermia is rarely associated with any significant abnormality, especially in younger patients. Chronic hemospermia probably warrants a more aggressive intervention to identify an etiologic factor even though there is little to support this statement. In younger patients, a congenital origin including cysts should be suspected even though symptoms do not occur earlier in life, probably because the seminal tract and prostate grow after puberty, and so symptoms are evident only after the patient is able to ejaculate<sup>9</sup>. In the middle aged group of patients, obstruction may be increased due to prostatic enlargement, as in benign prostatic hyperplasia which carries greater susceptibility to obstruction and inflammation resulting in hemospermia. However, we agree with other authors that inflammation is not typically diagnosed with TRUS, without histologic sample<sup>1</sup>. Genital duct obstruction is also a potentially surgically curable cause of male infertility. The treatment is directed towards the diagnostic findings, whether antibiotics for urogenital infections, fulguration or transurethral resection of the prostate or urethral varices or aspiration of cysts. General disorders including bleeding diatheses should be treated appropriately<sup>5</sup>.

Our study findings are consistent with most other series in the literature. Lu and associates found abnormalities such as ejaculatory duct cysts, ejaculatory duct calculi, Mullerian duct cysts, asymmetric seminal vesicle dilatation, preprostatic vein engorgement and prostatic enlargement in 33 of 40 patients (83%)<sup>10</sup>,

while Amano and associates found abnormal findings including prostatic stones, benign prostatic hyperplasia, prostatitis, and dilatation and calcifications of the seminal vesicles in 34 of 46 patients (73.9%)<sup>11</sup>. Worischek and Parra found significant sonographic findings in 24 of 26 patients with hemospermia. These consisted of dilated seminal vesicles in 8, ejaculatory duct cysts in 4, ejaculatory or seminal vesicle calcifications in 4, ejaculatory duct and seminal vesicle dilatation in 4, seminal vesicle cysts with ipsilateral renal agenesis and absence of the vas in 2, and an intraprostatic Mullerian duct remnant in 2 cases. None of the patients subjected to a biopsy was found to have malignancy.<sup>12</sup> In the largest report to our knowledge, 85 patients with hemospermia were examined. Blood tests and sperm culture demonstrated bacterial inflammation in 48 patients (56%). TRUS revealed peri-urethral and prostatic calcifications in 40 (47%), prostatic inflammation in progress or its outcome in 21 (24.70%), ectasia and seminal vesicle inflammation in 10 (11.76%) and a prostatic tumor in 3 patients (3.52%). None of the patients had cysts, stones or tumors in the seminal vesicles. In 11 patients (12.94%) no specific cause of hemospermia was detected, even though 4 of these patients (4.70%) had received anticoagulants for former heart ischemia. Benign prostatic hypertrophy was found in 44 patients (51.76%) but this was not considered a possible cause of hemospermia because of the high frequency of this condition in the male population<sup>13</sup>.

Routine urological evaluation, including digital rectal examination is usually insufficient to search for relevant findings in cases of hemospermia, and so transrectal ultrasonography is performed<sup>6</sup>. Due to its invasiveness, the use of vasography should be limited to cases with subtle abnormalities of the vas deferens, seminal vesicles and ejaculatory ducts. Vasography may be performed only as a preoperative evaluation before surgical exploration.

In our series, 83% of patients had abnormalities on TRUS. In a study on the value of MRI, TRUS revealed abnormalities in 15 of the 17 patients (88%) versus

100% with MRI. MRI with an endorectal surface coil is therefore considered a powerful modality for evaluating the seminal tracts of patients with hemospermia. It can be performed clinically when TRUS is not satisfactory<sup>14</sup>. However, the main limitation of the widespread use of MRI is the high current cost, especially compared to TRUS. Availability of the endorectal coil is another contributing factor. MRI should be limited only to cases of normal or equivocal findings on TRUS. Even then, the extra cost of MRI may not be warranted.

In conclusion, although usually a benign condition hemospermia merits a formal evaluation. Most of the causes are idiopathic or inflammatory as suggested by the mottled hyperechoic appearance or calcifications. TRUS provides an easy and efficient method of imaging a previously blind region to urologists. TRUS is a useful, noninvasive and cost-effective procedure to investigate the causes of hemospermia. Although in our series most of the lesions detected by TRUS did not require treatment, TRUS helped the referring physician to provide patient assurance, based on documented imaging.

Finally, urologists should consider performing a routine prostate cancer screening in all men of appropriate age (>50 years) since prostate cancer risk is elevated in men with hemospermia.

## REFERENCES

1. Leary FJ, Agullo JJ. Clinical significance of hematospermia. *Mayo Clin.Proc.* 1974 Nov;49(11):815-817
2. Ameer A, Touiti D, Jira H, el Alami M, Boumdin H, Abbar M. Les hemospermies: orientation diagnostique et therapeutique. A propos de sept cas. [Hemospermia: diagnosis and therapeutic aspects. Seven case reports]. *Ann.Urol.(Paris)* 2002 Jan;36(1):74-80.
3. Fletcher MS, Herzberg Z, Pryor JP. The aetiology and investigation of haemospermia. *Br.J.Urol.* 1981 Dec;53(6):669-671.
4. Ganabathi K, Chadwick D, Feneley RC, Gingell JC. Haemospermia. *Br.J.Urol.* 1992 Mar;69(3):225-230.
5. Mulhall JP, Albertsen PC. Hemospermia: diagnosis and management. *Urology* 1995 Oct;46(4):463-467.
6. Carter SS, Shinohara K, Lipshultz LI. Transrectal ultrasonography in disorders of the seminal vesicles and ejaculatory ducts. *Urol.Clin.North Am.* 1989 Nov;16(4):773-790.
7. Schnall MD, Lenkinski RE, Pollack HM, Imai Y, Kressel HY. Prostate: MR imaging with an endorectal surface coil. *Radiology* 1989 Aug;172(2):570-574
8. Schnall MD, Pollack HM, Van Arsdalen K, Kressel HY. The seminal tract in patients with ejaculatory dysfunction: MR imaging with an endorectal surface coil. *AJR Am.J.Roentgenol.* 1992 Aug;159(2):337-341.
9. Van Poppel H, Vereecken R, De Geeter P, Verduyn H. Hemospermia owing to utricular cyst: embryological summary and surgical review. *J.Urol.* 1983 Mar;129(3):608-609.
10. Lu CH, Chen WC, Wu HC, Lu HF. Transrectal ultrasonographic findings in patients with hemospermia. *Zhonghua Yi Xue Za Zhi (Taipei)* 2000 Jul;63(7):558-562.
11. Amano T, Kunimi K, Ohkawa M. Transrectal ultrasonography of the prostate and seminal vesicles with hemospermia. *Urol.Int.* 1994;53(3):139-142.
12. Worischek JH, Parra RO. Chronic hematospermia: assessment by transrectal ultrasound. *Urology* 1994 Apr;43(4):515-520.
13. Gattoni F, Avogadro A, Sacrini A, Blanc M, Pozzato C, Spagnoli I, et al. L'ecografia prostatica transrettale nello studio dell'emospermia. Valutazione di una casistica di 85 pazienti. [Transrectal prostatic echography in the study of hemospermia. An assessment of an 85-patient case load]. *Radiol. Med.(Torino)* 1996 Apr;91(4):424-428.
14. Cho IR, Lee MS, Rha KH, Hong SJ, Park SS, Kim MJ. Magnetic resonance imaging in hemospermia. *J.Urol.* 1997 Jan;157(1):258-262.

## RESUME

## APPORT DE L'ECHOGRAPHIE TRANSRECTALE CHEZ LES PATIENTS PRÉSENTANT UNE HEMOSPERMIE

**Objectif :** Le but de cette étude est d'évaluer les résultats de l'échographie transrectale (TRUS) chez les patients présentant une hemospermie. **Patients et méthodes :** Nous avons rétrospectivement révisé les résultats de TRUS chez 41 patients présentant une hemospermie. L'âge des patients s'étale de 19 à 70 ans (âge moyen :  $46.6 \pm 14$  ans). **Résultats :** En raison d'une superposition des résultats de la TRUS, des anomalies de la prostate ou de la région séminale ont été trouvées chez 34 patients (83%). Des anomalies de la prostate, le canal éjaculateur et les vésicules séminales ont été retrouvées chez 10 (24.4%), 17 (41.5%) et 16 patients (39%), respectivement. Cependant, vu que les résultats de TRUS de la prostate sont moins spécifiques dans ces cas et que les anomalies de la région séminale sont hautement spécifiques, TRUS serait d'un grand apport chez 25 patients (61%) présentant des anomalies de la région séminale. Les anomalies de la prostate ont inclus l'aspect hyperéchogénique suggestif de la prostatite chez 5 patients, de calcul prostatique chez 4 et des kystes multiples chez 1 cas. Les anomalies des canaux éjaculateurs ont inclus : la calcification avec l'obstruction chez 9 patients, kyste central chez 4, canal éjaculateur dilaté unilatéral chez 3, et dilatation bilatérale chez un patient. Les anomalies de vésicule séminale ont inclus la dilatation cystique bilatérale chez 7 patients, la dilatation unilatérale chez 5 et la calcification, la calcification avec dilatation, l'infection et l'adénocarcinome chez un patient chacune. **Conclusions :** TRUS est un outil non invasif et rentable utile pour étudier les causes de l'hemospermie, qui dans notre étude a aidé en fournissant l'information pour les patients en trouvant des résultats spécifiques chez 83% des patients. Des résultats positifs de la région séminale ont été trouvées chez 61% des cas.

Corresponding Author:  
Ashraf Abou Elela, M.D.  
1, Obour Buliding, App. 12  
Salah Salem St.  
Nasr City  
Cairo  
Egypt

ashrafaboelela@yahoo.co.uk