

LEIOMYOSARCOMA OF TUNICAL VAGINALIS IN AN ELDER MAN CASE REPORT

A.H. EL SHEIKH AND B.K. AL HALLANI

Department of Urology, Menoufeya University, Egypt and Department of Pathology, Al Baath University, Homs, Syria

INTRODUCTION

Sarcoma of the male genital system is very rare compared to carcinoma with a ratio of 1:2000¹. Para testicular tumors are extremely rare and the scarce literature only provides reports of single cases or small series, mostly describing rhabdomyosarcoma. Leiomyosarcoma constitutes 2.3% of paratesticular sarcoma².

We herein report the case of a 96-year-old male patient presenting with a large testicular mass which was diagnosed as leiomyosarcoma of the tunica vaginalis.

CASE REPORT

A 96-year-old bed ridden male patient with ischemic heart disease, mild diabetes mellitus and senile dementia reported a history of long standing left testicular swelling. Two months before presentation he had developed pain in the left testis. Clinical examination revealed a large, firm to hard left testicular mass, slightly tender, with free scrotal skin. No visceromegaly was detected. Sonography revealed a lobulated enlargement of the left testis with heterogeneous echopattern and a small amount of fluid in the peripheral pockets (Fig. 1).

The patient was subjected to inguinal orchidectomy. On cutting, the tumor was found arising from the tunica vaginalis, compressing the testis which was small in size. Gross pathology revealed an oval-shaped mass measuring 13 x 6 x 5 cm, which was firm to hard in consistency, lobulated and well circumscribed (Fig. 2). It showed a whitish nodular surface with foci of hemorrhage and necrosis.

Microscopically, the tumor was composed of interweaving bundles of pleomorphic malignant

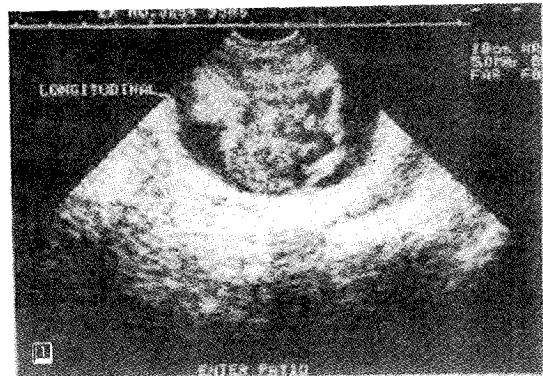


Fig. 1: Sonography of the left testis showing lobulated enlargement

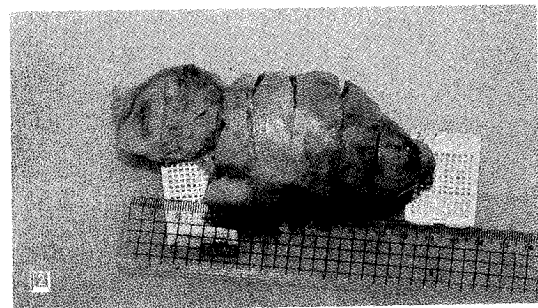


Fig. 2: Gross picture of the oval-shaped, lobulated and well-circumscribed mass

spindle cells with elongated, cigar-shaped nuclei and frequent mitotic figures; some were atypical. There were also large areas of necrosis and focal hemorrhage (Fig. 3).

Immunostaining profile showed diffuse positive staining for Desmin and smooth muscle actin (SMA) in the cytoplasm of the tumor cells (Fig. 4, 5). Pathological diagnosis revealed a leiomyosarcoma of the tunica albuginea.

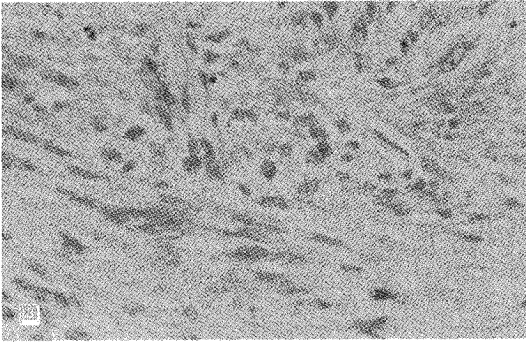


Fig. 3: Micrograph showing interweaving bundles of pleomorphic malignant spindle cells with elongated, cigar-shaped nuclei and frequent mitotic figures (H & E x 200)




Fig. 4: Immunostaining profile showing diffuse positive staining with anti Desmin (x 400)

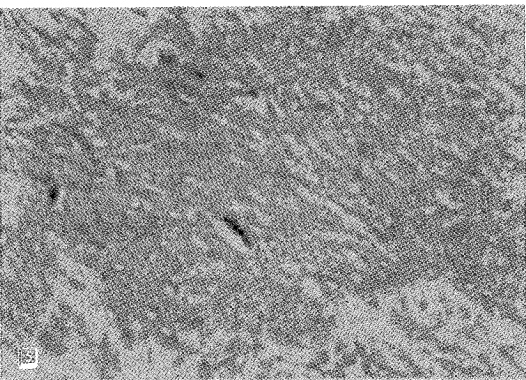


Fig. 5: Immunostaining profile showing diffuse positive staining with anti SMA peroxidase (x 400)

The patient was followed up by sonography and chest x-ray from end of May 2001 until January 2004. No local recurrence or remote metastasis could be detected.

DISCUSSION

Leiomyosarcoma constitutes 2.3% of paratesticular sarcoma². It arises from the epididymis, the spermatic cord or the tunica albuginea. It may also arise from the testis itself^{3,4}. Leiomyosarcoma of the tunica vaginalis is extremely rare^{5,6} and very few cases have been reported in the literature. Due to its rarity it appears to be of unknown prognostic potential. Although some authors deny the adequacy of local excision alone⁷, the generally accepted treatment is inguinal orchidectomy with meticulous follow-up^{3,4,8}.

In our case inguinal orchiectomy was done, and the tumor was proven to be leiomyosarcoma of the tunica vaginalis. Follow up for 31 months proved no recurrence.

We conclude that leiomyosarcoma of the tunica vaginalis is a tumor with a very low incidental rate. The rare literature on this topic has shown that inguinal orchidectomy is an effective treatment providing good results^{3,4,8}.

REFERENCES

1. Dixon FJ, Moore RA. Tumors of the male sex organ. In: Atlas of Tumor Pathology. Published by: Washington Armed Forces Institute of Pathology, p. 173, 1952.
2. El Badawi AA, Al Ghorab MM. Tumors of the spermatic cord. A review of the literature and a report of a case of lymphangioma. *J Urol* 1965, 94:445.
3. Hachi H, Bougtab A, Amhajji R *et al.* A case report of testicular leiomyosarcoma. *Med Trop* 2002, 62:531.
4. Ali Y, Kehinde EO, Makar R, Al Awadi KA, Anim JT. Leiomyosarcoma complicating chronic inflammation of the testis. *Med Princ Pract* 2002, 11:531.
5. Bajaj P, Agarwal K, Niveditha SR, Pathania OP. Leiomyosarcoma arising from tunica vaginalis testis: a case report. *Indian J Pathol Microbiol* 2001, 44:145.
6. Ochoa Urdangarain O, Gomez Areces R, Gonzalez Guerra O, Vazquez Curbelo JJ, Padiernes R. Leiomyosarcoma of tunica albuginea: presentation of a case and review of literature. *Arch Esp Urol* 1989, 42:155.
7. Sane SY, Nimbkar SA, Bapat RD. Leiomyosarcoma of hydrocele sac (a case report). *J Postgrad Med* 1980, 26:145.
8. Sattary M, Hazraty B, Bagche SM. Primary pure testicular low grade leiomyosarcoma. *Iranian Journal of Medical Sciences* 2003, 28:48.