

## TUBULARIZED INCISED PLATE (TIP) URETHROPLASTY: EXTENDED USE IN HYPOSPADIAS RE-OPERATION

A.M. KAMAL\*, S.E. ABOU HASHEM\*\* AND H.K. YOSSEF\*\*\*

*Departments of General Surgery\*, Urology\*\* and Pediatrics\*\*\*, Faculty of Medicine, Zagazig University, Zagazig, Egypt*

**Objective:** Recently, tubularized incised plate (TIP) urethroplasty (Snodgrass repair) has gained popularity for the primary repair of distal and proximal hypospadias. This study was carried out to evaluate TIP urethroplasty in the repair of failed and complicated hypospadias cases.

**Patients and Methods:** This study was carried out in the pediatric surgery unit, Departments of General Surgery and Urology, Zagazig University Hospital. Twenty-four patients with failed and complicated hypospadias with an intact urethral plate were included in this work. Thirteen patients (54%) were younger than 3 years, and 3 patients (13%) older than 6 years. The original hypospadias was coronal in 4, midshaft in 11 and penoscrotal in 9 cases. Wide fistula was present in 8 cases (32%) and dehiscence was found in 6 cases (26%). Previous procedures included meatal advancement and glanuloplasty incorporated (MAGPI) in 5 (21%) cases, Mathieu procedure in 4 (17%), and prepuce flaps in 13 (55%) cases. Two patients (8%) had been subjected to previous TIP urethroplasty. Twenty cases had had a single preceding procedure, while 4 cases had been subjected to two previous trials of correction. The time that had elapsed before re-operation was less than 6 months in 14 cases (58%).

**Results:** Fistula occurred in 3 cases, two of them had had preoperative fistula. Meatal and anastomotic strictures occurred in 2 cases each and were completely managed by dilatation for 3-6 months. Wound infection occurred in 5 cases. Good cosmetic and functional results were achieved in 15 cases (63%). TIP urethroplasty was found to be suitable for re-operating previously failed hypospadias cases because it reconstructs the urethra entirely from the urethral plate which is the least affected part after all types of repair. Also, no relation was found between the morphology of the urethral plate and the success of TIP repair. Most of the cases had an intact urethral plate which had not been incised in the primary procedure. Further studies are needed to assess the possibility of using a urethral plate which was previously incised in a primary procedure.

**Conclusion:** TIP urethroplasty could be a reasonable procedure in failed and complicated hypospadias cases. It provides good cosmetic and functional results and can be done using minimal residual tissues remaining after primary procedures.

**Keywords:** tubularized incised plate, hypospadias re-operation.

### INTRODUCTION

The evolution of hypospadias surgery has resulted in excellent outcomes, especially in patients with midshaft and distal defects<sup>1</sup>. The urologist now has a variety of surgical procedures and techniques that can attain the following surgical goals: conical glans, distally positioned slit-like meatus, normal urethral

caliber, circumferential mucosal collar, correction of chordee, and creation of a median raphe<sup>2</sup>.

However, the potential complications of urethrocutaneous fistula, abnormal urethral caliber (stricture or diverticulum) and residual chordee are always looming, despite the improved outcomes that the newer techniques provide<sup>3</sup>.

**Table 1: Patients' Data**

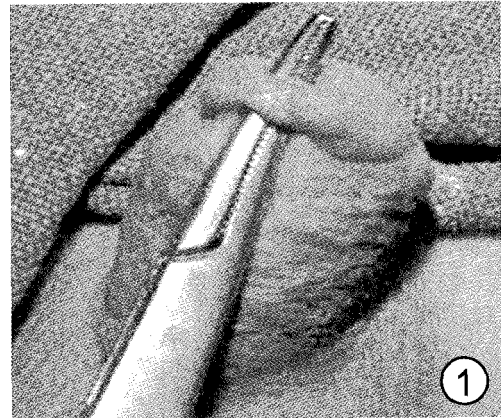
	No.	%
<u>Age:</u>		
>3 years	13	54%
3-6 years	8	33%
<6 years	3	13%
<u>Original Defect:</u>		
- coronal	4	17%
- midshaft	11	46%
- penoscrotal	9	37%
<u>Defect at presentation:</u>		
- wide fistula	8	32%
- diverticulum	5	21%
- incomplete correction	5	21%
- dehiscence	6	26%
<u>Previous operations:</u>		
- MAGPI*	5	21%
- Mathieu**	4	16%
- preputial onlay flap	7	29%
- preputial tubularized flap	6	26%
- TIP urethroplasty	2	8%
<u>No. of procedures:</u>		
- one	20	84%
- two	4	16%
<u>Time elapsed since first procedure:</u>		
>6 months	14	58%
6 – 12 months	7	29%
<12 months	3	13%

\* meatal advancement and glanuloplasty incorporated

\*\* meatal based onlay flap

The term urethral plate has been commonly applied to the strip of tissue that extends distally from the hypospadiac meatus to near the tip of the glans. These tissues historically were thought to contribute to the ventral penile curvature that often complicates hypospadias surgery<sup>4</sup>. This concept was responsible for the original practice of routinely transecting or resecting the urethral plate to achieve straightening<sup>5</sup>.

In 1987, Elder et al<sup>6</sup>. described their results using a transverse preputial island flap with an



**Fig. 1:** Preoperative photo showing a skin bridge after failed repair

onlay technique using the urethral plate. This technique demonstrated that chordee mostly was related to the skin and subcutaneous tissue and did not result from an abnormality of the urethral plate. Also, the use of the native urethral plate was believed to ensure excellent vascularity and urethral caliber<sup>7</sup>.

A longitudinal midline incision of the distal urethral plate was introduced by Rich et al. in 1989 aiming at the improvement of the cosmetic results of the Mathieu and onlay island flap procedures<sup>8</sup>. In 1994 Snodgrass described an extension of the incision proximally to the level of the hypospadiac meatus and emphasized that the deep incision of the shallow urethral plate was the most important part of tubularized incised plate urethroplasty<sup>9</sup>. It was suggested to extend the application of this procedure to proximal and complicated hypospadias cases<sup>10</sup>.

Previous surgical procedures often leave the patients with significant scarring and a limited amount of penile skin for secondary surgery. These factors make secondary hypospadias surgery more complicated than primary procedures<sup>11</sup>. The paucity of local tissue in secondary cases highlights the value of preserving the urethral plate, as it is the least affected part in most hypospadias repairs<sup>12</sup>.

In this study, we evaluated the role of tubularized incised urethral plate (TIP) urethroplasty for secondary and complicated hypospadias cases in which the plate was preserved during primary procedures.

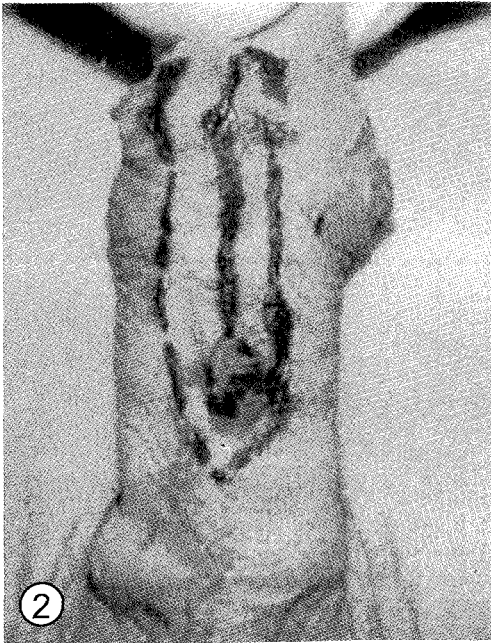

Fig. 2: Incision lines in a re-operation case

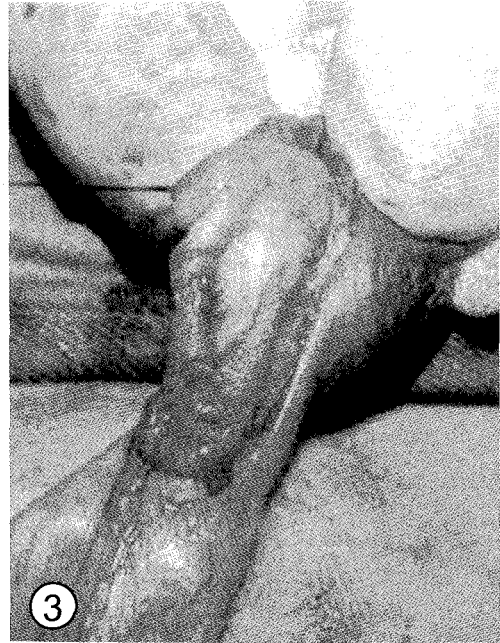

Fig. 3: Incision of the urethral plate in a re-operation case

## PATIENTS AND METHODS

Twenty-four patients with failed hypospadias repair were managed by tubularized incised plate (TIP) urethroplasty. Thirteen boys (54%) were younger than 3 years, 8 (33%) were between 3 and 6 years old and 3 (13%) were older than 6 years. (Table 1)

The original hypospadias was coronal in 4, midshaft in 11 and penoscrotal in 9 cases. Previous procedures included meatal advancement and glanuloplasty incorporated (MAGPI) in 5 (21%), Mathieu procedure in 4 (17%) and preputial flaps in 13 (55%) patients. TIP urethroplasty had been attempted in the remaining 2 (8%) cases. Twenty patients had been subjected to a single previous procedure, while four had gone through two previous trials of correction. (Table 1)

The time that had elapsed before re-operation was less than 6 months in 14 cases (58%).

The defects at presentation included wide fistula in 8 (32%), diverticulum in 5 (21%), incomplete repair in 5 (21%) and dehiscence of repair in 6 (26%) patients. (Table 1)

The presence of an intact urethral plate was an essential criterion. Cases in which the urethral plate was excised during the primary procedure were excluded. Also, cases with narrow fistulas which could be repaired primarily were excluded.

All patients were operated by the same team at the pediatric surgery unit of the general surgery and urology departments of Zagazig University Hospitals. The basic surgical technique was tubularized incised plate (TIP) urethroplasty according to Snodgrass<sup>9</sup>.

Follow-up was between 8 and 20 months.

### Surgical technique<sup>13</sup>.

The available tissue is identified and the urethral plate is cleared from skin tags or bridges (Fig. 1). The skin between the fistula or diverticulum and the meatus is cut longitudinally so that the underlying urethral plate can be exposed and treated as a longer urethral defect. Artificial erection is performed in each case. A tunica albuginea plication is used to treat residual chordee. Longitudinal incisions are made parallel to the edges of the urethral plate and encircling the meatus (Fig. 2). The

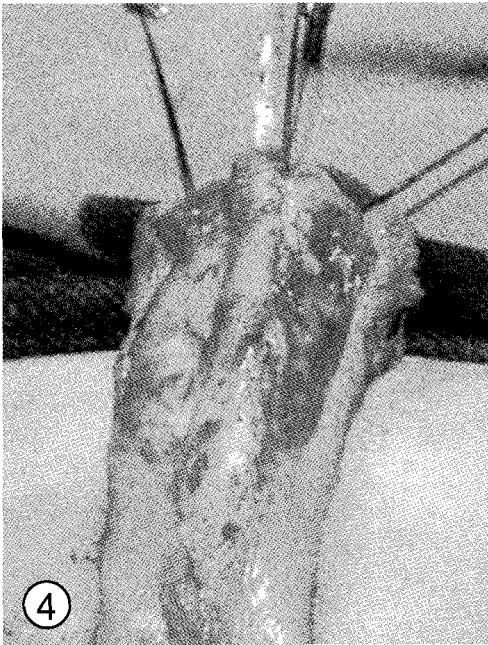


Fig. 4: Tubularization of the urethral plate

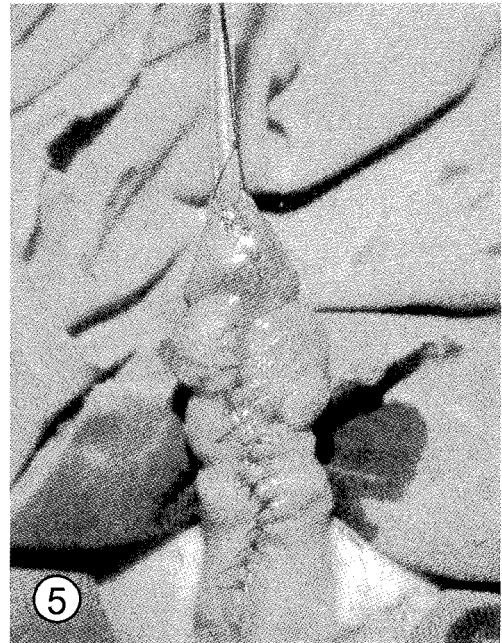

Fig. 5: Final repair in a re-operation case

urethral plate is then incised at the midline (Fig. 3) and tubularized around a stent (Fig. 4) with the stent size ranging from 8 to 10 Fr. depending on the patient's age and the size of the proximal urethra. An adjacent subcutaneous tissue flap, a dartos flap dissected from the scrotum or a tunica vaginalis flap is used as a second layer of vascularized coverage to augment the neourethral suture line. The skin is then closed and a mucosal collar is done (Fig. 5). The urethral stent is removed 7 or 8 days following the procedure.

## RESULTS

In our series, postoperative complications consisted of fistula in 3 (13%), meatal stenosis in 2 (7%), anastomotic stricture between the normal and the neourethra in 2 (7%), wound infection in 5 (21%) patients and urosepsis in 1 patient (4%). Out of the three patients that developed fistula, two had had preoperative fistula. The wound infection and urosepsis were treated conservatively.

Good cosmetic and functional results were achieved in 15 cases (63%).

## DISCUSSION

Most available microscopic studies of the urethral plate demonstrate that it is composed of epithelium overlying well-vascularized connective tissue<sup>5</sup>. Baskin et al.<sup>14</sup> performed histological studies and compared the normal with the hypospadiac fetal penile anatomy which appeared to confirm a copious blood supply to the urethral plate in boys with hypospadias. They compared the anatomy of hypospadiac and normal fetal penises using immunostaining techniques and noted that the most striking difference involved the relative vascularity. The vascularity of the distal urethral spongiosum and glans was more extensive in hypospadiac than in normal penises.

In hypospadias repair, it was suggested that incising the distal urethral spongiosum and glans, which are rich in large endothelial lined sinuses, results in the release of epithelial growth factor encouraging tissue repair. This may explain absent significant scar and stricture formation after tubularized incised plate urethroplasty<sup>15</sup>.

Twenty-two cases of our series (92%) had been managed primarily by procedures which

did not include incision of the urethral plate. This means that during re-operation the plate was incised for the first time. This allowed for a good healing of the roof of the neourethra. Among the two cases of meatal stenosis in our study, one had primarily been managed by TIP urethroplasty. In this case we faced a higher risk that re-incision of the urethral plate might induce fibrosis than in primary cases, but further studies are needed to evaluate this point.

The neourethra suture line was augmented by local available tissues and tunica vaginalis. The primary procedures mostly included circumcision of the penis causing a shortage of available tissues for coverage of the neourethra. The importance of the second-layer urethroplasty in preventing dehiscence and fistula formation has been previously described<sup>16</sup>. In our series, difficulty in establishing a second layer was encountered proximally because the urethral plate was not wide enough in this area and the mobilization of tissues was more difficult.

Vascularized second-layer coverage over the neourethra was considered an important factor in achieving a better success rate in primary and re-operative Snodgrass procedures<sup>17</sup>. It was concluded that a meticulous dissection of the subcutaneous tissue adjacent to the neourethra usually provided tissues for second-layer coverage. A dartos flap may also be used as second-layer coverage if local subcutaneous tissue is not available<sup>18</sup>. Cooper et al.<sup>19</sup> reported that incorporation of the well-vascularized spongiosa tissue located along the sides of the urethral plate in the suture lines provided coverage and reduced fistula formation when using onlay island flap for hypospadias repair.

Tubularized incised plate hypospadias repair requires an adequate midline incision of the urethral plate to construct a normal caliber neourethra. Some authors assumed that the configuration of the urethral plate affected tubularization. For instance, Holland and Smith<sup>20</sup> found increased complications during tubularized incised plate urethroplasty when the plate was less than 8 mm wide or had a shallow groove before midline incision. Conversely, other authors concluded that this technique was successful regardless of the urethral plate configuration, whether flat, deeply grooved, wide or narrow<sup>10</sup>. Whether the distortion of the urethral plate by previous operations adversely affects the outcome of re-operation procedures

is controversial. Simmons et al.<sup>12</sup> analysed the records of 36 patients who underwent salvage onlay flap repair for persistent fistula, dehiscence or stricture and reported a success rate of 93% (28 / 30) and 50% (3 / 6) in the dehiscence and stricture groups, respectively. In our study, no severe distortion of the urethral plate was found, and no difficulty was encountered with the tubularization of the plate. Fistulas and strictures which occurred in our re-operation cases appear to be related to the surgical technique rather than the original character of the urethral plate.

Many trials have been undertaken to study the best procedure for hypospadias re-operation. In one study, there was no significant difference between the complication rates of tubularized incised plate urethroplasty, Mathieu, Duplay or onlay technique<sup>15</sup>. It was stated that a limited number of incisions and sutures was preferable. Accordingly, the Duplay technique should be preferable to tubularized incised plate, Mathieu and onlay repair, while the Duplay technique and tubularized incised plate urethroplasty should be preferable to Mathieu and onlay repair.

Upadhyay et al.<sup>21</sup> do not recommend the TIP technique for midshaft hypospadias. They prefer an onlay flap in cases of a preserved urethral plate with good blood supply. Moreover, Jayanthi et al.<sup>22</sup> advocate the creation of a local skin flap, even in re-do cases. These flaps can either be meatally based, if the scar distribution allows this, or a transverse island flap off the preputial skin that has been transposed ventrally during a prior procedure. In more than 90% of the re-do cases done by Jayanthi et al., the defect was successfully corrected in the majority of cases using a local skin flap.

With respect to scarring and the deficiency of skin in most re-operative cases, tubularized incised plate (TIP) urethroplasty is the preferred procedure. It fulfils many criteria needed in this situation such as generous vascularity of the urethral plate, relative simplicity of the technique, consistent availability of tissue necessary to complete the repair and excellent cosmesis<sup>13</sup>.

In conclusion, tubularized incised plate (TIP) urethroplasty is a versatile procedure with a potential applicability to a wide spectrum of hypospadias conditions. It is a suitable option for the treatment of previously failed hypo-

spadias repair with a low complication rate. It does not include flaps or pedicles which might be the cause of failure in other procedures. Also, it is suitable in cases with deficient skin. The presence of an intact urethral plate is of utmost importance, but a controlled study is needed to further clarify the effect of previous incisions of the plate on the final outcome of the re-operation.

#### REFERENCES

1. Retik AB, Mandell J, Bauer SB, Atala A. Meatal based hypospadias repair with the use of a dorsal subcutaneous flap to prevent urethrocutaneous fistula. *J Urol* 1994, 152:1229.
2. Stock JA, Hanna MK. Distal urethroplasty and glanuloplasty procedure: results of 512 repairs. *Urology* 1997, 49:449.
3. Belman AB. The de-epithelialized flap and its influence on hypospadias repair. *J Urol* 1994, 152:2332.
4. Creevy CD. The correction of hypospadias: a review. *Urol Surv* 1958, 8:2.
5. Snodgrass W, Patterson K, Plaire JC, Grady R, Mitchell ME. Histology of urethral plate: implications for hypospadias surgery. *J Urol* 2000, 164:988.
6. Elder JS, Duckett JW, Snyder HM. Onlay island flap in the repair of mid and distal penile hypospadias without chordee. *J Urol* 1987, 138:376.
7. Smith DP. A comprehensive analysis of tubularized incised plate hypospadias repair. *Urology* 2001, 57:778.
8. Rich MA, Keating MA, Snyder HM, Duckett JW. Hinging the urethral plate in hypospadias meatoplasty. *J Urol* 1989, 142:1551.
9. Snodgrass W. Tubularized, incised plate urethroplasty for distal hypospadias. *J Urol* 1994, 151:464.
10. Snodgrass W, Koyle M, Manzoni G, Hurwitz R, Caldamone A, Ehrlich R. Tubularized incised plate hypospadias repair: results of a multicenter experience. *J Urol* 1996, 156:839.
11. Wheeler R, Malone P. The role of Mathieu repair as a salvage procedure. *Br J Urol* 1993, 54:724.
12. Simmons GR, Cain MP, Casale AJ, Keating MA, Adams MC, Rink RC. Repair of hypospadias complications using the previously used urethral plate. *Urology* 1999, 54:724.
13. Yang SSD, Chen SC, Hsieh CH, Chen YT. Reoperative Snodgrass procedure. *J Urol* 2001, 166:2342.
14. Baskin LS, Erol A, Li YW, Cunha GR. Anatomical studies of hypospadias. *J Urol* 1998, 160:1108.
15. Borer JG, Bauer SB, Peters CA *et al.* Tubularized incised plate urethroplasty: expanded use in primary and repeat surgery of hypospadias. *J Urol* 2001, 165:581.
16. Gittes GK, Snyder CL, Murphy JP. Glans approximation procedure urethroplasty for the wide, deep meatus. *Urology* 1998, 52:499.
17. Ross JH, Kay R. Use of a de-epithelialized local skin flap in hypospadias repairs accomplished by tubularization of the incised urethral plate. *Urology* 1997, 50:110.
18. Churchill BM, van Savage JG, Khoury AE, McLorie GA. The dartos flap as an adjunct in preventing urethrocutaneous fistulas in repeat hypospadias surgery. *J Urol* 1996, 156:2047.
19. Cooper CS, Noh PH, Snyder HM 3<sup>rd</sup>. Preservation of urethral plate spongiosum: technique to reduce hypospadias fistulas. *Urology* 2001, 57:351.
20. Holland A, Smith G. Effect of the depth and width of the urethral plate on tubularized incised plate urethroplasty. *J Urol* 2000, 164:489.
21. Upadhyay J, Shekarriz B, Khoury AE. Midshaft hypospadias. *Urol Clin North Am* 2002, 29:299.
22. Jayanthi VR, McLorie GA, Khoury AE, Churchill BM. Can previously relocated penile skin be successfully used for salvage hypospadias repair? *J Urol* 1994, 152:740.

#### RESUME

##### Lit urétral incisé et tubulisé (TIP): Extension des indications aux reintervention pour hypospadias

**Objectifs :** Récemment, l'urétroplastie par Lit urétral incisé et tubulisé (TIP ou technique de Snodgrass) a gagné une popularité pour la réparation primaire des hypospadias distaux et proximaux. Cette étude a été effectuée pour évaluer l'urétroplastie par TIP dans la réparation des échecs de cure et des cas compliqués d'hypospadias. **Patients et méthodes :** Cette étude a été effectuée dans l'unité de chirurgie pédiatrique, départements de chirurgie générale et urologie, hôpital universitaire de Zagazig. Vingt-quatre patients présentant des échecs de cure d'hypospadias compliqués avec un lit

urétral intact ont été inclus dans ce travail. Treize patients (54%) étaient de moins de 3 ans, et 3 patients (13%) de plus de 6 ans. Les hypospadias originaux étaient coronaux dans 4 cas, mipéniens dans 11 cas et penoscrotaux dans 9 cas. La fistule large était présente dans 8 cas (32%) et une déchirure a été retrouvée dans 6 cas (26%). Les procédures précédentes ont inclus l'avancement méatal et la glanuloplastie (MAGPI) dans 5 cas (21%), le procédé de Mathieu dans 4 cas (17%), et ailerons préputiaux dans 13 cas (55%). Deux patients (8%) avaient eu une uréthroplastie par TIP première. Vingt cas avaient eu une seule cure simple, alors que 4 cas avaient été soumis à deux cures de correction. Le temps écoulé avant la correction était moins de 6 mois dans 14 cas (58%). **Résultats** : La fistule s'est installée dans 3 cas, deux d'entre eux avaient eu une fistule préopératoire. La sténose anastomotique méatale s'est produite dans 2 cas traités par des dilatations itératives pendant 3-6 mois avec succès. L'infection de la plaie a été notée chez 5 patients. Un bon résultat esthétique et fonctionnel a été réalisé chez 15 patients (63%). L'uréthroplastie par TIP s'est avérée appropriée à réopérer des cas d'échec de cure d'hypospadias parce qu'elle reconstruit l'urètre entièrement à partir du lit urétral qui est la zone la moins altérée après toutes les tentatives de réparation. En outre, aucune relation n'a été trouvée entre la morphologie du lit urétral et le succès de la réparation par TIP. La plupart des cas ont présenté un plat urétral intact qui n'avait pas été incisé lors de la cure primaire. D'autres études sont nécessaires pour évaluer la possibilité d'utiliser un lit urétral qui a été précédemment incisé lors d'une cure primaire. **Conclusions** : L'uréthroplastie par TIP a pu être un choix raisonnable pour des cas d'échec de cure et des cas compliqués d'hypospadias. Il fournit de bons résultats esthétiques et fonctionnels et peut être réalisé en utilisant les tissus résiduels minimaux restants après des procédures primaires.

All correspondence to be sent to:

S.E. Abou Hashem, M.D.  
Urology Department, Faculty of Medicine  
Zagazig University  
Zagazig  
Egypt

E-mail: safwat\_a\_hashem@hotmail.com