

THE USE OF BUCCAL MUCOSA FOR ANTERIOR URETHROPLASTY: NEW CONCEPTS AND CONCERNS

G. BARBAGLI

Centre for Urethral and Genital Reconstructive Surgery, Arezzo, Italy

INTRODUCTION

At the beginning of the third millennium a lot of certainties regarding adult anterior urethral stricture disease must be abandoned, and new knowledge must be gained. The changes involve the etiology of urethral diseases and the surgical techniques used for anterior urethroplasty¹⁻⁵.

In the adult male patient, urethral stricture involving the penile urethra may be due to failed hypospadias repair, ischemia or inflammatory disease in the corpus spongiosum⁵. In the last century the most important cause of inflammatory disease of the corpus spongiosum causing narrowing of the urethral mucosa and stricture, was infection due to *Neisseria gonorrhoea*. Today, blenorrhagia or sexually transmitted diseases (STDs) are rarely reported as a cause of urethral stricture in patients coming from developed countries, although STDs have increased.

A new chronic inflammatory disease of the male genitalia, which may involve the entire pendulous urethra causing complex and devastating stricture, is Lichen sclerosus (LS), also known as Balanitis xerotica obliterans (B.X.O.)⁶⁻⁹.

The surgical treatment of adult anterior urethral strictures has been a constantly evolving process. Recently, considerable changes have been introduced: the wider use of the buccal mucosa graft versus the use of penile skin, and the use of dorsal onlay urethroplasties, also named Barbagli procedures¹⁰⁻¹⁶. Moreover, in the penile urethra the dorsal placement of the graft is now combined with the incision of the urethral plate, as suggested by Snodgrass for childhood hypospadias surgery¹⁷, and its augmentation as suggested by Hayes¹⁸ and Asopa¹⁹.

Renewed controversy exists over the best means of reconstructing the anterior urethra²⁰.

The popularity of flaps and grafts has varied over time, and in the last years the free grafts have been resurgent, thus reducing the use of genital flaps²⁰⁻²¹. The current literature does not clearly support us in the choice of either the use of penile graft or flap urethroplasty. No prospective comparison of graft and flap has ever been carried out, making it hard to declare a clear winner. The reconstructive urologist must be fully familiar with the use of both flaps and grafts to deal with any condition of the urethra at the time of surgery. Moreover, the use of two-stage or mesh-graft urethroplasty may be the only way to restore the urethral lumen in patients with complex urethral stricture disease^{5,22}. The flow chart, which we present here, is based on the current and updated literature, and on the present clinical and pathological classification of anterior urethral diseases⁵. Furthermore it is based on our daily clinical experience that includes about 400 urethroplasties a year.

AETIOLOGY OF ANTERIOR URETHRAL STRICTURES

In adult male patients, urethral strictures involving the penile urethra are due to:

failed hypospadias repair: the stricture may involve the external urethral meatus or the entire pendulous urethra, and is frequently associated with diverticula, stones, hair, fistula, cosmetic defects, and residual penile curvature. In these patients the foreskin is absent, and the vascularity of the residual penile skin is irregular and not predictable, and the dartos fascia is thin and not available for a dependable vascular and mechanical support to a penile graft or flap^{5,23}.

ischemia: these strictures are frequently observed in patients after urological endoscopic procedures or cardiovascular surgery²⁴⁻²⁶, and in patients in the resuscitation room, with an indwelling catheter in place.

In these patients, the penis is normal, the foreskin is frequently present and the penile skin is not compromised in its vascularity. The dartos fascia is thick and useful for vascular or mechanical support to the graft or flap.

- *Lichen sclerosus*: the stricture may involve only the external urethral meatus and the fossa navicularis or the entire pendulous urethra⁶⁻⁹. In some patients the stricture may involve also the bulbar urethra, and a panurethral stricture may be observed⁶⁻⁹. In patients with LS, the glans, the foreskin, and the penile skin are involved in the disease⁶⁻⁹. These patients may require a complete glans resurfacing to improve the aesthetic appearance of the penis, as well as sexual performance⁸.

Basically, urethral strictures involving the bulbar urethra are due to:

- *congenital anomalies of the mucosal membrane*: the strictures are usually located in the proximal bulbar urethra, and the corpus spongiosum is not involved in the disease;
- *traumatic scar after blunt perineal trauma*: the stricture is located in the bulbar urethra, and the spongiosum tissue is involved in the scar;
- *Lichen sclerosus*: The strictures may involve only the external urethral meatus and the fossa navicularis or the entire pendulous urethra. In some patients the stricture may extend to the bulbar urethra, and a panurethral stricture may be observed;
- *ischemia*: these strictures are frequently observed in patients after urological endoscopic procedures, after cardiovascular surgery or in patients in the resuscitation room with an indwelling catheter in place, and may involve the bulbar urethra at different sites.

CRITERIA FOR SELECTION OF THE SURGICAL PROCEDURE

Basically, penile urethroplasty may be requested in patients with a normal penis (ischemic urethral stricture) or in patients with an abnormal penis (urethral strictures due to failed hypospadias repair or Lichen sclerosus). In patients with a normal penis the urethral plate,

the foreskin, the penile skin and the dartos fascia are available for urethral reconstruction. In these patients a one-stage augmentation urethroplasty using a graft or flap may be suggested. In patients with an abnormal penis the urethral plate, the foreskin, the penile skin and the dartos fascia are unavailable for urethral reconstruction. In these patients a staged substitution urethroplasty is advisable.

The surgical procedures for the repair of bulbar urethral strictures are selected according to the length of the stricture. In patients with congenital anomalies of the mucosal membrane *endoscopic urethrotomy* is the solution of choice. Strictures ranging from 1 to 2 cm in length are treated by using an *end-to-end anastomosis*; strictures ranging from 2 to 3 cm in length are managed by using a *dorsal augmented anastomotic urethroplasty*; strictures longer than 3 cm are treated by using *dorsal or ventral onlay graft urethroplasty*. Finally, in patients with strictures longer than 6 cm involving both the penile and bulbar urethra or associated with local adverse conditions a *two-stage urethroplasty* or *mesh graft urethroplasty* is mandatory.

SURGICAL TECHNIQUES

The buccal mucosa is receiving increased attention in the urological literature for penile and bulbar urethroplasty. The ideal surgical technique for harvesting the buccal mucosa should be simple, safe, reliable, reproducible in the hands of any surgeon, as well as based on sound anatomical principles, and on adequate surgical instruments and steps. We believe the technique we present here fulfils all these criteria.

Preoperative Considerations

Preoperative tests include urine culture, retrograde and voiding urethrography, urethral ultrasonography and urethroscopy. The patient's clinical history, and the site and length of the stricture are carefully examined to better define the characteristics that the buccal mucosa graft should have.

In all patients expecting a two-stage urethroplasty, the patient and the anesthetist are informed beforehand that bilateral buccal mucosa graft harvesting may be necessary. Patients who require small and thin grafts are

informed that the lip is a preferred donor site in this case. Finally, all patients with buccal mucosa diseases, patients who underwent previous surgery in the mandibular arch that does not allow a wide mouth opening, and patients playing wind instruments, are informed that genital or extragenital skin will be used for urethroplasty. All patients receive intravenous broad-spectrum antibiotics the day before surgery, during the procedure, and for 3 days afterwards. Three days before surgery the patient starts using chlorhexidine for oral cleansing and continues this for three days after surgery. The patient is intubated through the nose, allowing the mouth to be completely free. Two surgical teams work simultaneously at the donor and the recipient site, with each having its own set of surgical instruments including suction and bipolar cautery. The buccal retractor is provided with its own light, and using this instrument only one assistant is sufficient for harvesting of the buccal mucosa.

Harvesting and Preparing the Graft

The inner mucosal surface of the right cheek is prepared and disinfected, and Stensen's duct, located at the level of the second molar, is identified. The desired graft size is measured and marked. A solution of lidocaine with epinephrine is injected along the edges of the graft to promote haemostasis. Two stay sutures are placed in the external edge of the cheek to keep the buccal mucosa on stretch, while the outlined graft is sharply dissected and removed. The donor site is carefully examined for bleeding and closed with 5/0 rapid vicryl interrupted stitches. Harvesting from the lip, with a standard orotracheal tube, is easy and quick, but while the graft length is 5 cm, the width is only 1.5 cm. The graft is stabilized between several needles on a silicone board and carefully defatted with microsurgical instruments. When necessary, another graft may be harvested from the left cheek using the same technique. The graft is tailored according to the site, length and characteristics of the stricture.

Postoperative Care and Complications

An ice bag is applied on the cheek to avoid pain and hematoma. A clear liquid diet and ice cream are given initially and then advanced

to a soft and regular diet. The patient is discharged from the hospital three days after surgery. All patients receive postoperative broad-spectrum antibiotics, and are maintained on oral antibiotics until the catheter is removed.

Few reports about complications after buccal mucosa harvesting have been reported in the literature: Stensen's duct damage, intraoperative bleeding, facial hematoma, infection (rare), subjective local disturbance, neural damage: paresthesia from "lungobuccale" or "mentoniero" nerve, retraction from the scar: lip/cheek distortion, buccal opening limitation. In our experience (1997-2003) on 650 cases of buccal mucosa graft harvesting (mean follow-up 12 months) we have had: facial haematoma requiring emergency evacuation in one case, lip distortion and/or disesthesia in two cases and cheek granuloma requiring surgical ablation in one case.

One-stage Penile Urethroplasty with Dorsal Buccal Mucosa Graft

A circumcoronal foreskin incision is made with complete degloving of the penis, and the penile urethra is exposed (Fig. 1A). The stricture tract is fully opened by a ventral midline incision, the urethral plate is longitudinally incised on the dorsal midline down to the corpora (Fig. 1B), and the wings of the urethral plate are laterally mobilized (Fig. 1C). The graft is sutured and quilted on the bed of the dorsal urethral incision with interrupted 6/0 sutures, and an augmentation of the urethral plate is obtained (Fig. 1D). The urethra is closed and tubularised (Fig. 1E), taking advantage of the mobilized wings of the urethral plate. A dartos fascial flap is obtained to cover the urethral suture, and the glans and the penile skin are closed. A small Foley silicone catheter is left in place (Fig. 1F) for three weeks. Supra-pubic urinary drainage is unnecessary.

Comment: This kind of urethroplasty is feasible in patients with an ischemic penile stricture or with failed hypospadias repair, in which the urethral plate can be mobilized using a midline incision. The technique is not possible when the urethral plate is fibrous or full of hair, or in patients with LS disease. This procedure represents an evolution of our original technique described on 1996 for dorsal penile urethroplasty.

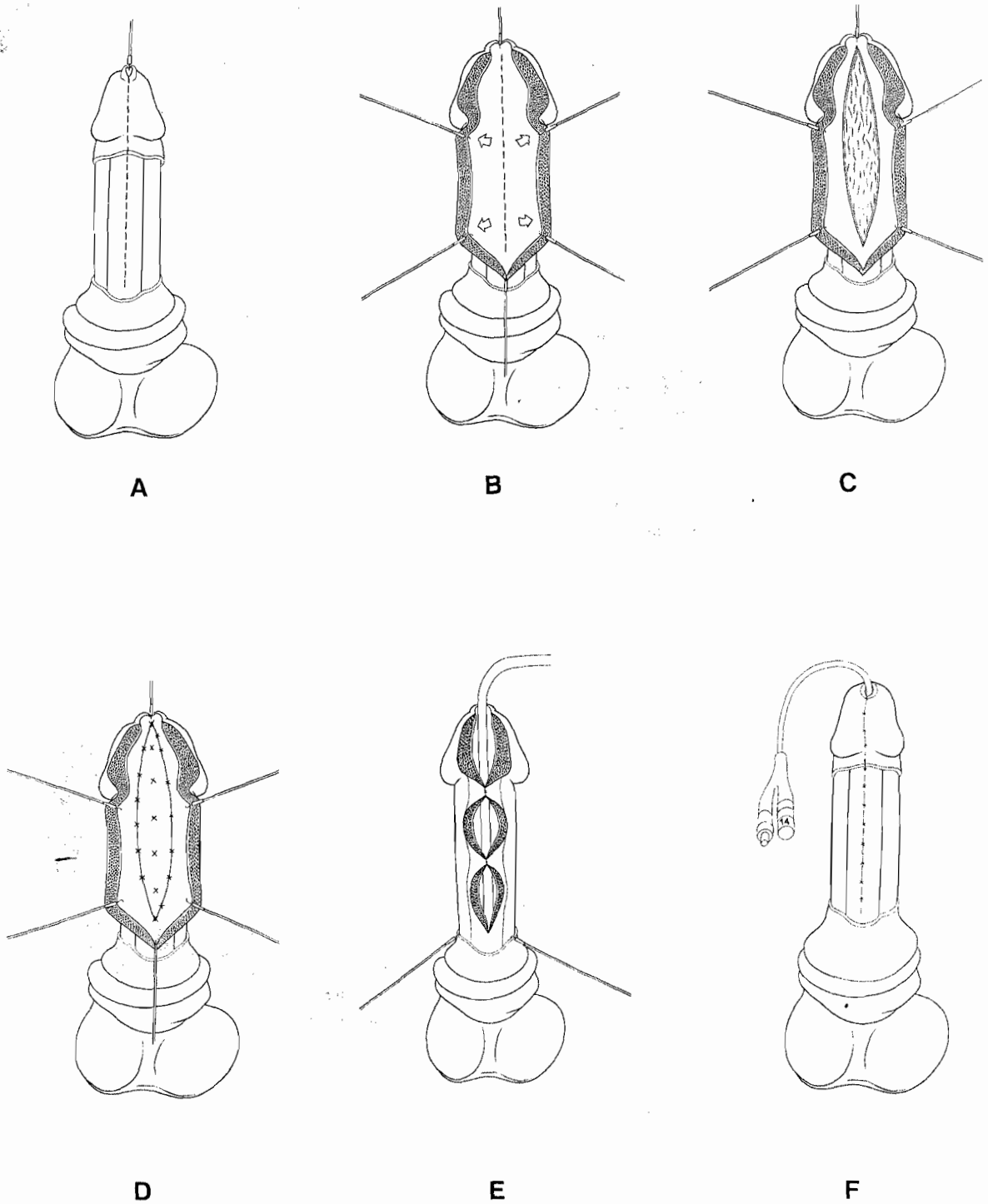


Fig. 1: Operative technique of one-stage penile urethroplasty. **A:** A circumcoronal foreskin incision is made with complete degloving of the penis, and the penile urethra is exposed. **B:** The stricture tract is fully opened by a ventral midline incision; the urethral plate is longitudinally incised on the dorsal midline down to the corpora. **C:** The wings of the urethral plate are laterally mobilized. **D:** The graft is sutured and quilted on the bed of the dorsal urethral incision with interrupted 6/0 sutures, and an augmentation of the urethral plate is obtained. **E:** The urethra is closed and tubularised. **F:** A small Foley catheter is left in place.

Two-Stage Penile Urethroplasty with Buccal Mucosa Graft

In patients with failed hypospadias repair (Fig. 2A), the penile urethral plate is excised (Fig. 2B), and the glans is fully opened (Fig. 2C). The buccal mucosa graft is splayed and quilted over the tunica albuginea and around the urethral stoma (Fig. 2D). Six months after the first stage, the patient is evaluated for urethral closure (Fig. 2E). A wide strip of buccal mucosa is obtained (Fig. 2F), and the graft is closed and tubularised up to the glans (Fig. 2G). A dartos penile fascial flap is obtained to cover the urethra. The glans and the skin are closed over the buccal mucosa graft (Fig. 2H). A Foley 12 Ch. silicone catheter is left in place for 3 weeks.

Comment: This kind of urethroplasty is suggested in patients with penile stricture due to LS or with failed hypospadias repair, in which the urethral plate is removed, because it

is inappropriate for any kind of augmentation urethroplasty.

Post-operative Course and Complications of Penile Urethroplasties

In penile urethroplasty the Foley silicone catheter is small (12 Ch), and with grooves to facilitate the passage of urethral discharge around the catheter. The catheter is left in place for 2 or 3 weeks, but is removed when pus or infection is present. After removal of the catheter, voiding urethrography is obtained. Fistula is the complication most frequently observed, and a new surgical approach will be necessary to correct the fistulous tract. Stenosis of the urethral meatus is frequently observed and a wide meatotomy will be necessary. Necrosis of the penile skin may occur after flap urethroplasty, but is rarely observed after graft urethroplasty in patients with a normal penis.

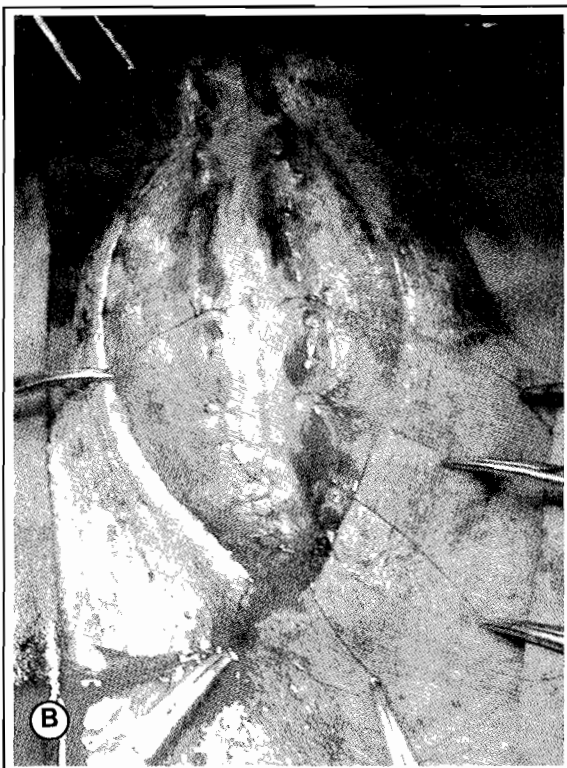
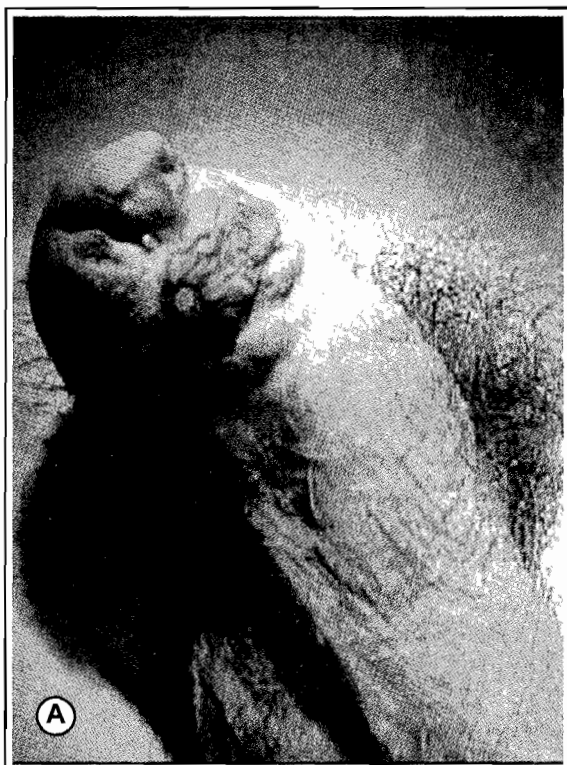

Fig. 2: Operative procedure of two-stage penile urethroplasty with buccal mucosa graft. **A:** Patient with failed hypospadias repair. **B:** The penile urethral plate is excised.

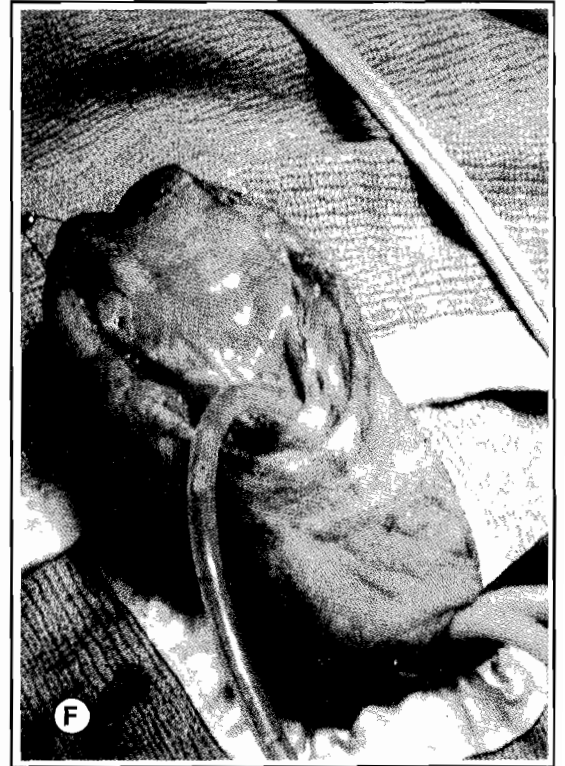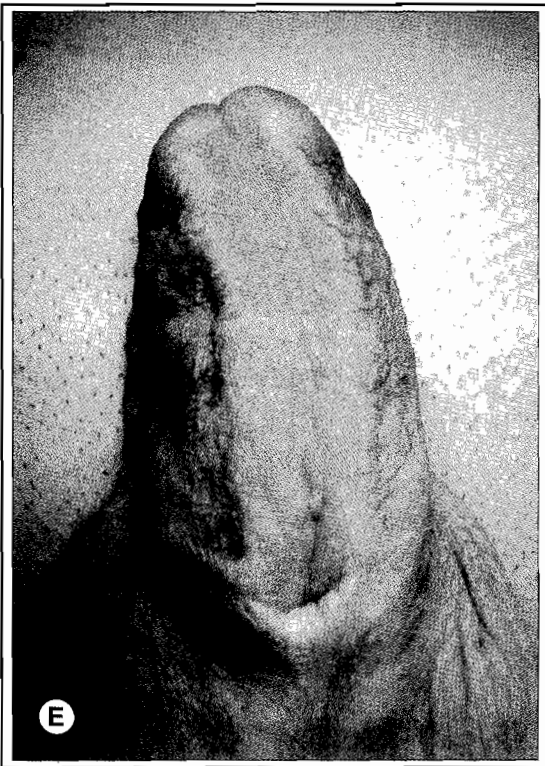
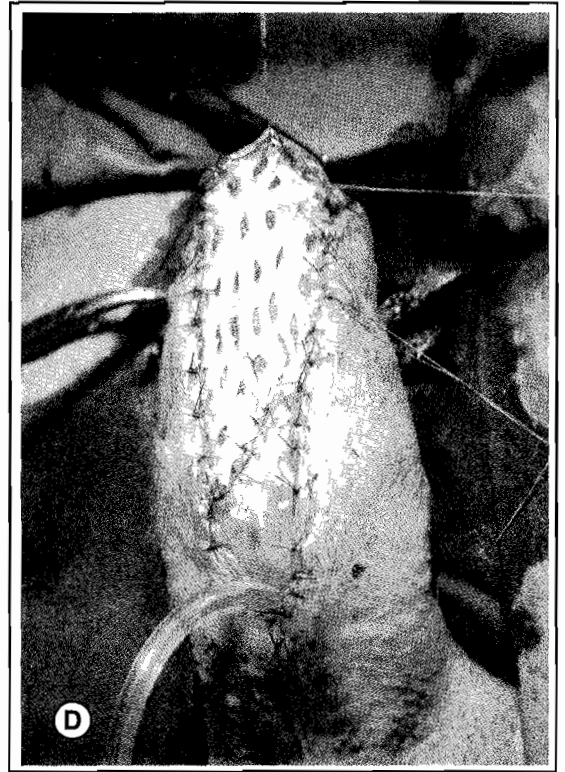

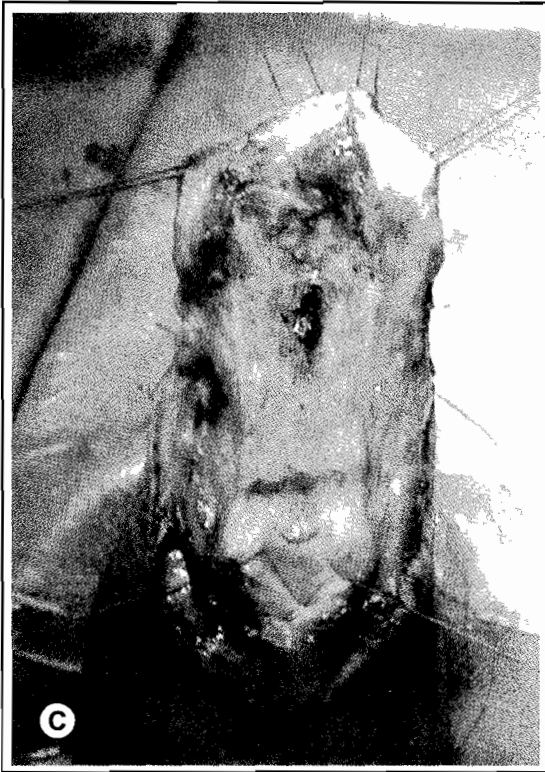
Fig. 2 (cont.): C: The glans is fully opened. D: The buccal mucosa graft is splayed and quilted over the tunica albuginea and around the urethral stoma. E: Six months after the first stage the patient is evaluated for urethral closure. F: A wide strip of buccal mucosa is obtained.

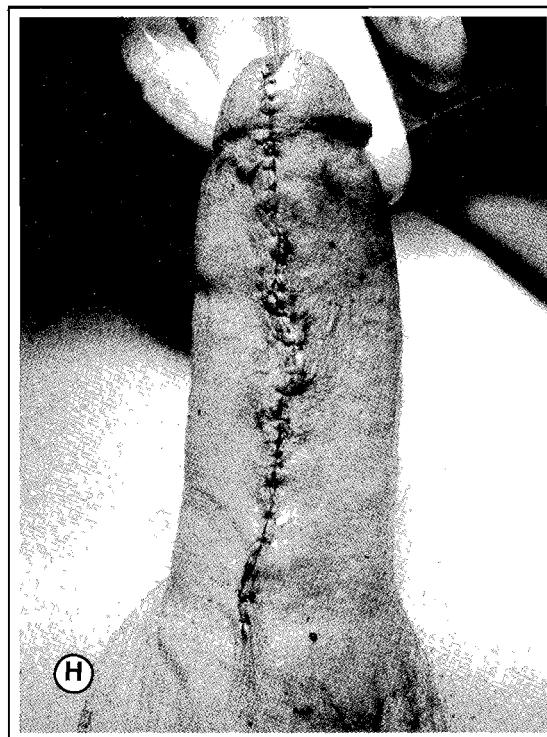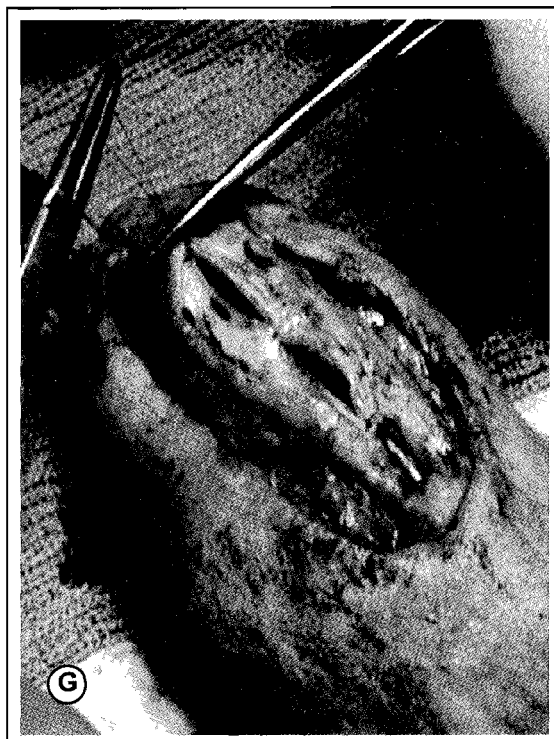


Fig. 2 (cont.): G: The graft is closed and tubularised up to the glans. H: After obtaining a dartos penile fascial flap to cover the urethra, the glans and the skin are closed over the buccal mucosa graft.

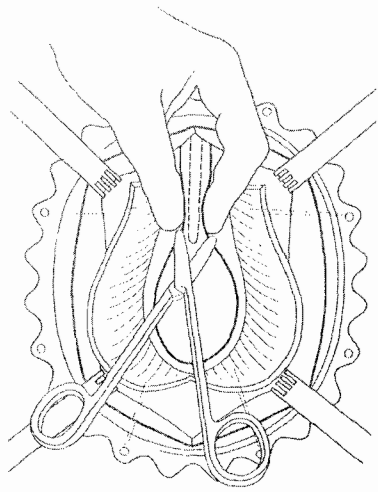
Dorsal Augmented Anastomotic Urethroplasty

A midline perineo-scrotal incision is made. The bulbo-cavernous muscles are separated, and the urethra is completely transected at the level of the stricture (Fig. 3A). The distal and proximal urethral edges are freed from the corpora cavernosa (Fig. 3B). The proximal urethral edge is ventrally opened, and the distal urethral edge is fully opened along its dorsal surface (Fig. 3C). The buccal mucosa graft is sutured to the tunica albuginea, and its margins are sutured to the proximal mucosal edge of the urethra (Fig. 3D). The distal urethral margin is sutured to the left side of the graft (Fig. 3DE). The urethra is rotated back to its original position, and the right urethral margin is sutured to the right side of the graft (Fig. 3F). At the end of the procedure, the grafted area is covered entirely by the urethra (Fig. 3F). A

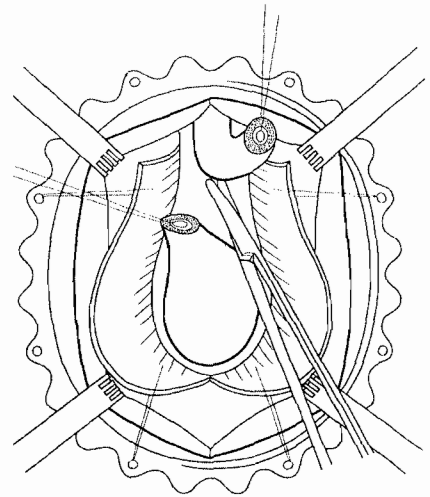
Foley silicone 16 Ch. catheter is left in place for three weeks.

Dorsal Onlay Graft Urethroplasty

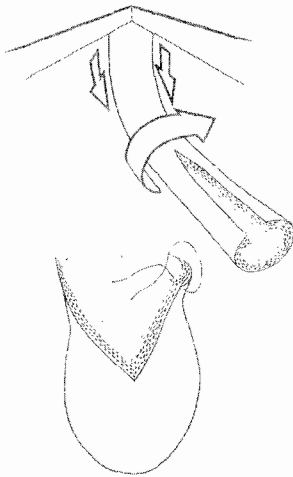
A midline perineo-scrotal incision is made. The bulbo-cavernous muscles are separated, and the bulbar urethra is dissected from the corpora cavernosa (Fig. 4A). The bulbar urethra is rotated by 180° (Fig. 4B), and the dorsal urethral surface is fully opened (Fig. 4C). The buccal mucosa graft is sutured, splayed and quilted over the corpora cavernosa using 6-0 interrupted stitches, and the right urethral margin is now sutured on the right side of the patch (Fig. 4CD). The urethra is rotated over the graft (Fig. 4D), and the left side of the graft is sutured to the left side of the urethra (Fig. 4E). At the end of the procedure the graft is completely covered by the urethra (Fig. 4E). A Foley silicone 16 Ch. catheter is left in place for three weeks.



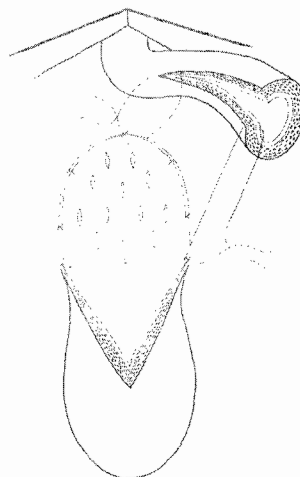
A



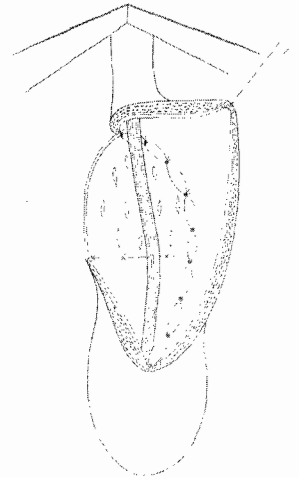
B



C



D



E

Fig. 3: Operative procedure of dorsal augmented anastomotic urethroplasty. **A:** A midline perineo-scrotal incision is made. The bulbo-cavernosus muscles are separated, and the urethra is completely transected at the level of the stricture. **B:** The distal and proximal urethral edges are freed from the corpora cavernosa. **C:** The proximal urethral edge is ventrally opened, and the distal urethral edge is fully opened along its dorsal surface. **D:** The buccal mucosa graft is sutured to the tunica albuginea, and its margins are sutured to the proximal mucosal edge of the urethra. **DE:** The distal urethral margin is sutured to the left side of the graft. **F:** The urethra is rotated back to its original position, and the right urethral margin is sutured to the right side of the graft. At the end of the procedure, the grafted area is covered entirely by the urethra.

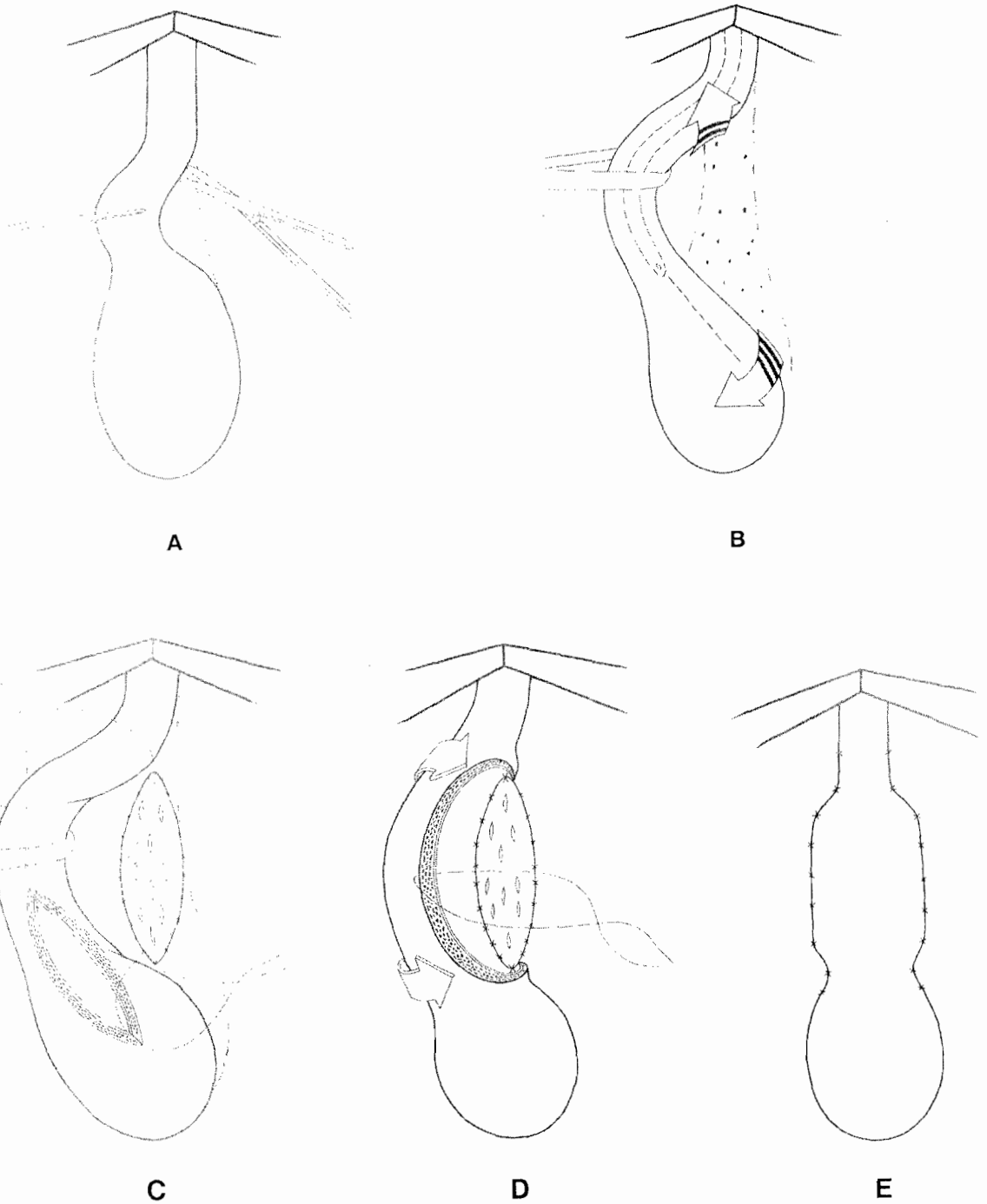


Fig. 4: Operating procedure of dorsal onlay graft urethroplasty. **A:** A midline perineo-scrotal incision is made. The bulbocavernosus muscles are separated, and the bulbar urethra is dissected from the corpora cavernosa. **B:** The bulbar urethra is rotated by 180°. **C:** The dorsal urethral surface is fully opened. **CD:** The buccal mucosa graft is sutured, splayed and quilted over the corpora cavernosa using 6-0 interrupted stitches, and the right urethral margin is now sutured on the right side of the patch. **D:** The urethra is rotated over the graft. **E:** The left side of the graft is sutured to the left side of the urethra. At the end of the procedure the graft is completely covered by the urethra.

DISCUSSION

The technique of harvesting buccal mucosa for urethral reconstruction was reviewed in detail in 1996 by Morey and McAninch, who at that time advocated nasotracheal intubation of the patient.²⁷ In 2002, some authors including Morey stated that nasotracheal intubation was preferable but not imperative²⁸. In 2003, other authors including McAninch explained clearly that "we initially preferred nasotracheal intubation but have found that this results in more postoperative discomfort and no greater access to the inner cheek. The orotracheal tube is taped over the contralateral side...."²⁹.

According to our experience, nasotracheal intubation is preferable, because the nasal tube is more anatomical and softer than the pharyngo-oral tube. We have not experienced any postoperative discomfort for the patients, and the harvesting is easy and quick, because the mouth is completely free. When working inside the mouth with the orotracheal tube taped over the contralateral side in patients with a small mouth opening, it may be difficult to harvest the buccal graft. Moreover, we experienced in two patients that the orotracheal tube was moved from its original position during the harvesting, causing serious problems for the anesthetist.

Working simultaneously in two teams - an assistant harvesting the buccal mucosa and the urologist simultaneously exposing and calibrating the stricture - presents numerous advantages: it decreases the operative time considerably and prevents troublesome complications with the patient in a lithotomy position; it increases the sterility of the surgery and prevents cross-contamination; moreover, by using a special retractor with its own light only one assistant is sufficient to work inside the mouth.

In 2001, some authors reported that during a buccal mucosa harvesting the graft was dropped on the floor, was cleaned and used without any problem, emphasizing that the buccal mucosa appears to be extremely resistant to infection; in fact, infection did not present a problem, neither at the oral nor at the perineal operative site, in any of the treated cases⁴. This is an anecdotal report, but when 8-10 buccal mucosa graft urethroplasties a week are performed, the surgical technique should be standardized and improved.

In our center, buccal mucosa harvesting is made preferably in the cheek. Lip harvesting is preferable in the following cases: when it is impossible to work inside in the mouth; when a small and thin graft for meatal or navicularis reconstruction is needed, particularly in children; when the patient has undergone a previous bilateral harvesting from the cheek, and it is not possible to perform a new harvesting in these sites. Moreover, we rarely use lip harvesting due to cosmetic reasons: many patients can suffer from retraction of the lip when they smile. We observed this complication in two patients.

The selection of the surgical procedure for reconstruction of the pendulous urethra greatly depends on the state of the penile tissues and components: foreskin, penile skin, dartos fascia, glans. Penile urethral stricture disease may represent a simple problem in patients with a normal penis, but may represent a difficult challenge in patients who had the penis damaged by previous surgeries (hypospadias failure) or by inflammatory changes (LS).

Penile urethroplasty, whether a one-stage or a two-stage repair, is intrinsically prone to complications such as hematoma or infection, which, in turn, lead to secondary complications such as fistulae (which do not occur in the bulbar or posterior urethra). On the other hand, this procedure is the one most likely to produce alterations in sexual function^{30,31}.

In patients requiring penile urethroplasty, the use of a buccal mucosa graft avoids cosmetic disadvantages caused by the use of the local genital skin, such as penile-glans torsion, subcutaneous deformity or chordee. In patients with LS the use of buccal mucosa as a graft is mandatory, because LS is a skin disease, thus any skin used for the repair may also become diseased and usually also becomes diseased in due course^{4,6}.

Moreover, in patients requiring penile urethroplasty the use of free grafts does not require extensive training in tissue transfer procedures, as does the use of a penile flap. So far, it has not been established yet in which patients the use of the buccal mucosa graft may be successful in penile one-stage urethroplasty. We are not sure either about the proper anatomical characteristics the penis should have in order to ensure the graft taking. The penile spongiosum tissue and dartos fascia do not ensure a good vascular and me-

chanical support to the graft in all patients²⁰. What type of vascular support can be used? In which patients could the use of a pedicled flap instead of a free graft have better chances of success? What is the role of urethral plate salvage in the reconstructive armamentarium? Morey suggests that urethral plate replacement may be necessary in a minority of complex, long, severe strictures, and describes a new penile urethroplasty by using a graft-flap combined procedure³².

In the near future an accurate selection of patients could answer all these questions, and it might be possible that use of the buccal mucosa graft could have the upper hand over the penile flap. Recently, the theoretical advantages of the buccal mucosa graft, used as an onlay patch rather than a complete tube, were pathologically demonstrated³³. The great elasticity and ready availability of the buccal mucosa may give rise to numerous new surgical techniques, arranging the graft in an original fashion, by using the incision of the urethral plate¹⁷, and its augmentation, as suggested for childhood hypospadias surgery^{18,19}. In the past years literature seemed to support the soundness of one-stage or two-stage buccal mucosa graft urethroplasty for the successful repair of penile or bulbar urethral strictures. We realise, however, that a longer follow-up is mandatory to determine the long-term results and morbidity over time, and to find other potential applications of these surgical techniques.

Finally, in the bulbar urethra anastomotic urethroplasty, dorsal augmented anastomotic urethroplasty^{5,34}, and buccal mucosa graft urethroplasty provide excellent results in the majority of patients with uncomplicated urethral strictures ranging in length from 3 to 6 cm. The graft may be used on the ventral²⁷⁻²⁹ or on the dorsal^{1,5,10,14-16} urethral surface, according to surgeon experience and preference. In patients with local adverse conditions or complex urethral strictures, the use of two-stage procedures or mesh graft urethroplasty is advisable^{5,22}.

CONCLUSION

The armamentarium of the reconstructive urethral surgeon is a continuously evolving process and requires great familiarity with new concepts and concerns. The successful management of urethral strictures demands attention, not only to surgical details, but to proce-

dures selection. No single technique is appropriate for all situations and the successful surgeon will have a repertoire of operations to choose from. Certainly, sexual function can be placed at risk by any surgery on the genitalia and dissection must avoid interference with the neurovascular supply to the penis. The use of flaps or grafts should not compromise penile length, should not cause penile chordee and certainly should not untowardly affect penile appearance. It should also be recognized that the success of urethroplasty surgery is not measured in one- or in five-year outcomes, and we are constantly reminded by late failures that there is no true substitute for the normal urethra.

REFERENCES

1. Greenwell TJ, Venn SN, Mundy AR. Changing practice in anterior urethroplasty. *BJU Int* 1999; 83: 631.
2. Andrich DE, Mundy AR. Urethral strictures and their surgical treatment. *BJU Int* 2000; 86: 571.
3. Andrich DE, Mundy AR. Surgery for urethral stricture disease. *Contemporary Urology* 2001; 13: 32.
4. Andrich DE, Mundy AR. Substitution urethroplasty with buccal mucosal-free grafts. *J Urol* 2001; 165:1131.
5. Barbagli G, Palminteri E, Lazzeri M, Guazzoni G. Anterior urethral strictures. *BJU Int* 2003; 92: 497.
6. Venn SN, Mundy AR. Urethroplasty for balanitis xerotica obliterans. *BJU* 1998; 81: 735.
7. Barbagli G, Lazzeri M, Palminteri E, Turini D. Lichen sclerosis of male genitalia involving anterior urethra. *Lancet* 1999; 354: 429.
8. Depasquale I, Park AJ, Bracka A. The treatment of balanitis xerotica obliterans. *BJU Int* 2000; 86: 459.
9. Barbagli G, Palminteri E, Lazzeri M, Turini D. Lichen sclerosis of the male genitalia. *Contemporary Urology* 2001; 13: 47.
10. Barbagli G, Selli C, Tosto A, Palminteri E. Dorsal free graft urethroplasty. *J Urol* 1996; 155: 123.
11. Barbagli G, Palminteri E, Rizzo M. Dorsal onlay graft urethroplasty using penile skin or buccal mucosa in adult bulbourethral strictures. *J Urol* 1998; 160: 1307.
12. Barbagli G, Palminteri E, Balò S, Picinotti A, Lazzeri M. Dorsal onlay graft urethroplasty. *Contemporary Urology* 2002; 14: 18.
13. Barbagli G, Palminteri E, Lazzeri M. Dorsal onlay techniques for urethroplasty. *Urol Clin N Am* 2002; 29: 389.

14. Iselin CE, Webster GD. Dorsal onlay urethroplasty for urethral stricture repair. *World J Urol* 1998; 16: 181.
15. Jordan GH.: Anterior urethral reconstruction: Concepts and concerns. *Contemporary Urology* 1998; 10: 80.
16. Andrich DE, Leach CJ, Mundy AR. The Barbagli procedure gives the best results for patch urethroplasty of the bulbar urethra. *BJU Int.* 2001; 88: 385.
17. Snodgrass W. Tubularized, incised plate urethroplasty for distal hypospadias. *J Urol* 1994; 151: 464.
18. Hayes MC, Malone PS. The use of a dorsal buccal mucosal graft with urethral plate incision (Snodgrass) for hypospadias salvage. *BJU Int.* 1999; 83: 508.
19. Asopa HS, Garg M, Singhal GG, Singh L, Asopa J, Nischal A. Dorsal free graft urethroplasty for urethral stricture by ventral sagittal urethrotomy approach. *Urology* 2001; 58(5): 657.
20. Wessels H, McAninch JW. Current controversies in anterior urethral stricture repair: free-graft versus pedicled skin-flaps reconstruction. *World J Urol* 1998; 16: 175.
21. Wessells HW, McAninch JW.: Use of free grafts in urethral stricture reconstruction. *J Urol* 1996; 155: 1912.
22. Carr LK, MacDiarmid SA, Webster GD. Treatment of complex anterior urethral stricture disease with mesh graft urethroplasty. *J Urol* 1997; 157:104.
23. Bracka A. Hypospadias repair: the two-stage alternative. *Br J Urol* 1995; 76: 31.
24. Abdel-Hakim A, Bernstein J, Teijeira J, Elhilali MM. Urethral stricture after cardiovascular surgery, a retrospective and a prospective study. *J Urol* 1983; 130: 1100.
25. Abdel-Hakim A, Hassouna M, Teijeira J, Elhilali M. Role of urethral ischemia in the development of urethral strictures after cardiovascular surgery: a preliminary report. *J Urol* 1984; 131: 1077.
26. Bamshad BR, Poon MW, Stewart SC. Effect of cardiopulmonary bypass on urethral blood flow as measured by laser doppler flowmetry. *J Urol* 1998; 160: 2030.
27. Morey AF, McAninch JW. Technique of harvesting buccal mucosa for urethral reconstruction. *J Urol* 1996; 155: 1696.
28. Kane CJ, Tarman GJ, Summerton DJ *et al.* Multi-institutional experience with buccal mucosa onlay urethroplasty for bulbar urethral reconstruction. *J Urol* 2002; 167: 1314.
29. Elliot SP, Metro MJ, McAninch JW. Long-term followup of the ventrally placed buccal mucosa onlay graft in bulbar urethral reconstruction. *J Urol* 2003; 169: 1754.
30. Coursey JW, Morey AF, McAninch JW *et al.*: Sexual outcomes of anterior urethroplasty. *J Urol* 2000; 163: 70 (abstract 306).
31. Andrich DE, Leach CJ, Dungleison N, Mundy AR. The problems of penile urethroplasty. *J Urol* 2002; 167: 84 (abstract 334).
32. Morey AF. Urethral plate salvage with dorsal graft promotes successful penile flap onlay reconstruction of severe pendulous strictures. *J Urol* 2001; 166: 1376.
33. El-Sherbiny MT, Abol-Enein H, Dawaba MS, Ghoneim MA. Treatment of urethral defects: skin, buccal or bladder mucosa, tube or patch? An experimental study in dogs. *J Urol* 2002; 167: 2225.
34. Guralnick ML, Webster GD. The augmented anastomotic urethroplasty: indications and outcome in 29 patients. *J Urol* 2001; 165: 1496.

All correspondence to be sent to:

Professor Guido Barbagli
 Centre for Urethral and Genitalia Reconstructive Surgery
 Via Fra Guittone, 2
 52100 Arezzo
 Italy

E-mail: guido@rdn.it

Web-site: www.urethralcenter.org