

Case Report

**Paratesticular Liposarcoma: What is the Best Therapeutic Strategy?**

A. Makni<sup>1</sup>, W. Rebai<sup>1</sup>, H. Azzouz<sup>3</sup>, Y Nouria<sup>2</sup>, H. Magherbi<sup>1</sup>, M. Jouini<sup>1</sup>, M. Kacem<sup>1</sup>, Z. Ben Safta<sup>1</sup>

*Departments of <sup>1</sup>General Surgery (A), <sup>2</sup>Urology, <sup>3</sup>Anatomopathology, La Rabta Hospital, Tunis, Tunisia*

**ABSTRACT**

**Introduction:** Liposarcomas are neoplasms of mesodermal origin derived from adipose tissue and correspond to 10–14% of all soft tissue sarcomas. Paratesticular liposarcoma is very rare.

**Case report:** We report a 60-year old man who presented with a left testicular tumor 20 cm in diameter. Initial incisional biopsy was reported as fibromatosis. Chest and abdominal CT scan did not show distant metastases. Through an inguinal incision orchidectomy with homolateral inguinal node dissection was performed. Histopathological examination showed a paratesticular myxoid liposarcoma. Adjuvant radiotherapy without chemotherapy was administered. The patient remains well at 11 months followup, with no evidence of recurrence.

**Conclusion:** Complete surgical extirpation reduces the risk of local recurrence. Neoadjuvant chemotherapy or radiotherapy may reduce the tumor size, thus facilitating complete excision.

**Key Words:** Paratesticular, myxoid liposarcoma.

**Corresponding Author:** Makni Amin, Departement of General Surgery 'A', La Rabta hospital, Jabbari 1007, Tunis, Tunisia, Email: aminmakni@msn.com

**Article Info:** Date received: 2 December 2010

Date accepted (after revision): 31 January 2011

**INTRODUCTION**

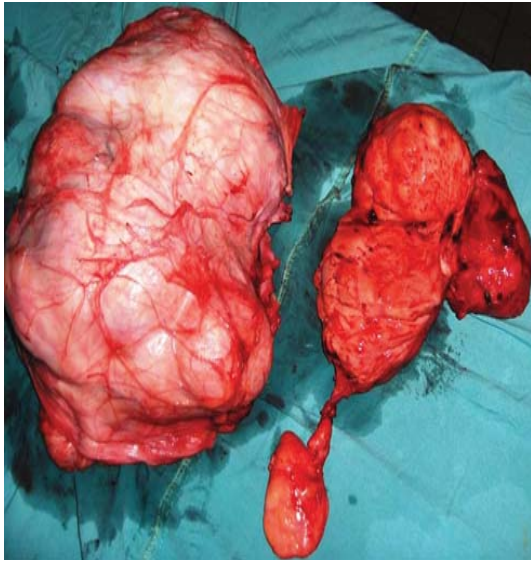Paratesticular myxoid liposarcoma is a rare tumor which includes all liposarcomas arising in the structures around the testis, including the lower end of the spermatic cord<sup>1,2</sup>. Radical orchidectomy is the recommended therapy<sup>1-3</sup>. Radiotherapy may be considered in intermediate or high-grade tumors and recurrent liposarcomas<sup>2</sup>. The role of chemotherapy remains unclear.

**OBSERVATION**

A 60-year-old man presented with a painless left inguinoscrotal swelling which had slowly increased in size over two years. The size had increased suddenly in preceding 6 weeks. On examination there

was a firm, painless mass 20 cm in longest diameter in the left scrotal-inguinal region. The left testicle could not be identified. The right testis and spermatic cord were normal. Abdominal ultrasonography, abdominal Computed Tomography (CT) and chest ultrasonography did not show distant metastases. Through an inguinal incision, orchidectomy with homolateral inguinal node dissection was performed (Fig. 1). Histopathological examination revealed a paratesticular myxoid liposarcoma (Fig. 2). Adjuvant radiotherapy without chemotherapy was administered. The patient remains well 11 months followup, with no evidence of recurrence.

## PARATESTICULAR LIPOSARCOMA



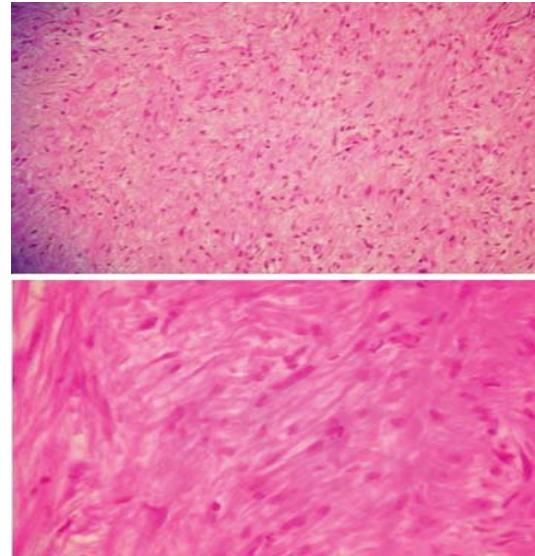
**Figure 1:** Surgical specimen consisting of a large tumor adjacent to the left testicle.

### DISCUSSION

---

Liposarcomas are soft tissue sarcomas that originate from adipose tissue. These tumors represent lesser than 1% of all malignant tumors<sup>4, 5</sup>. Paratesticular liposarcoma has been rarely reported in the literature<sup>1-3</sup>. In the retrospective study of 30 cases of paratesticular liposarcoma reported by Montgomery et al, the average patient age was 63 years, the average tumor size was 11 cm and only one patient had a myxoid type liposarcoma. Our patient who was 60-years old at presentation had a testicular tumor of 20 cm in diameter which was a myxoid liposarcoma.

Complete surgical resection through an inguinal incision offers the best chance of cure and prevention of local recurrence<sup>3,6,7</sup>. However, orchidectomy via transscrotal incision is to be condemned because it risks the implantation of neoplastic cells in the scrotal skin, thus increasing the potential area of lymph node metastases.



**Figure 2:** Histopathological examination.

**Above:** The stroma shows a characteristic plexiform arrangement of capillaries as well as abundant myxomatous matrix. (HE x 40).

**Below:** Higher magnification shows high mitotic activity with numerous abnormal nuclei. Many cells are lipoblasts containing cytoplasmic lipid vacuoles which indent the nucleus or displace it to an eccentric position (HE x 200).

Mesodermal tumors in general and liposarcomas in particular are known to be radioresistant and chemoresistant<sup>8</sup>. However, radiation has shown favorable results in some studies<sup>9</sup>. For this reason we used adjuvant radiotherapy in our patient. It is not known whether neoadjuvant chemotherapy could reduce tumor bulk, thus facilitating subsequent surgical excision.

In a study of 22 genitourinary sarcomas published by Mondaini et al<sup>3</sup>, adverse prognostic factors were testicular location of the tumor, size exceeding 5 cm and poor histological differentiation.

### CONCLUSION

---

Paratesticular myxoid liposarcoma is a rare tumor. The best treatment is radical orchidectomy with wide margins through an inguinal incision. The value of adjuvant radiotherapy and chemotherapy remains unproven.

# PARATESTICULAR LIPOSARCOMA

## REFERENCES

---

1. Montgomery E, Fisher C. Paratesticular liposarcoma: A clinicopathologic study. *Am. J. Surg. Pathol.* 2003; Jan; 27 (1): 40-7.
2. Ozkara H, Ozkan B, Alici B, Onal B, Durak H, Talat Z. Recurrent paratesticular myxoid liposarcoma in a young man. *J.Urol.* 2004; Jan; 171 (1): 343.
3. Mondaini N, Palli D, Saieva C, Nesi G, Franchi A, Ponchietti R, et al. Clinical characteristics and overall survival in genitourinary sarcomas treated with curative intent: A multicenter study. *Eur. Urol.* 2005; 47 (4): 468-73.
4. Kilkenny III JW, Bland KI, Copeland III EM. Retroperitoneal sarcoma: The University of Florida experience. *J.Am.Coll.Surg.* 1996; 182 (4): 329-39.
5. Hassan I, Park SZ, Donohue JH, Nagorney DM, Kay PA, Nasciemento AG, et al. Operative management of primary retroperitoneal sarcomas: A reappraisal of an institutional experience. *Ann. Surg.* 2004; Feb; 239 (2): 244-50.
6. Ugwumba FO, Nnabugwu I, Nnakenyi EF, Olusina DB, Ajuzieogu O. Giant Seminoma following ipsilateral orchidectomy: A rare finding. Case report. *Eur. J. Cancer Care.* 2009; 18 (3): 322-4.
7. Rowland RG, Herman JR. Tumours and infectious diseases of the testes, epididymis and scrotum. In: Gillenwater JY, Grayhack JT, Howards SS, Mitchell ME, editors. *Adult and pediatric urology.* 4th ed. Philadelphia: Lippincott Williams and Wilkins; 2002.
8. Keizer HJ, Crowther D, Nielsen OS, Van Oosterom AT, Muguiro JH, Van Pottelberghe C, et al. EORTC Group Phase II Study of oral etoposide for pretreated soft tissue sarcoma. *Sarcoma.* 1997; 1 (2): 99-101.
9. Alkis N, Muallaoglu S, Koçer M, Arslan ÜY, Durnali AG, Tokluoglu S, et al. Primary adult soft tissue sarcomas: Analysis of 294 patients. *Med.Oncol.* 2011; 28: 391-6.