

Case Report

Primary Renal Leiomyosarcoma: Case Report and Literature Review

G. S. Bhat, G. G. Nelivigi, M. Shivalingaiah and C. S. Ratkal

Department of Urology, Institute of Nephrourology, Bangalore, India

ABSTRACT

Primary leiomyosarcoma of the kidney is extremely rare. The management is unclear due to the limited literature on the subject. The diagnosis should be considered when imaging shows a relatively hypovascular tumor involving one renal pole, with atypical features on microscopy. We report a renal leiomyosarcoma in a 68 year old man, who underwent right radical nephrectomy. A tumor-free surgical margin is the most important prognostic factor. Although various modalities of adjuvant treatment have been tried, the overall prognosis is poor as the tumor is highly aggressive.

Key Words: primary leiomyosarcoma, radical nephrectomy, tumor free surgical margin

Corresponding Author: Dr. Gajanan S. Bhat, 186/25, 10th B Main, First Block, Jayanagar, Bangalore-11, Karnataka, India, Email: gajubhatru@yahoo.co.in

Article Info : Date received: 31/12/2010

Date accepted (after revision): 10/2/2011

INTRODUCTION

Primary sarcomas of the kidney are very rare and comprise around 1.1% of all renal tumors¹. Among the sarcomas, leiomyosarcoma is the commonest (50-60%) and has the worst prognosis². The management of renal leiomyosarcoma is unclear due to the limited literature on the subject. As the prognosis is distinctly different from renal cell carcinoma, it is important to consider the diagnosis in case of a renal mass with atypical clinical or histological features.

CASE REPORT

A 68 year old man presented with dull aching pain in the right hypochondrium of one month duration. Ultrasound imaging revealed an irregular right upper pole renal mass of 6.3 x 4.8 cm. No associated comorbidities were found. Clinical examination was unremarkable except for an enlarged, firm, non-tender prostate. Haematological investigations, urine examination and renal function tests were normal. Contrast Enhanced

Computed Tomography (CECT) of the abdomen and pelvis revealed a heterogeneous minimally enhancing mass 5.6 x 5.1 x 5.2 cm in the upper pole of the right kidney with no evidence of metastases (Fig. 1). Magnetic resonance imaging (MRI) revealed medial deviation of the inferior vena cava without intracaval thrombus or infiltration of its wall (Fig. 2).

The patient underwent right radical nephrectomy. Intra operatively, dense adhesions were found between the tumor mass and the duodenum, inferior surface of the liver and inferior vena cava, which were dissected so that the specimen could be delivered in toto. Macroscopically the tumor arising from the renal capsule was well circumscribed with areas of necrosis and hemorrhage and compression of adjacent normal renal parenchyma. Microscopy revealed features suggestive of high-grade sarcoma with prominent nucleoli, intranuclear inclusions and atypical mitoses at the rate of 0-1 per high-power field (Fig. 3).

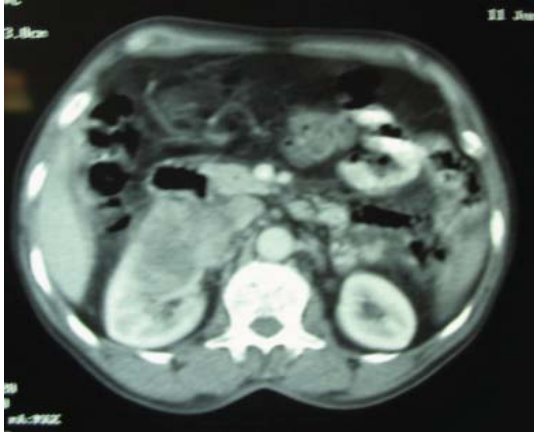


Fig. 1 a: Tumour in the right kidney which is indistinguishable from renal cell carcinoma.

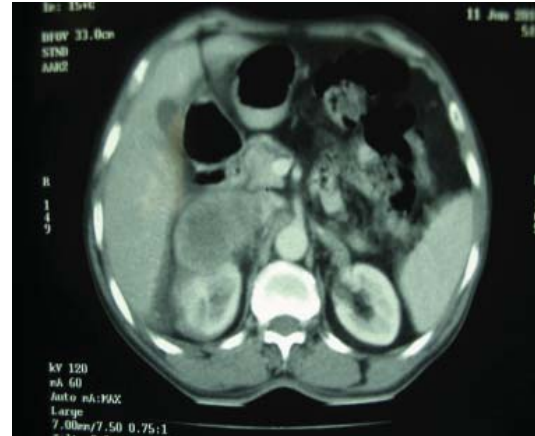


Fig. 1 b: Right renal upper pole tumour with pointer showing compressed inferior vena cava.

The resection margins were negative. Immunohistochemistry revealed strong positivity to Smooth Muscle Actin (SMA) and desmin in 90% of the cells and positivity to cytokeratin in 10% of the cells, but was negative for CD-117, CD-34 and S-100. At 3 months' followup the patient had no recurrence or metastases.

DISCUSSION

Leiomyosarcoma is an extremely rare renal neoplasm, but is the commonest type of renal sarcoma. It arises from the capsule and has a worse prognosis compared to other genitourinary sites especially if the tumor has breached Gerota's fascia^{2,3}. Most often the tumor is diagnosed on histology and the clinical diagnosis in such cases is almost always renal cell carcinoma⁴. The following CT and angiographic features suggest the diagnosis of renal sarcoma⁵:

1. Tumor that originates from the renal capsule or renal sinus
2. Lack of extension of the mass beyond its capsule
3. Fatty density of the mass in cases of liposarcoma
4. Vascular pattern: irregular tortuous tumor vessels without pooling of contrast material or arteriovenous shunting, sparse neovascularity in leiomyosarcoma.

The staging of the primary tumor is based on its size and histological grade⁶. The grading is based on the degree of differentiation, grade 1 being well differentiated and grade 4 being undifferentiated. Based on its location, the tumor is classified as either superficial or deep in relation to the body surface. As renal tumors fall in the deep category, they are stage I when the histological grade is 1-2, stage III when the histological grade is 3-4 and stage IV when there are metastases.

The treatment of choice is radical nephrectomy and the most important prognostic factor is a tumor free resection margin^{2,7}. Macroscopically the tumor is a well circumscribed, fleshy lesion with areas of necrosis, hemorrhage and cystic degeneration⁸. Histopathological indicators of poorer prognosis are necrosis, nuclear pleomorphism, and more than rare mitotic figures⁹. Irrespective of the findings on histopathology, overall prognosis appears poor with average survival reported as 8 months post diagnosis in case of invasive disease and incomplete resection¹⁰. Hence it is important that the tumor be removed in toto and a negative resection margin be achieved. Adjuvant radiotherapy, chemotherapy and hormonal treatment do not appear to alter the clinical course¹¹.

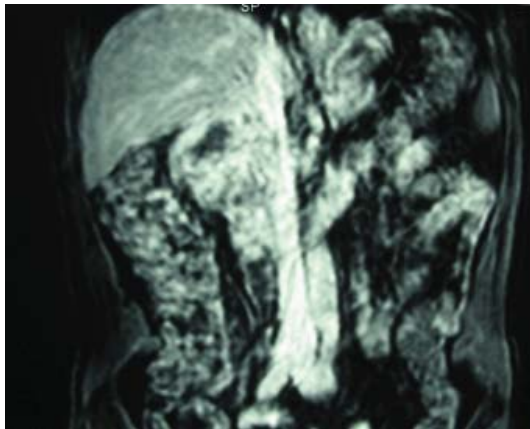


Fig. 2: MRI showing tumour compressing inferior vena cava.

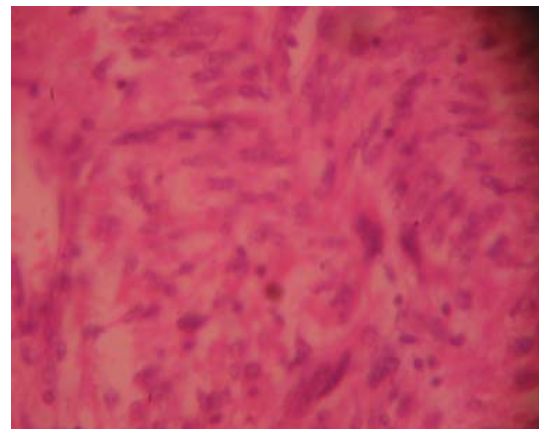


Fig. 3: Microscopy of the tumour (H and E stain, magnification x100).

CONCLUSION

Leiomyosarcoma is an extremely rare malignancy arising from the renal capsule, but the diagnosis should be considered in a renal polar tumor. It is important to achieve a negative resection margin as it is the only factor conferring a better prognosis in this aggressive disease. Although various adjuvant therapeutic modalities have been described, none appear to alter the clinical course of the disease.

ACKNOWLEDGEMENTS

We acknowledge the services of Dr. Sujataha Siddappa, Pathologist, Institute of Nephrourology, Bangalore, Karnataka, India for histopathology & Dr. Clementina Ramarao, Department of Pathology, Kidwai Memorial Institute of Oncology, Bangalore, Karnataka, India for immunohistochemistry.”

REFERENCES

1. Granmayeh M, Wallace S, Barrett AF, Fisher R, Heslep JH. Sarcoma of the kidney: Angiographic features. *AJR Am.J.Roentgenol.* 1977; Jul;129(1):107-12.
2. Demir A, Yazici CM, Eren F, Türkeri L. Case report: Good prognosis in leiomyosarcoma of the kidney. *Int. Urol.Nephrol.* 2007;39(1):7-10.
3. Sharma D, Pradhan S, Aryya NC, Shukla VK. Leiomyosarcoma of kidney: A case report with long term result after radiotherapy and chemotherapy. *Int. Urol.Nephrol.* 2007;39(2):397-400.
4. Moazzam M, Ather MH, Hussainy AS. Leiomyosarcoma presenting as a spontaneously ruptured renal tumor-case report. *BMC Urol.* 2002; Nov 19;2:13.
5. Shirkhoda A, Lewis E. Renal sarcoma and sarcomatoid renal cell carcinoma: CT and angiographic features. *Radiology.* 1987; Feb;162(2):353-7.
6. Greene FL, Page DL, Fleming ID, Fritz A, Balch CM, Haller DG, et al. *AJCC cancer staging manual.* 6th ed. New York: Springer; 2002.
7. Todd CS, Michael H, Sutton G. Retroperitoneal leiomyosarcoma: Eight cases and a literature review. *Gynecol.Oncol.* 1995; Dec;59(3):333-7.
8. Farrow GM, Harrison EG,Jr, Utz DC. Sarcomas and sarcomatoid and mixed malignant tumors of the kidney in adults. *Cancer.* 1968; Sep;22(3):556-63.
9. Grignon DJ, Ayala AG, Ro JY, el Naggar A, Papadopoulos NJ. Primary sarcomas of the kidney. A clinicopathologic and DNA flow cytometric study of 17 cases. *Cancer.* 1990; Apr 1;65(7):1611-8.
10. Miller JS, Zhou M, Brimo F, Guo CC, Epstein JI. Primary leiomyosarcoma of the kidney: A clinicopathologic study of 27 cases. *Am.J.Surg.Pathol.* 2010;34(2):238-42.
11. Weissman MJ, Gaeta JF, Albert DJ. Childhood urogenital sarcoma. *J.Surg.Oncol.* 1972;4(2):109-16.