

## Point of Technique | Endoscopic Resection of a Prominent Median Lobe During TURP: a Simple Technique to Avoid Sub-Trigonal Resection

A. A. Attia<sup>1</sup> and M. T. ABD AL-HAK<sup>2</sup>

<sup>1</sup>Department of Urology, Ahmed Maher Teaching Hospital, Cairo, Egypt and <sup>2</sup>Department of Radiology, AL-Zahraa University Hospital, AL-Azhar University (Girls), Cairo, Egypt

**Key Words:** Benign prostatic hyperplasia, surgery, Transurethral resection of prostate, Endoscopic resection, prominent median lobe

**Corresponding Author:** Dr. Abd El-Wahid Attia, Urology Department, Ahmed Maher Teaching Hospital, Cairo, Egypt, Email: draymanattia@gmail.com

**Article Info :** Date received: 6/3/2010

Date accepted (after revision): 1/4/2010

### INTRODUCTION

During transurethral resection of the prostate (TURP) especially in cases of BPH with a very large obstructing adenoma, it is preferable to start by resection of the median lobe<sup>1</sup>. Once the median lobe has been adequately resected, we have to respect the bladder neck (BN) as a proximal limit of resection. Additional tissue resection from the BN is often tempting. However, this maneuver may result in undermining the trigone and inadvertent resection of one or both ureteral orifices<sup>1</sup>. A midline incision through the raised edge of the BN with Colling's knife (Fig. 1) has been described to separate the BN fibers, open the passage and avoid ureteral injury<sup>2</sup>.

Herein we present a simple and safe technique for resecting a prominent median lobe.

### DESCRIPTION OF THE METHOD

A longitudinal deep incision is made with a Colling's knife in the cleft between each lateral lobe and the median lobe. The incision is deepened until the prostatic capsular fibers are exposed (Fig. 2). A transverse incision is then made starting 5mm. above the vesico-prostatic junction and extending medially from the cleft on one side to the mid-point

of the vesico-prostatic junction (Fig. 3). Resection is then performed with the standard loop (24 Fr). Resection of the prominent part of the median lobe is started at the floating part and is terminated by resecting the fixed part (Fig. 3). Resection of the remaining part of the median lobe is performed as the last step of the procedure (Fig. 4).

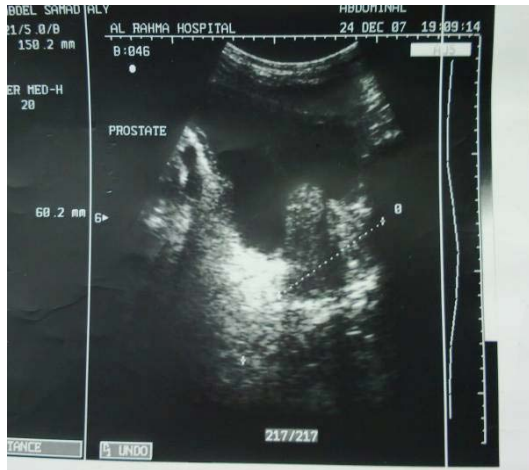### PATIENTS

Between January 2008 and December 2009 we performed this technique in 32 TURP patients with a prominent median lobe. The result was successful adequate resection, without any sub-trigonal extension.

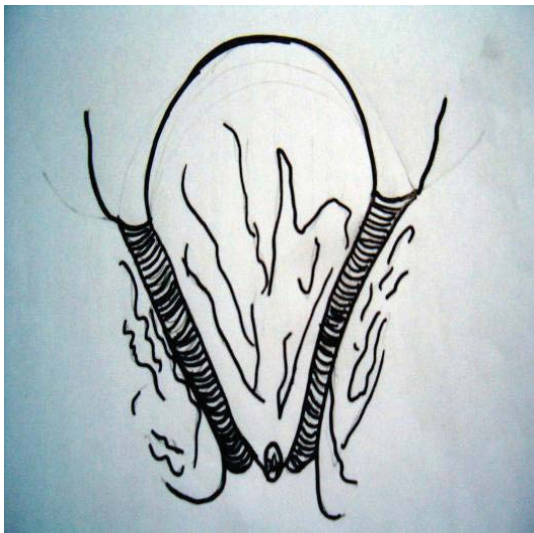
### DISCUSSION

In our study, the deep incision on both sides of the median lobe aims at cutting off much of the blood supply, which comes from the penetrating periurethral prostatic branches of the inferior vesical artery at the bladder neck<sup>3</sup>. Median lobe resection of the prominent part should be performed first to allow irrigation and passage of prostatic chips into the bladder<sup>1</sup>. If a complete transverse incision of the prominent part of the median lobe is performed, the surgeon will be confronted

## Endoscopic resection of a prominent median lobe in TURP



**Fig. 1:** Post TURP residual median lobe.

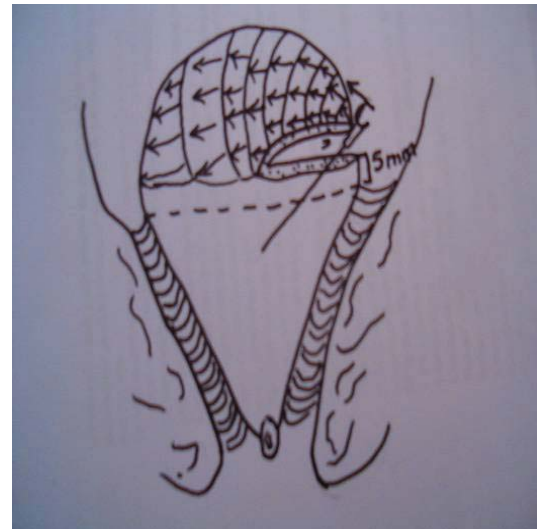

**Fig. 2:** Deep cut down to the capsule.

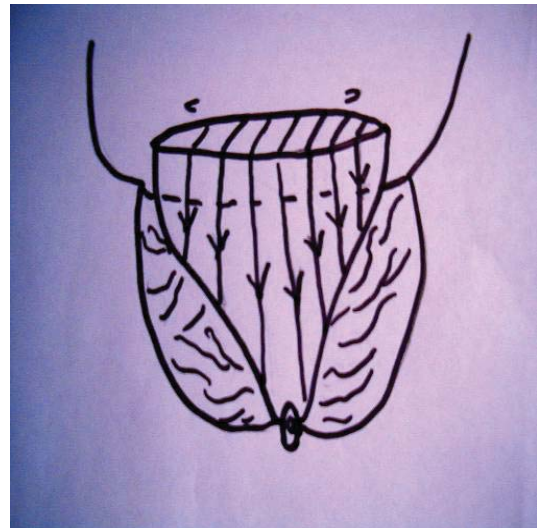
with a huge and bulky floating piece, which is difficult to evacuate through the endoscope sheath. If resection of the remaining part of the median lobe is postponed to the end of the procedure, this provides BN support and avoids unnecessary BN injury and sub-trigonal extension.

### REFERENCES

1. Mebust WK, Holtgrewe HL, Cockett AT, Peters PC. Transurethral prostatectomy: Immediate and postoperative complications. A cooperative study of 13 participating institutions evaluating 3,885 patients 1989. *J.Urol.* 2002; Feb;167(2 Pt 2):999,1003; discussion 1004.



**Fig. 3:** Resection of the floating part is followed by resection of the fixed one.



**Fig. 4:** The remaining adenoma is resected at the end of the procedure.

2. Kulb TB, Kamer M, Lingeman JE, Foster RS. Prevention of post-prostatectomy vesical neck contracture by prophylactic vesical neck incision. *J.Urol.* 1987; Feb;137(2):230-1.
3. Flocks RH. The arterial distribution within the prostatic gland: Its role in transurethral prostatic resection. *J.Urol.* 1937;37:524-48.