

Original article

Accuracy of Ultrasound Diagnosis after Blunt Scrotal Trauma (10 Years Experience)

O. A. Abd Elkader, A. El Nashar and K. Mohy El Den

Department of Urology, Suez Canal University Hospital, Ismailia, Egypt

ABSTRACT

Objectives: To evaluate the role of ultrasonography (US) and its accuracy, sensitivity and specificity for the diagnosis of testicular rupture after blunt scrotal trauma. Moreover, tunica albuginea breach, testicular hematoma, testis avulsion, epididymal injuries and hematocele are particularly examined.

Patients and Methods: Between 1998 and 2008, 24 patients presented to Suez Canal University Hospital after blunt scrotal trauma and underwent surgical exploration. All patients had an emergency scrotal US examination with the use of a 7.5-10 MHz linear transducer. US findings were compared with the surgical findings to calculate the sensitivity and specificity of US for each type of lesion.

Results: Out of 24 patients, 12 were diagnosed as having testicular rupture and tunica albuginea breach was visualized on US in 6 patients. Sensitivity and specificity of US were 92% and 50% for testicular rupture, 85% and 75% for hematocele, 80% and 79% for testicular hematoma, and 100% and 96% for testicular avulsion, respectively. US diagnosis of epididymal injuries was poor as it failed to detect 3 out of 5 epididymal lesions.

Conclusion: US was highly sensitive in the diagnosis of testis rupture. This can provide information on the integrity of the scrotal contents that can help the physician to determine the optimal treatment.

Key Words: Ultrasonography, scrotal blunt trauma, testis rupture

Corresponding Author: Dr. Osman Abd El Kader, Suez Canal University, Faculty of Medicine, Department of Urology, Ismailia, Egypt, EMail: osman3247@yahoo.Com

Article Info : Date received: 3/5/2010

Date accepted (after revision): 11/8/2010

INTRODUCTION

Patients presenting with scrotal trauma are often difficult to examine clinically due to the painful condition and the presence of a tender scrotal swelling. Although testicular trauma is not life-threatening, testicular loss may impair fertility, contribute to hypogonadism and affect social confidence.

Due to the high incidence of testicular rupture after blunt scrotal trauma (up to 50%)¹, early diagnosis and operative intervention are important to achieve high testicular salvage rates.

Ultrasonography (US) has become an extension of the clinical examination in

assessing the integrity of the testes; as the finding of parenchymal heterogeneity may indicate intratesticular hematoma² while loss of continuity of the tunica indicates testicular rupture^{3,4}.

Blunt scrotal trauma presents a diagnostic dilemma because immediate operative exploration is not necessarily indicated. Difficult scrotal examination can prevent detection of testicular rupture, an oversight that can lead to complications⁵.

Previously blunt scrotal trauma was managed conservatively and surgical intervention was undertaken only after the

development of complications⁶. However, early exploration and repair may reduce complications and hospitalization⁷. One study reported that the probability of testicular salvage after blunt trauma decreased from 80% to 32% if exploration was done within 3 days⁸. Other studies reported a rate of testicular salvage of 90% when exploration was performed within 3 days and only 45% when surgery was delayed for more than 3 days^{9, 10}.

While scrotal US is usually readily available, reliable and inexpensive, it is the most operator-dependent imaging technique, and its limitations should be remembered. The level of experience of the sonographer, the completeness of the examination and the criteria used for evaluation are all potential confounding variables⁶.

The objective of our study was to compare US and surgical findings in 24 patients who presented with blunt scrotal trauma to the emergency unit in Suez Canal University Hospital in a 10-year period. The accuracy, sensitivity and specificity of US for the diagnosis of testicular rupture, tunica albuginea breach, testicular hematoma, testicular avulsion, epididymal injuries and hematocele were particularly evaluated.

PATIENTS AND METHODS

A retrospective study of 24 patients who presented with blunt scrotal trauma to our emergency unit between 1998 and 2008 was performed. Assessment included clinical history, cause of injury and time before presentation. Thorough clinical examination of each patient was performed. Testicular rupture was suggested if there were extreme testicular tenderness and pain during physical examination. Hematocele was considered if there was a tense, tender scrotal mass without light transmission and the underlying testis was impalpable or indistinct.

Scrotal US was performed using a high-resolution linear transducer (Siemens Sonoline Sienna Ultrasound Imaging System, Siemens Medical Systems, Inc., Ultrasound

Group, Federal Republic of Germany) which has computerized software and a 7.5-10 MHz scanner probe (color B-mode imager and pulsed Doppler unit with real-time spectrum analysis).

Results were reviewed by a urologist. Severe injuries of the scrotal contents like testicular rupture were diagnosed based on the presence of a single sonographic finding of a heterogenous echopattern of the testicular parenchyma or loss of its contour definition. Intratesticular hematoma was diagnosed as a focal area of altered echogenicity within the testis with no internal flow on color Doppler and preservation of the ovoid shape in multiple planes^{11, 12}. Hematocele was characterized by an extratesticular collection within the tunica vaginalis with low-level echoes¹³. Enlargement of the epididymis may suggest either an epididymal hematoma or post-traumatic epididymitis⁶.

Surgical exploration was performed by transverse scrotal incision and rarely by median longitudinal incision (if the contralateral testis required exploration). The wound was copiously irrigated with saline for removal of the scrotal hematoma, then complete exposure of the testis, epididymis and spermatic cord was performed. Testicular parenchyma that extruded through a rupture of the tunica albuginea was examined, necrotic testicular parenchyma was removed and the tunica albuginea was sutured without tension. Orchidectomy was performed if the tunica was disrupted with macerated parenchyma. Post-operative follow-up was obtained after two weeks. The medical records were reviewed, comparing clinical, US and surgical findings. Calculation of the sensitivity and specificity of US for each type of injury was done.

RESULTS

The mean patient age was 28 (range 17-78) years and the mean time between trauma and presentation was 8 (range 1-96) hours. The causes of blunt scrotal trauma are shown in Table 1.

Table 1: Causes of blunt scrotal injuries

Injuries	N	%
Assault	11	46%
Motor vehicle accident	8	33%
Sport related	3	12,5%
Fall from a height	2	8,5%

Table 2: Clinical, ultrasonographic and surgical findings of scrotal injuries

Lesion	Clinical finding	US finding	Surgical finding
Hematocele	6	18	20
Testicular rupture	0	17	12
Tunica albuginea breach	0	9	11
Testicular hematoma	0	8	5
Epididymal injury	0	5	4
Testicular avulsion	0	2	1

All patients underwent scrotal surgical exploration after clinical and US examination. Hematocele was suggested by US in 18 of the 24 patients, while surgical exploration revealed 20 cases, with 2 false negative results, giving a sensitivity and specificity of 85% and 75%, respectively. Testicular rupture was diagnosed on US in 17 cases, while surgery confirmed 12 cases, with 5 false positive results, giving a sensitivity and specificity of 92% and 50%, respectively. Salvage management was performed in 11 cases and only one orchidectomy was done in a case of severely macerated parenchyma with extensive necrosis. Tunica albuginea breach was diagnosed on US in 9 cases, while surgical exploration revealed 11 cases, with 2 false negative results, giving a sensitivity and specificity of 73% and 92%, respectively. Rupture of the tunica was repaired with continuous sutures without tension.

Testicular hematoma with intact tunica albuginea was diagnosed on US in 8 cases and at surgical exploration in 5 patients. The hematoma was evacuated with repair of the

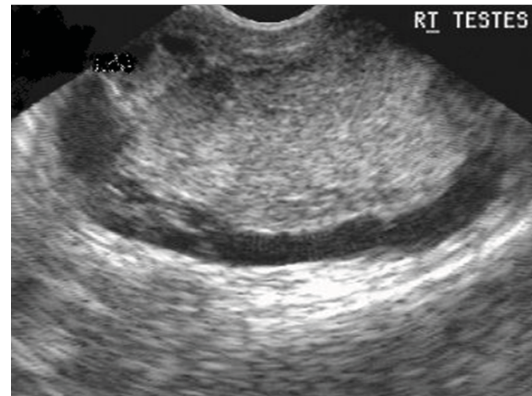


Fig. 1 A: Scrotal US of blunt trauma shows severe heterogenous echo pattern of the testicular parenchyma in a patient who underwent early exploration.

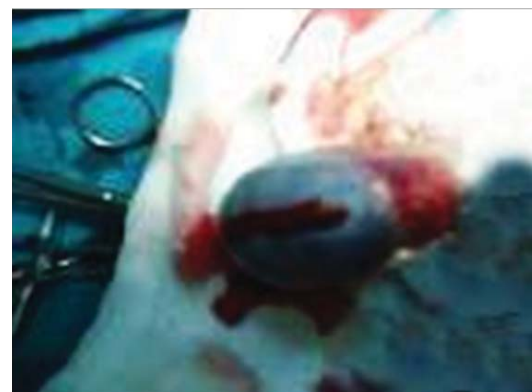

Fig. 1 B: Early surgical exploration - tunica albuginea incised for evaluation of intratesticular hematoma.

tunica without tension. With 3 false positive cases the sensitivity and specificity of US were 80% and 79%, respectively.

Epididymal injuries were suspected on US in 5 patients and proved at surgical exploration in 4 patients, with sensitivity and specificity of 75% and 79%, respectively. Testicular avulsion was diagnosed on US in two patients and confirmed at surgery in one, giving a sensitivity and specificity of 80% and 79%, respectively. During operation one case was found to be testicular torsion, and orchidopexy was performed.

Clinical and US findings are compared with surgical results in Table 2, and the calculated accuracy of US is shown in Table 3.

At follow-up 4 patients presented with persistent scrotal pain. Testicular atrophy despite early surgical intervention was diagnosed in 3 of these patients – two had severe testicular injury and one had severe epididymal rupture at the time of surgical exploration.

Figure 1 shows the results of early exploration with preservation of testicular tissues. Figure 2 shows the results of delayed exploration which ended in orchidectomy.

Table 3: Accuracy of US examination when compared with surgical findings.

US finding	Sensitivity	Specificity	PPV	NPV
Hematocele	85%	75%	94%	50%
Testicular rupture	92%	50%	65%	86%
Tunica albuginea breach	73%	92%	89%	80%
Testicular hematoma	80%	79%	50%	94%
Epididymal injury	75%	79%	50%	94%
Testicular avulsion	100%	96%	50%	100%

PPV = positive predictive value

NPV= negative predictive value

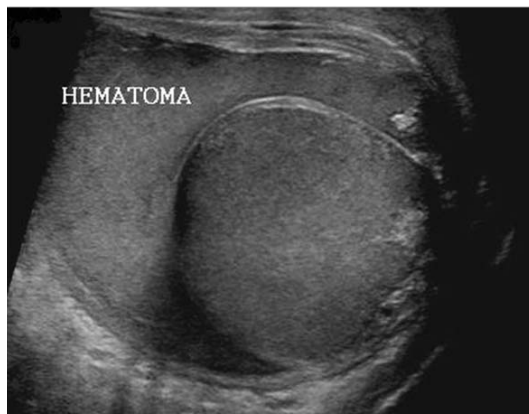

Fig. 2A: Scrotal US of blunt trauma shows mild intratesticular hematoma in a patient who underwent delayed exploration.

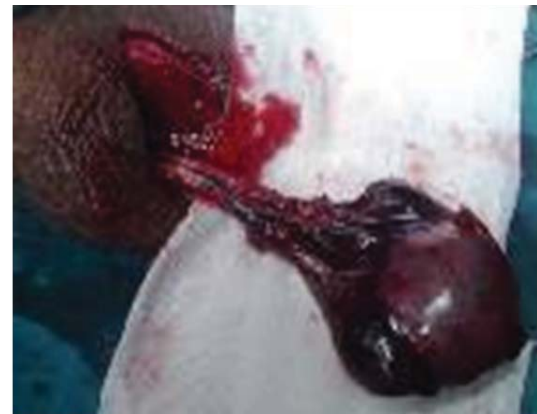

Fig. 2C: Delayed Gangrenous testis (non-viable).

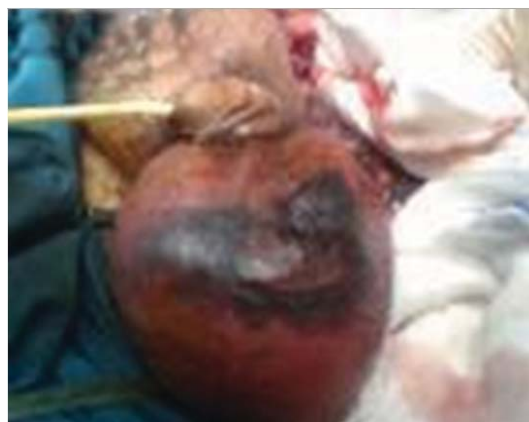

Fig. 2B: Delayed exploration with gangrenous scrotal skin.

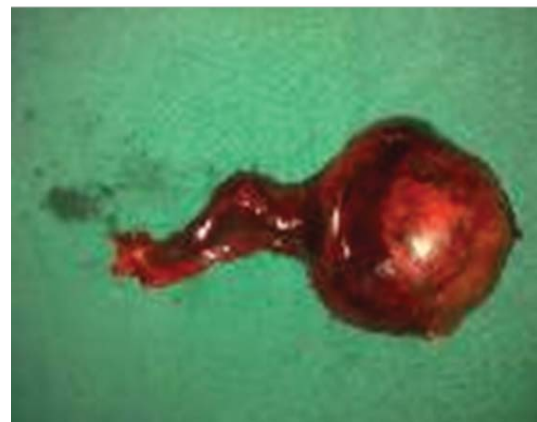


Fig. 2D: Operative orchidectomy specimen.

DISCUSSION

In this study, damage to the scrotal contents after blunt trauma varied from intratesticular hematoma to severe testicular rupture or testicular avulsion. Clinical examination is often limited because of scrotal pain and swelling which usually leads to misdiagnosis of severe injuries, especially testicular rupture. Our study revealed the poor accuracy of clinical examination for the diagnosis of testicular or epididymal injury. Misdiagnosis has been demonstrated to increase the orchidectomy rate and long-term morbidity such as testicular atrophy and infertility^{1,14}.

Early surgical intervention has been recommended by several authors, as this reduces complication rates and hospitalization and increases testicular salvage rates from 32-45% to 80-90%⁷⁻¹⁰.

In this study the highest sensitivity and specificity of US was for testicular avulsion (100% and 96%, respectively), similar to previously reported results^{5,15,16}. US was also of value in the diagnosis of hematocele, tunica albuginea breach and testicular hematoma, with good sensitivity and specificity (Table 3).

In spite of the high sensitivity of US for the diagnosis of testicular rupture, conservative management of hematocele or intratesticular hematoma can result in infection, chronic pain and testicular atrophy^{1,14,17,18}. Thus early surgical exploration is recommended to reduce morbidity and to preserve testicular parenchyma and function⁷⁻¹⁰.

CONCLUSIONS

US is highly sensitive in the diagnosis of testicular avulsion, testicular rupture, hematocele and testicular hematoma. US in blunt scrotal trauma can provide information on the integrity of the scrotal contents which can help the physician to determine the optimal treatment.

REFERENCES

1. Cass AS, Luxenberg M. Testicular injuries. *Urology*. 1991; Jun;37(6):528-30.
2. Fournier GR,Jr, Laing FC, Jeffrey RB, McAninch JW. High resolution scrotal ultrasonography: A highly sensitive but nonspecific diagnostic technique. *J.Urol*. 1985; Sep;134(3):490-3.
3. Herbener TE. Ultrasound in the assessment of the acute scrotum. *J.Clin.Ultrasound*. 1996; Oct;24(8):405-21.
4. Wessells H, McAninch JW. Testicular trauma. *Urology*. 1996; May;47(5):750.
5. Buckley JC, McAninch JW. Diagnosis and management of testicular ruptures. *Urol.Clin.North Am*. 2006;33(1):111-6.
6. Morey AF, Metro MJ, Carney KJ, Miller KS, McAninch JW. Consensus on genitourinary trauma: External genitalia. *Br.J.Urol*. 2004;94:507-11.
7. McCormack JL, Kretz AW, Tocantins R. Traumatic rupture of the testicle. *J.Urol*. 1966;96:80-3.
8. Gross M. Rupture of the testicle: The importance of early surgical treatment. *J.Urol*. 1969; Feb;101(2):196-7.
9. Jeffrey RB, Laing FC, Hricak H, McAninch JW. Sonography of testicular trauma. *AJR Am.J.Roentgenol*. 1983; Nov;141(5):993-5.
10. Lupetin AR, King W,3rd, Rich PJ, Lederman RB. The traumatized scrotum. Ultrasound evaluation. *Radiology*. 1983; Jul;148(1):203-7.
11. Ragheb D, Higgins JL,Jr. Ultrasonography of the scrotum: Technique, anatomy and pathologic entities. *J.Ultrasound Med*. 2002; Feb;21(2):171-85.
12. Kratzik C, Hainz A, Kuber W, Donner G, Lunglmayr G, Frick J, et al. Has ultrasound influenced the therapy concept of blunt scrotal trauma? *J.Urol*. 1989; Nov;142(5):1243-6.
13. Berman JM, Beidle TR, Kunberger LE, Letourneau JG. Sonographic evaluation of acute intrascrotal pathology. *AJR Am.J.Roentgenol*. 1996; Apr;166(4):857-61.
14. Cross JJ, Berman LH, Elliott PG, Irving S. Scrotal trauma: A cause of testicular atrophy. *Clin.Radiol*. 1999; May;54(5):317-20.
15. Guichard G, El Ammari J, Del Coro C, Cellarier D, Loock PY, Chabannes E, et al. Accuracy of ultrasonography in diagnosis of testicular rupture after blunt scrotal trauma. *Urology*. 2008;71(1):52-6.
16. Micallef M, Ahmad I, Ramesh N, Hurley M, McNerney D. Ultrasound features of blunt testicular injury. *Injury*. 2001; Jan;32(1):23-6.

17. Cass AS, Luxenberg M. Value of early operation in blunt testicular contusion with hematocele. J.Urol. 1988; Apr;139(4):746-7.
18. MacDermott JP, Gray BK, Stewart PA. Traumatic rupture of the testis. Br.J.Urol. 1988; Aug;62(2):179-81.

Editorial Comment

Blunt scrotal trauma accounts for almost 25% of urologic injuries due to blunt forces. Up to 85% of testicular injuries are due to blunt trauma. Injuries can vary from scrotal hematoma, hematocele, testicular rupture and injury to the cord structures. As pointed out in the article by Elkader et al, clinical exam can be difficult to differentiate. Ecchymosis, scrotal swelling and tenderness may confound the ability to perform an accurate exam of the testicular integrity. Scrotal ultrasonography has been shown to be helpful in those patients with equivocal exam findings. The trend in the last few decades has been for early exploration, which has shown testicular salvage rates close to 90% when preformed within 3 days of injury.

This article by Elkader et al represents a significant single center experience in managing blunt scrotal trauma. The authors describe 24 patients with blunt scrotal trauma with an algorithm that includes careful history and exam, as well as scrotal ultrasound. They looked at the predictive values of ultrasound findings compared to results of surgical exploration. For testicular rupture, they show a sensitivity of 92%, which is significantly greater than what has been published in previous reports. A similar result was found with their PPV. Interestingly, their specificity of 65% was much lower than in other reports, as well as their NPV. I believe this demonstrates the significant operator dependency of this imaging modality.

This study does provide interesting and informative data on potential evaluation modalities for clinicians who have patients with these injuries, which routinely can have difficult exams. Our feelings are that mechanism of injury and any abnormal exam findings should guide the decision for exploration. It is our practice to explore all patients with suspicious history for potential testicular injury, as well as any scrotal swelling or ecchymosis within 24 hours of injury. We reserve the use of diagnostic ultrasonography if the history is questionable or the exam is normal. My other indication for using ultrasound is merely convenience. If we know there will be some delay in getting the patient to the operating room, we will often request an ultrasound to confirm our suspicions. But because of the low specificity, poor NPV, and intraoperator dependency, I rarely let the ultrasound findings guide my decision for surgery. Clearly the literature supports early exploration for testicular salvage. IF the history and exam are suspicious enough, acquiring an additional study may only delay further. The consequences of having negative findings on scrotal exploration are minimal.

I would use the data in this well written study as a guide for those physicians that are prone to conservative management, or those patients with suspect history and normal exams.

Charles D. Best, MD, FACS
Asst. Professor of Urology and Surgery
Chief of Service, Urology
Director of Urologic Trauma Service
LAC+USC County Medical Center
USC Institute of Urology
Los Angeles, CA USA