

Case Report

Circumcaval Ureter with Synchronous Ipsilateral Transitional Cell Carcinoma of the Renal Pelvis and the Urinary Bladder: Report of a Case and Review of the Literature

S. Sallemi, S. Ben Rhouma, A. Dahmani, Y. Nouira and A. Horchani

La Rabta Hospital, Department of Urology, Tunis, Tunisia

ABSTRACT

We report a case of concomitant transitional cell carcinoma (TCC) in a circumcaval ureter and invasive bladder cancer. The diagnosis was based on the findings of excretory urography (IVU) and contrast-enhanced computed tomography (CT). IVU showed a typical J-shaped deformity in the dilated right proximal ureteric segment with moderate hydronephrosis and a filling defect in the renal pelvis, while abdominal CT with contrast showed right hydronephrosis with an intra-pelvic tumor. The patient underwent radical cystoprostatectomy and nephroureterectomy. No recurrence was detected after 12 months of follow-up.

Key Words: Circumcaval, retrocaval, ureter, bladder, transitional cell carcinoma

Corresponding Author: Dahmani Adel, La Rabta Hospital, Department of Urology, Djebel lakhdher, 1007 Tunis, Tunisia, E-mail : drdahmani@yahoo.fr

Article Info : Date received: 5/4/2009

Date accepted (after revision): 5/9/2009

INTRODUCTION

Circumcaval or retrocaval ureter is a rare vascular congenital anomaly which leads to external compression of the ureter by the inferior vena cava (IVC)¹. Only sporadic cases have been reported in the literature.

A ureteral transitional cell carcinoma (TCC) in a retrocaval ureter is an exceptional condition and only 2 such cases have been reported^{2,3}. To our knowledge, the combination of TCC in a retrocaval ureter and bladder TCC has never been reported. Herein, we report a case of such combination.

CASE REPORT

A 56-year-old man, a heavy smoker, presented with a history of intermittent right flank pain and gross hematuria of one year's duration.

Clinical examination was unremarkable apart from moderate right flank tenderness. Intravenous urography (IVU) showed a normal left kidney, while on the right it revealed a typical J-shaped deformity of the dilated proximal ureter, moderate hydronephrosis and a filling defect in the renal pelvis (Fig. 1). Abdominal computed tomography (CT) with contrast showed right hydronephrosis with an intra-pelvic tumor (Fig. 2 A,B).

Urine culture was negative. There was no evidence of skeletal metastases on radioisotope bone scan. Cystoscopy showed a large bladder tumor and biopsy revealed a grade-3 TCC infiltrating the detrusor muscle. An *en bloc* right nephroureterectomy with radical cystoprostatectomy and ileal conduit urinary diversion were performed. Examination of the resected specimen showed a tumor in the pelvis and proximal ureter above the site

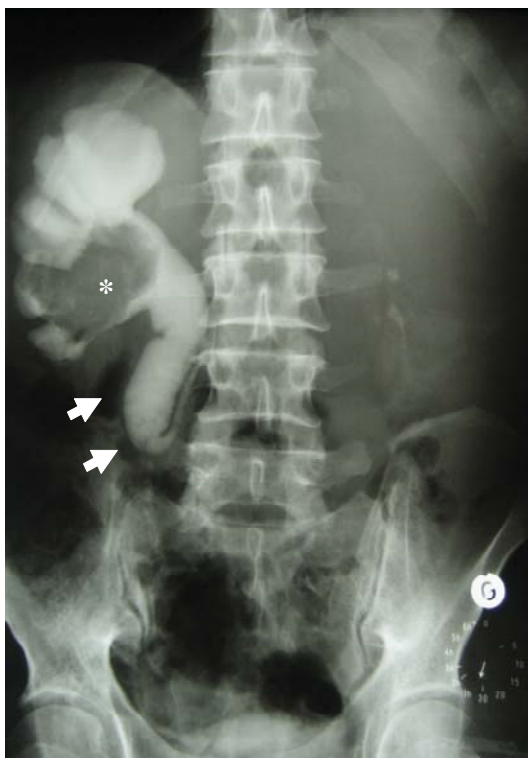

Fig. 1: IVU showing a J-shaped deformity of the dilated proximal right ureter with hydronephrosis and filling defect in the renal pelvis.

where the ureter passed behind the vena cava. On histopathologic examination the bladder and ureteral tumors were classified as TCC, stage pT4a N0 M0 and pT2 N0 M0, respectively.

The post-operative course was uneventful and after a follow-up of 12 months radiological investigations did not reveal any recurrence.

DISCUSSION

A retrocaval ureter is a rare congenital anomaly usually associated with upper urinary tract stasis and a J- or fish-hook deformity of the ureter as it passes behind the inferior vena cava (IVC). Although this anomaly is commonly known as a circumcaval or retrocaval ureter it is not the result of an abnormality in ureteral development, but rather an anomaly in the development of the IVC⁴. The

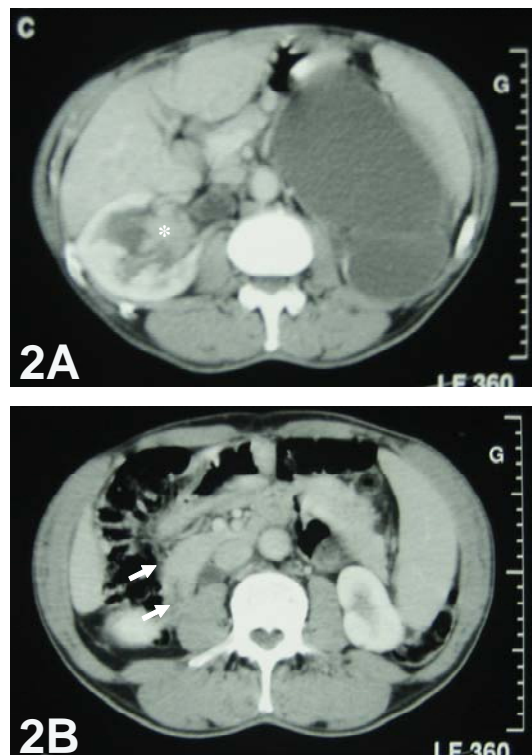


Fig. 2: Contrast-enhanced CT scan showing (A) an enhancing soft tissue mass occupying the dilated right renal pelvis and (B) the dilated proximal part of the retrocaval ureter (arrow).

abnormal position of the ureter results from anomalous development of the infrarenal IVC from the right posterior cardinal vein that is embryologically more laterally placed, instead of from the supracardinal vein that is embryologically more medial⁴. This anomaly entraps a segment of the proximal ureter as it wraps around the IVC and often results in obstruction and hydronephrosis⁵ due to compression of the ureter by the psoas muscle, spinal column and IVC⁶. It may also be due to lumen stenosis, torsion, or adhesion of the retrocaval segment⁷.

Since its first description by Hochstetter in 1893^{6,8}, approximately 200 cases of retrocaval ureter have been reported in the literature⁹. The incidence of this congenital anomaly ranges from 1 in 1000 live births¹⁰ to about 1 in 1500 at autopsy¹¹. In cadavers the male-to-female ratio has been found to be 3 to 4:1¹²; clinically, it is seen 2.8 times more frequently in men than in women^{6,13}.

Although the lesion is congenital, symptoms usually present in the third to fourth decade of life^{6,13}. In our case, the patient was 56 years old. In most patients, symptoms are due to ureteral obstruction and hydronephrosis. Patients usually present with right flank pain and discomfort, which can be intermittent, dull or aching⁶. Rarely, a lumbar mass (hydronephrotic kidney) can be palpated². The other clinical features include recurrent urinary tract infections and microscopic or gross hematuria⁷.

Imaging studies are usually accurate and sufficient for the diagnosis of retrocaval ureter. Ultrasonography is a non-invasive method to demonstrate the anatomy of the retrocaval ureter and to follow up the patients for hydronephrosis, parenchymal atrophy, and nephrolithiasis⁷. IVU and retrograde urography have been commonly used to diagnose a circumcaval ureter. The upper ureter is typically elongated and dilated in a J- or fish-hook shape before it passes behind the IVC. IVU may fail to visualize the portion of the ureter that extends behind the IVC. Retrograde ureteropyelography may help demonstrate the typical fish-hook curve of the upper ureter towards the midline, with the retrocaval segment at the level of the 3rd or 4th lumbar vertebra^{6,13}. Spiral CT scan is the imaging modality of choice for the diagnosis of IVC abnormalities and circumcaval ureter¹⁴⁻¹⁶ as it is non-invasive and accurately determines the anatomic relationship of the IVC and ureter¹⁷.

Ureteral TCC in a retrocaval ureter is an exceptional condition. To our knowledge, only two such cases have been reported^{2,3}. Some investigators have suggested that urinary stasis in a dilated upper urinary tract may be tumorigenic⁹. Urinary stasis increases the contact time of urinary metabolites with the urothelium of the dilated collecting system. Smoking, as in our patient, may be a predisposing factor. Synchronous TCC of the bladder and ureter was found in 2.3% of patients with bladder TCC, in 39% of those with ureteral TCC, and in 24% of those with renal TCC¹⁸. To our knowledge, our patient is the first reported case of synchronous upper

urinary tract TCC in a circumcaval ureter and bladder tumor.

As recommended for treatment of TCC of the upper urinary tract and invasive bladder TCC, our patient underwent radical cystoprostatectomy and radical nephroureterectomy. No recurrence has been observed at one year of follow-up.

REFERENCES

1. Walsh PC, Retik AB, Vaughan EDJ. *Cambell's urology*. 8th ed. Philadelphia: W.B. Saunders; 2003.
2. Clements JC, McLeod DG, Greene WR, Stutzman RE. A case report: Duplicated vena cava with right retrocaval ureter and ureteral tumor. *J.Urol.* 1978; Feb;119(2):284-5.
3. Sanroma Ortueta I, Garmendia Larrea JC, Garrido Rivas MC, Lopez Garcia JA, Arocena Lanz F. Carcinoma transicional en ureter retrocavo. [Transitional cell carcinoma in a retrocaval ureter]. *Arch.Esp.Urol.* 1989; Nov-Dec;42(9):919-21.
4. Lautin EM, Haramati N, Frager D, Friedman AC, Gold K, Kurtz A, et al. CT diagnosis of circumcaval ureter. *AJR Am.J.Roentgenol.* 1988; Mar;150(3):591-4.
5. Baba S, Oya M, Miyahara M, Deguchi N, Tazaki H. Laparoscopic surgical correction of circumcaval ureter. *Urology.* 1994; Jul;44(1):122-6.
6. Zhang XD, Hou SK, Zhu JH, Wang XF, Meng GD, Qu XK. Diagnosis and treatment of retrocaval ureter. *Eur. Urol.* 1990;18(3):207-10.
7. Huang KH, Chang SC, Chueh SC, Huang CY, Pu YS, Chen J. Retrocaval ureter: Report of 12 cases and literature review. *JTUA.* 2005; Dec;16(4):163-4.
8. Hochstetter F. Beitrage zur Entwicklungsgeschichte des Venensystems der Amnioten. III. Sauger. *Morph.Jahrb.* 1889;20:542.
9. Miller DC, Kropp KA. Transitional cell carcinoma associated with crossed renal ectopia and previous cyclophosphamide therapy. *J.Urol.* 1992; Oct;148(4):1244-6.
10. Heslin JE, Mamonas C. Retrocaval ureter: Report of four cases and review of literature. *J.Urol.* 1951; Feb;65(2):212-22.
11. Johansson NT, Nilsson S, Schersten T, Schvarcz J, Weiland PO. Retrocaval ureter. Report of a case and short review of the literature. *Scand.J.Urol.Nephrol.* 1969;3(1):53-8.

12. Peters CA, Schluskel RN, Retik AB. Pediatric laparoscopic dismembered pyeloplasty. *J.Urol.* 1995; Jun;153(6):1962-5.
13. Kenawi MM, Williams DI. Circumcaval ureter: A report of four cases in children with a review of the literature and a new classification. *Br.J.Urol.* 1976; Jun;48(3):183-92.
14. Rubinstein I, Cavalcanti AG, Canalini AF, Freitas MA, Accioly PM. Left retrocaval ureter associated with inferior vena caval duplication. *J.Urol.* 1999; Oct;162(4):1373-4.
15. Singh DD, Sanjeev P, Sharma RK. Spiral CT evaluation of circumcaval ureter (retrocaval ureter). *Ind.J.Radiol. Imag.* 2001;11:83-4.
16. Bass JE, Redwine MD, Kramer LA, Huynh PT, Harris JH,Jr. Spectrum of congenital anomalies of the inferior vena cava: Cross-sectional imaging findings. *Radiographics.* 2000; May-Jun;20(3):639-52.
17. Pienkny AJ, Herts B, Strem SB. Contemporary diagnosis of retrocaval ureter. *J.Endourol.* 1999; Dec;13(10):721-2.
18. Yousem DM, Gatewood OM, Goldman SM, Marshall FF. Synchronous and metachronous transitional cell carcinoma of the urinary tract: Prevalence, incidence and radiographic detection. *Radiology.* 1988; Jun;167(3):613-8.