

## Case Report

# Ectopic Splenic Tissue in the Testis: A Case Report

E. Bekar<sup>1</sup>, T. Yalta<sup>1</sup>, H. Yarıcı<sup>2</sup>, A. Dogdas<sup>3</sup> and Y. Tuncer<sup>4</sup>

*Departments of <sup>1</sup>Pathology, <sup>2</sup>Urology, <sup>3</sup>Radiology and <sup>4</sup>General Surgery, Sivas State Hospital, Sivas, Turkey*

## ABSTRACT

Splenogonadal fusion is a rare congenital anomaly that has been encountered in all age groups. It is defined as an abnormal connection between spleen and gonad or mesonephros derivatives. We report a case of splenogonadal fusion which was diagnosed incidentally in a 38-year-old man with a history of infertility. This rare entity should be considered in the differential diagnosis of testicular masses.

**Key Words:** Splenogonadal fusion, testicular mass.

**Corresponding Author:** Dr. Tulin Yalta, Pathology Department, Sivas State Hospital, Sivas 58100, TURKEY, E-mail: tdeyalta@yahoo.com

**Article Info :** Date received: 4/3/2009

Date accepted (after revision): 24/5/2009

## INTRODUCTION

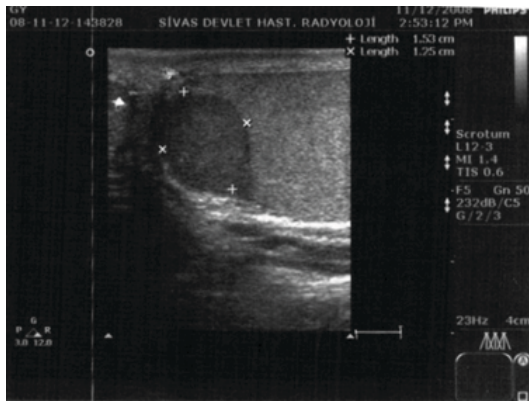
Splenogonadal fusion, which was first described in the late 19<sup>th</sup> century, is considered primarily as a separation anomaly between the precursor cells of the spleen and gonads resulting from the anatomical proximity of these cell lines during a specific period of gestation (between the 5<sup>th</sup> and 8<sup>th</sup> week) with a consequent failure of total separation. This leads to co-migration of gonads with splenic remnants<sup>1</sup>. The scarceness of reports in the literature underlines the rarity of this entity. We report a case of splenogonadal fusion in a 38-year-old man with a history of infertility.

## CASE REPORT

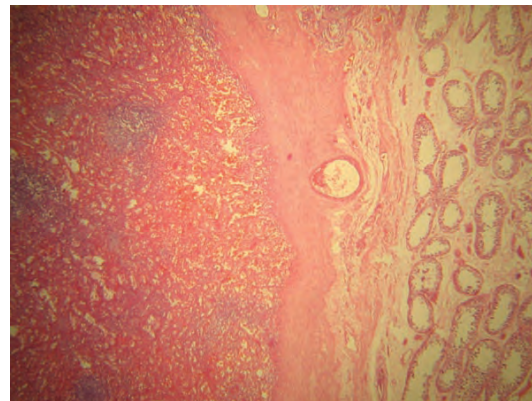
A 38-year-old male patient was referred to our urology clinic with a complaint of infertility. During routine physical examination, a palpable left scrotal mass was found. The levels of the tumor markers (alpha fetoprotein [ $\alpha$ FP], human chorionic gonadotropin [ $\beta$ HCG]) were normal. Ultrasonographic (USG) examination demonstrated a hypoechoic mass (12 x 15 mm in size) in the upper

part of the left testis (Fig. 1). The mass was found to be poorly circumscribed and grossly distorting the testicular parenchyma. Doppler examination also revealed increased vascularity in the mass. After these diagnostic tests, the patient underwent left orchiectomy.

On macroscopic examination of the resected material (13 x 14 x 3 cm in size), the testicular sections, in general, were found to be homogeneous and brown in color. In one section, there was a well circumscribed, homogeneous and glistening dark-brown lesion of 2 cm in diameter. The epididymis and cord structures were found normal. On microscopy, beneath the seminiferous tubules, there appeared to be a well-circumscribed lesion with a thick fibrous capsule. The lesion comprised a structure that was reminiscent of splenic tissue characterized by the presence of a central arteriole, surrounding lymphoid follicles (white pulp), and interspersed sinusoids (red pulp) (Fig. 2). This finding was consistent with intratesticular ectopic splenic tissue.



**Fig. 1:** Ultrasonography demonstrating a hypo-echoic mass (12 x 15 mm) in the upper part of the left testis.



**Fig. 2:** Microscopy demonstrating splenic tissue circumscribed by a fibrous capsule separating it from the seminiferous tubules (HE x 40).

## DISCUSSION

Splenogonadal fusion is a rare entity that may be encountered in both sexes, but is more common in males, predominantly involving the left gonad. Two main variants are known to exist based on the anatomic relationship between the spleen and gonads: continuous and discontinuous forms. In the continuous form, the orthotopic spleen is attached to the gonad with a cord of fibrous or splenic tissue, while in the discontinuous form there is no connection between these organs<sup>2</sup>.

The most common symptom is testicular swelling, and most patients present with a scrotal mass<sup>2,3</sup>. Acute scrotal pain may also occur due to the involvement of ectopic splenic tissue by malaria, leukemia, mononucleosis or mumps<sup>3</sup>. The accompanying intraperitoneal cord may also give rise to bowel obstruction in some cases. Some of the cases reported to date were diagnosed incidentally (as in the present case). Testicular neoplasms have been reported in only 3 cases with splenogonadal fusion<sup>2</sup>.

Splenogonadal fusion may be associated with other congenital anomalies such as limb malformations, micrognathia, cardiac defects, cleft palate, anal anomalies, craniosynostosis, spina bifida and, most commonly, cryptorchidism<sup>3</sup>. Duncan et al. reported a case of splenogonadal fusion

associated with bilateral cryptorchidism and hypospadias<sup>4</sup>. Brasch et al. reported a case involving the right testis<sup>5</sup>.

Ultrasonography, scintigraphy (with technetium-99m) and single positron emission computerized tomography are considered the best diagnostic tools for this condition<sup>2,3</sup>.

In 37% of the reported cases orchiectomy was performed because of suspected neoplasms<sup>2,3</sup>. Intra-operatively, pathological examination of a frozen section of the testicular biopsy material may be performed to avoid unnecessary orchiectomy<sup>1,6</sup>. Treatment of splenogonadal fusion consists of simply dissecting the splenic tissue from the involved gonad and generally leads to complete cure of the patient<sup>3</sup>.

In conclusion, this rare entity should be kept in mind in the differential diagnosis of testicular masses. Since the majority of patients with this entity are young adults, particular attention should be paid to the prevention of unnecessary orchiectomy.

## REFERENCES

1. Trias Puig-Sureda I, Orsola los de Santos A, Raventós Busquets CX, Español Quintilla I, Bucar Terrades S. [Splenogonadal fusion. Report of a case] *Fusión*

## ECTOPIC SPLENIC TISSUE IN THE TESTIS

- esplenogonadal. Presentación de un caso. *Actas Urol. Esp.* 2007; May;31(5):559-61.
2. Shen XC, Du CJ, Chen JM. Case report: Splenogonadal fusion. *Zhejiang Da Xue Xue Bao Yi Xue Ban.* 2007; May;36(3):1.
  3. Al Hashash B, Yadav SK, Malik A. Splenogonadal fusion in a boy: Case report and review of literature. *Kuwait Med.J.* 2008;40(1):72-4.
  4. Duncan WL,Jr, Barraza MA. Splenogonadal fusion: A case report and review of literature. *J.Pediatr.Surg.* 2005; Dec;40(12):e5-7.
  5. Brasch J, Roscher AA. Unusual presentation on the right side of ectopic testicular spleen. *Int.Surg.* 1987; Oct-Dec;72(4):233-4.
  6. Heimbach D, Wirth M, Muller J, Frohmuller H. Ektopisches Milzgewebe in Verbindung zum Hoden. [Ectopic splenic tissue in connection with the testis]. *Urologe A.* 1991; Mar;30(2):92-3.

### **Editorial Comment:**

It is worthwhile to publish this case report, as it describes an important differential diagnosis of testicular masses. In the present case, ultrasonography showed a mass typical for testicular cancer. No frozen section was done and the patient was subjected to orchiectomy, which proved to be the wrong decision. Therefore, it is good to be aware of such rare entities.

Dr. Susanne Krege,  
Maria Hilf Hospital, Krefeld, Germany