



African Journal of Urology

Official journal of the Pan African Urological Surgeon's Association
web page of the journal

www.ees.elsevier.com/afju
www.sciencedirect.com



Reconstructive Urology

Case report

Severe congenital penile torsion with anterior urethral diverticulum: A case report



Amilal Bhat ^{a,*}, Vikas Singh ^b, Mahakshit Bhat ^a, Aksita Bhat ^c

^a Department of Urology, S.P. Medical College, Bikaner, Rajasthan, 334003, India

^b Department of Urology, Dr. S.N. Medical College, Jodhpur, Rajasthan, 334003, India

^c Department of Surgery, S.P. Medical College, Bikaner, Rajasthan, 334003, India

Received 19 May 2017; received in revised form 8 October 2017; accepted 6 December 2017

Available online 16 February 2018

KEYWORDS

Penile torsion;
Urethral diverticula;
Congenital anomalies;
Mobilization of urethra;
Urethroplasty;
Double Breasting;
Correction of penile torsion

Abstract

Introduction: We present a rare case of severe penile torsion of 180° along with giant congenital anterior urethral diverticula. Presentation of these two rare anomalies together is extremely rare and has not been reported yet. The extreme rarity of the case and its management warrants this presentation.

Observation: A 5 years old boy presented to us as a case of epispadias with post-void dribbling and wetting of the underwears. On examination, he was found to be a case of severe congenital penile torsion with diversion and rotation of median raphe in a counterclockwise fashion upto the midline dorsally confirming 180° torsion. During voiding, there was appearance of a swelling in distal penile region with passage of urinary drops while compressing it. Micturating cystourethrogram showed diverticula in penile and bulbar urethra. Torsion was completely corrected by penile de-gloving in a plane between two layers of buck fascia and mobilization of the urethra along with spongiosum proximally upto the penoscrotal junction and distally upto the glans. Diverticula was laid open and underwent urethroplasty along with double breasting of thickened diverticular tissue. Torsion was completely corrected after surgery. Post-operative recovery was uneventful. Urine culture was sterile and uroflowmetry showed maximal urinary flow of 12 ml/s at 3 months postoperatively.

Conclusions: Penile de-gloving and adequate urethral mobilization corrects the severe penile torsion of 180°. Correction of severe torsion and urethroplasty is feasible in a single stage with good results.

© 2018 Pan African Urological Surgeons Association. Production and hosting by Elsevier B.V. This is an open access article under the CC BY-NC-ND license (<http://creativecommons.org/licenses/by-nc-nd/4.0/>).

* Corresponding author at: C-15 Sadul Ganj, Bikaner, Rajasthan, 334003, India.

E-mail addresses: amilalbhat@redifmail.com (A. Bhat), 037drvikassingh@gmail.com (V. Singh), mahak199027@gmail.com (M. Bhat), akshit7@gmail.com (A. Bhat).

Peer review under responsibility of Pan African Urological Surgeons' Association.

<https://doi.org/10.1016/j.afju.2017.12.002>

1110-5704/© 2018 Pan African Urological Surgeons Association. Production and hosting by Elsevier B.V. This is an open access article under the CC BY-NC-ND license (<http://creativecommons.org/licenses/by-nc-nd/4.0/>).

Introduction

Severe congenital penile torsion is rare and its association with anterior urethral diverticula has not been reported to the best of our knowledge. The incidence and various techniques for correction of penile torsion with their advantages and disadvantages are reported in the literature [1–8]. The new simplified technique of penile de-gloving and urethral mobilization along with spongiosum, corrects even the severe penile torsion [4]. Both of the congenital anomalies were treated in a single stage with good functional as well as cosmetic results. The extreme rarity of the case and its simplified correction in a single stage warrants the reporting.

Case report

A 5 year old male boy presented to us as a case of epispadias. Parents complained of appearance of swelling on the dorsal aspect of penis during voiding, stream pointing backwards falling on the thighs and post void dribbling with wetting of the underwears since birth. On examination, he was found to be a case of severe congenital penile torsion with counterclockwise rotation of median raphe up to the midline dorsally confirming 180° torsion (Fig. 1A). The meatus was seen dorsally on retraction of the prepuce (Fig. 1B). During voiding, there was appearance of a swelling on the left dorso-lateral aspect of the distal penis with urinary stream pointing backwards between the thighs (Fig. 1C) and there was dribbling of urine on

compressing the area after micturation. Urine examination showed 2–3 pus cells/HPF. Renal functions were normal. Ultrasonography of abdomen showed normal upper tracts and bladder wall with insignificant post void residual urine. Micturating cystourethrogram showed diverticula on dorsal surface of penis. The angle between proximal normal urethra and diverticular wall was obtuse, which was more in favour of diverticula (Fig. 1D). The patient was planned for reconstructive surgery in a single stage. Penile de-gloving was done through circumferential subcoronal incision in subdartos plane upto the root of penis. Torsion persisted even after this. Then the urethra along with spongiosum was mobilized proximally upto the penoscrotal junction and distally upto the glans. This corrected the torsion completely (Fig. 2A). Then the diverticula was laid open and urethral mucosal lining was separated from overlying thickened diverticular wall (Fig. 2B). Urethroplasty along with double breasting of thickened diverticular wall over a 6 Fr infant feeding tube was done (Fig. 2C and D). A third layer of dartos was used to cover the urethral tube and then skin was closed as a fourth protective layer (Fig. 2E).

Postoperative course was uneventful. Penile torsion was completely disappeared. Feeding tube was removed on 10th postoperative day. Patient voided well with good stream. Patient was followed up at 1, 3, 6 and 12 months. At 3 month, Urine culture was sterile and uroflowmetry showed maximal urinary flow of 12 ml/s.

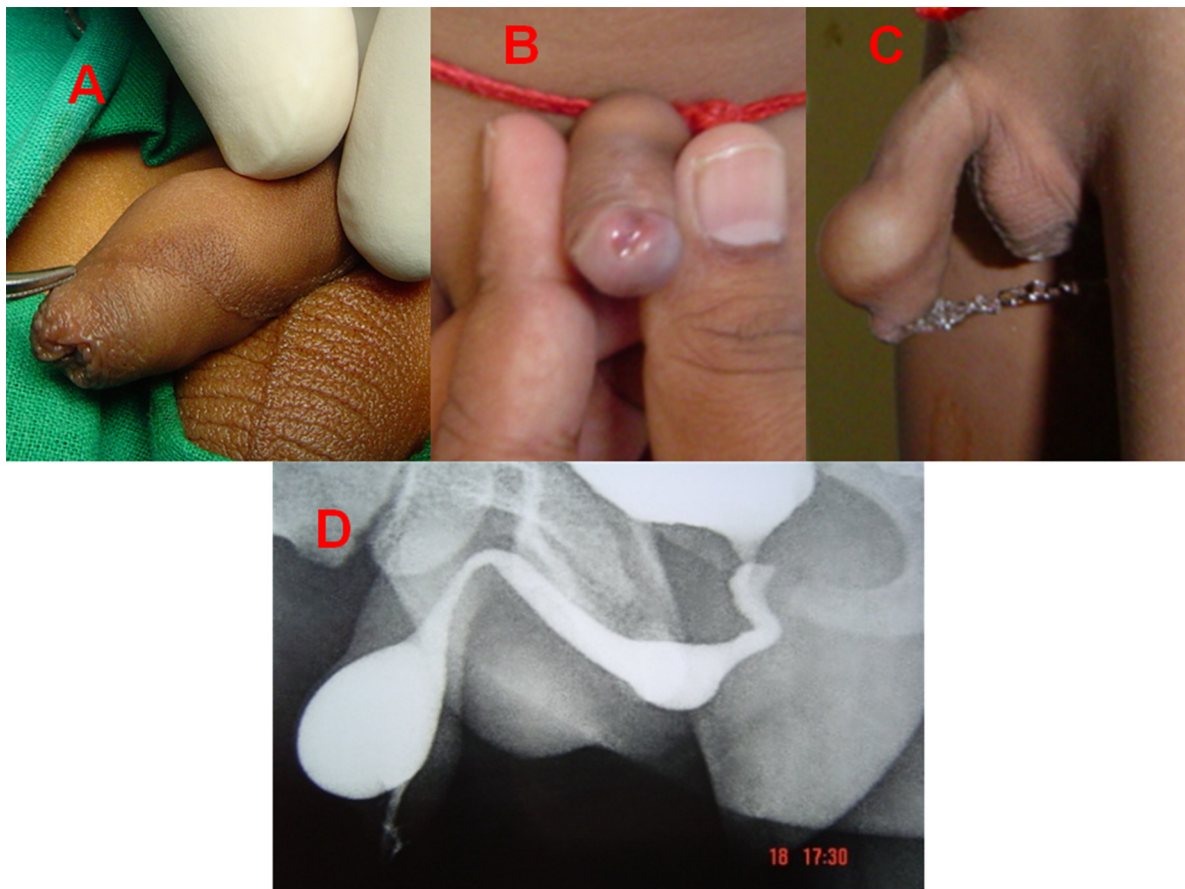


Figure 1 Figure showing penile torsion and diverticula. (A) Showing end of median raphe dorsally midline. (B) Showing the meatus on dorsal side. (C) Showing penile swelling on dorsal surface of penis and urinary stream directed posteriorly between the thighs. (D) Showing the micturating cystourethrogram with anterior urethral diverticula on the dorsal side of penis.

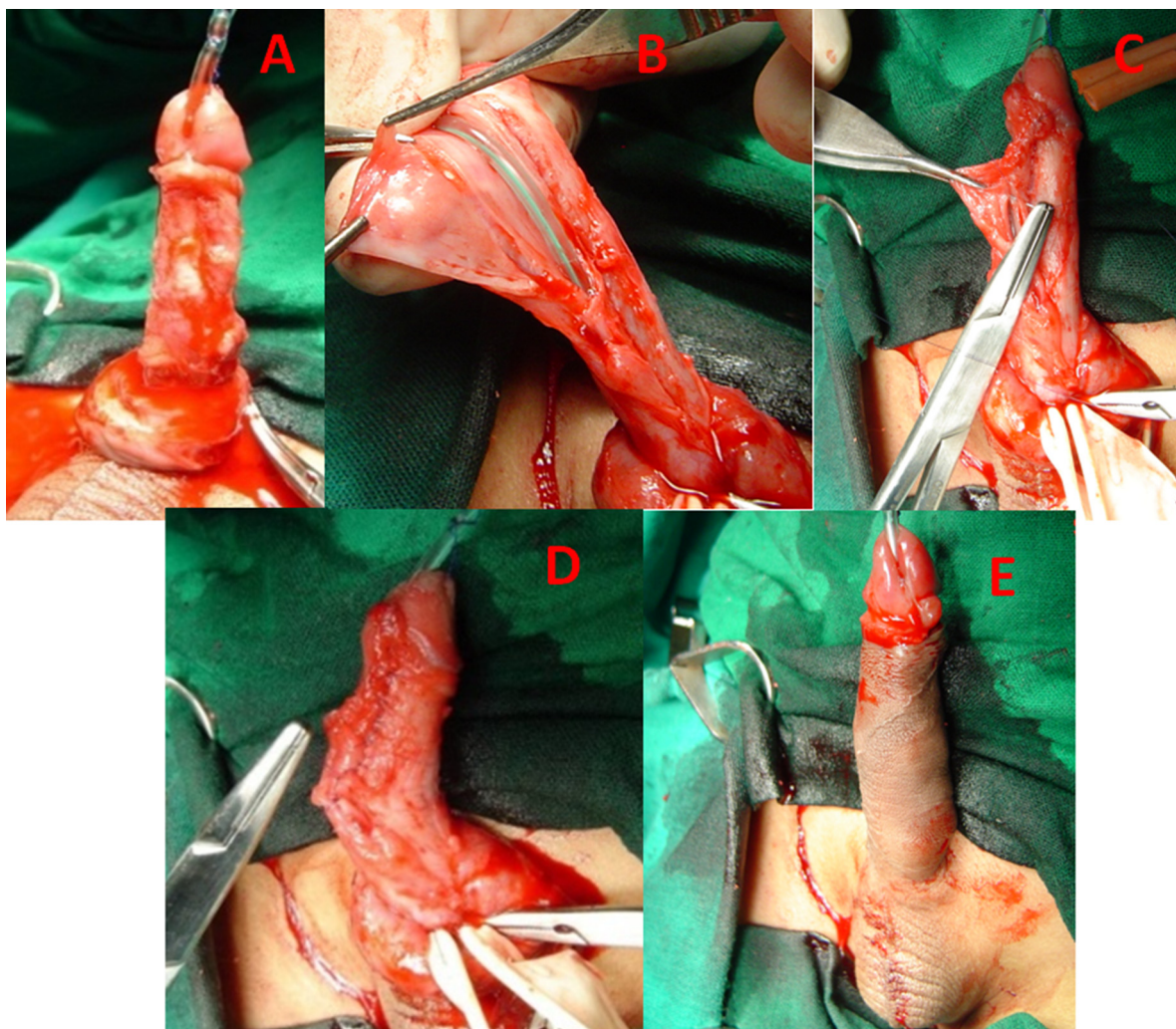


Figure 2 Figure showing correction of penile torsion and diverticula. (A) Showing correction of penile torque by penile de-gloving and mobilization of urethra. (B) Showing laying opening of urethral diverticula and excision of urethral mucosa of a part of urethral diverticula. (C) Showing closure of urethra. (D) Showing double breasting of flap over the neo-urethra. (E) Showing skin closure and correction of torque.

Discussion

The true incidence of congenital penile torsion is not known as most of the cases are unreported [5]. It is seen independently or in association with other penile and urethral malformations including hypospadias, epispadias or chordee without hypospadias [6]. The association of penile torsion with anterior urethral has not reported in the literature. Torsion may be classified as mild ($<45^\circ$), moderate ($45\text{--}90^\circ$) or severe ($>90^\circ$) degree depending upon the degree of rotation of median raphe from midline [2]. Incidence of isolated penile torsion ranges between 1.7% to 27%, that of severe torsion to be 0.7% [6]. Eroglu and Gundogdu found the incidence of 20% and only 0.4% babies were having severe degree of torsion ($>90^\circ$) [7].

There is no consensus on the exact etiology of congenital penile torsion. Most of the people suggested that the underlying cause is the abnormal attachment of skin and dartos fascia [8]. Some suggested involvement of other tissues, such as Buck's fascia, corpus cavernosum and tunica albuginea [1]. Bhat et al. proposed the eccentric fusion of the endodermal and/or ectodermal urethral folds is responsible for penile torsion. This leads to misdirected,

unequal mesodermal proliferation during formation of the corpora and, hence, aberrant attachment of the fascial coverings of the penis and spongiosum to one side, leading to torsion [6]. Embryology of urethral diverticula is not well defined but abortive corpus spongiosum over the affected urethral part is believed to be a cause [9]. The basic embryological explanation of these two congenital anomalies happening together is not clear but the possible explanation may be that improper proliferation of mesodermal tissue may lead to poor development of spongiosum and coverings due to the eccentric fusion of urethral folds. This may lead to poor support of spongiosum and potential weak area for diverticulation.

Most of the patients with isolated penile torsion are asymptomatic unless it is of severe degree. Isolated penile torsion of mild degree usually does not need any intervention unless parents and/or patient insist for cosmetic correction [6]. Mild degree of torsion can be corrected by simple penile de-gloving and skin reattachment [7,8]. Whereas for moderate to severe torsion of more than $45\text{--}90^\circ$, simple degloving is insufficient and needs some advance procedures like resection of Buck's fascia, dorsal dartos flap rotation, suturing the tunica albuginea to the pubic periosteum, diagonal corporal

placation and correction by mobilization of urethral plate and urethra [1–3,6]. Among these the most popular and the most studied one is dorsal dartos flap rotation. But there are chances of under or overcorrection with this. The new technique of penile de-gloving and mobilization of urethra along with spongiosum proximally upto penoscrotal junction/bulb and distally upto the glans corrects torsion of severe degree [6]. We have also used this technique in our case and corrected the torque of 180° successfully.

Giant anterior urethral diverticulum is a rare entity [10]. It may be located anywhere in the anterior urethra, but the most common location is penile urethra. This entity should be differentiated from diverticula due to anterior urethral valves, as the treatment differs for both conditions. In our case, penile torsion was associated with giant congenital anterior urethral diverticula. Even after extensive literature search, we were unable to find any such case report. Clinical presentation depends upon the size of diverticulum and its neck. Large diverticular wall may act as a flap and can give obstructive symptoms [10]. Small neck diverticula can retain the urine and lead to recurrent urinary tract infections [9]. Patients usually present with penile swelling and postvoid dribbling as in our case.

Transurethral resection with a paediatric resectoscope is the treatment of choice for small, well-supported diverticula wherein the distal obstructing lip is resected. But in the large diverticula, as also in our case, open diverticulectomy and primary repair is recommended [9]. Double breasting with denuded urethral mucosal wall of diverticula (Fig. 1D) further strengthens the repair and prevents recurrence of diverticula.

Conclusion

This is the first case of severe penile torsion with anterior urethral diverticula. Penile degloving along with adequate urethral mobilization corrects severe penile torsion of 180°. Correction of severe penile torsion by penile de-gloving & mobilization of urethra, excision of urethral diverticula and urethroplasty is feasible in a single stage with good functional and cosmetic results.

Authors' contributions

The corresponding author (Dr. Amilal Bhat) contributed in concept design, application of technique, clinical data collection, preparing,

reviewing and editing of the manuscript. While the co-authors (Dr. Vikash Singh, Mahakshit Bhat, and Akshita Bhat) participated in literature search, manuscript writing, reviewing and editing.

Consent from the patient

Obtained.

Conflict of interest

The authors declare that they have no conflict of interest.

Source of funding

None.

References

- [1] Aldaqadossi HA, Elgamel SA, Seif Elnasr M. Dorsal dartos flap rotation versus suturing tunica albuginea to the periosteum for correction of penile torsion: a prospective randomized study. *J Pediatr Urol* 2012;9:643–7.
- [2] Fisher C, Park M. Penile torsion repair using dorsal dartos flap rotation. *J Urol* 2004;171:1903.
- [3] Abou Zeid A, Soliman H. Penile torsion: an overlooked anomaly with distal hypospadias. *Ann Pediatr Surg* 2010;6:93–7.
- [4] Bhat A, Sabharwal K, Bhat M, Singla M, Upadhaya R, Kumar V. Correlation of severity of penile torsion with type of hypospadias & ventral penile curvature and their management. *Afr J Urol* 2015;21:111–8.
- [5] Sarkis PE, Sadasivam M. Incidence and predictive factors of isolated neonatal penile glanular torsion. *J Pediatr Urol* 2007;3:495–9.
- [6] Bhat A, Bhat MP, Saxena G. Correction of penile torsion by mobilization of urethral plate and urethra. *J Pediatr Urol* 2009;5:451–7.
- [7] Eroglu Egemen, Gundogdu Gokhan. Isolated penile torsion in newborns. *Can Urol Assoc J* 2015;9(11–12):E805–7.
- [8] Hussein A, Naguib I, Wilson AM. Penile de-gloving and skin reattachment technique for repair of penile torsion. *J Plastic Reconstr Surg* 2007;31:19–23.
- [9] Gupta DK, Srinivas M. Congenital anterior urethral diverticulum in children. *Pediatr Surg Int* 2000;16(8):565–8.
- [10] Mohan V, Gupta SK, Cherian J, et al. Urethral diverticulum in male subjects: report of 5 cases. *J Urol* 1980;123:592–4.