



African Journal of Urology

Official journal of the Pan African Urological Surgeon's Association
web page of the journal

www.ees.elsevier.com/afju
www.sciencedirect.com



Reconstructive Urology

Original article

Functional and cosmetic outcome of partial penile disassembly repair in isolated male epispadias patients



A. Bhat*, M. Bhat, R. Kumar, V. Kumar

Department of Urology, Preventive and Social Medicine, S.P. Medical College, Bikaner 334003, India

Received 14 July 2015; received in revised form 27 September 2015; accepted 30 September 2015

Available online 4 July 2017

KEYWORDS

Congenital anomalies;
Epispadias repair;
Single stage repair;
Partial penile disassembly;
Urethroplasty;
Complication of epispadias repair;
Continence;
Functional and cosmetic outcome

Abstract

Introduction: Epispadias is a rare congenital anomaly and requires a carefully constructed and well-planned approach for the management. Modified Cantwell-Ransley technique and Mitchell's complete penile disassembly are commonly used technique and these may require multiple surgeries in majority of the patients to achieve the goals of cosmesis and continence.

Objective: To evaluate the functional and cosmetic outcome of single stage partial penile disassembly repair in isolated male epispadias.

Patients and methods: A retrospective analysis of 43 cases of primary epispadias repair, performed during July 1998 to March 2013. Patients were classified on the basis of type of epispadias, urinary incontinence, presence/degree of chordee and penile rotation.

Technique: Penile de-gloving with mobilization of urethral plate from ventral to dorsal aspect with preservation of blood supply at both ends, distally up to the level of mid-glans and proximally up to pubic symphysis with division of peno-pubic ligament to lengthen the penis and position the urethra ventrally. Tubularization of urethral plate followed by spongioplasty, corporoplasty with medial rotation of corporeal bodies (without any corporotomy) and glanuloplasty with meatoplasty is done to bring the meatus ventrally. Skin cover with rotation of ventral flaps and z-plasty when required.

Results: Age of the patients varied from 6 months to 26 years with a mean of 9 years. Ninety three percent of the patients had excellent cosmetic outcome while seven percent had minimal residual chordee/torque but did not require any surgery. None of the patients developed complications like fistula or stricture. All the 12 patients in the postpubertal group reported normal erections and successful ejaculations after the surgery. Postoperative follow up ranged from 2 to 10 years with a mean of 4 years.

* Corresponding author at: C-15 Sadul Ganj, Bikaner, Rajasthan 334003, India.

E-mail addresses: amilalbhat@redifmail.com (A. Bhat), mahak199027@gmail.com (M. Bhat), drrajeevkr2k@gmail.com (R. Kumar), vinaysinghkgmc99@gmail.com (V. Kumar).

Peer review under responsibility of Pan African Urological Surgeons' Association.

<http://dx.doi.org/10.1016/j.afju.2015.09.010>

1110-5704/© 2017 Pan African Urological Surgeons Association. Production and hosting by Elsevier B.V. This is an open access article under the CC BY-NC-ND license (<http://creativecommons.org/licenses/by-nc-nd/4.0/>).

Conclusions: The technique incorporates all the benefits of Cantwell-Ransley repair, can be done with less extensive dissection than total penile disassembly. Both functional and cosmetic results are good with low complication rate. Spongioplasty reconstructs near normal urethra and corporoplasty with spongioplasty also helps in prevention of urethral fistula.

© 2017 Pan African Urological Surgeons Association. Production and hosting by Elsevier B.V. This is an open access article under the CC BY-NC-ND license (<http://creativecommons.org/licenses/by-nc-nd/4.0/>).

Introduction

Epispadias is a rare congenital anomaly which occurs in 1 in 117,000 and male's most common variety being peno-pubic epispadias (70%) [1,2]. These patients may suffer from urinary incontinence especially the peno-pubic variant. A carefully constructed and well-planned approach is the pre-requisite to the management of these patients. Currently, there are two popular surgical techniques described well in the literature are; modified Cantwell-Ransley technique, which involves partial disassembly of the penis and placement of the urethra in a ventral position and Mitchell's complete penile disassembly. The drawbacks of Modified Cantwell-Ransley technique are persistence of short penile length and residual dorsal chordee along with a need for second procedure to achieve continence [3,4]. The major disadvantages of the Mitchell technique are the aggressive dissection which endangers the blood supply to urethra and resultant hypospadias meatus which may require a second surgery in significant proportion of cases [5]. Both the techniques require multiple surgeries in majority of the patients to achieve the goals of cosmesis and continence. Purpose of the study was to evaluate the functional and cosmetic outcome of single stage partial penile disassembly repair in isolated male epispadias patients.

Patients and methods

A retrospective analysis of surgical outcome of 50 cases of primary epispadias repair operated during July 1998 to March 2013 was performed. All patients of primary epispadias who were continent or partially incontinent were included in the study. Primary epispadias with total incontinence (7 cases) who underwent partial penile with double breasting of bladder neck were published earlier so excluded from the study [6]. The exclusion criteria were: (1) those who underwent partial penile disassembly with double breasting of the bladder neck; (2) those with epispadias associated with bladder exstrophy; and (3) re-operative cases.

Surgical technique

Circum-coronal incision with U shape extension encircling the urethral plate and meatus after local infiltration of adrenaline (1:100,000) (Fig. 1A–C). Penile de-gloving is done up to root of the penis. Mobilization of urethral plate from ventral to dorsal aspect (Fig. 1D and E), proximally right up to pubic symphysis exposing the bladder neck with division of peno-pubic ligament and distally up to the level of mid-glans helps in penile lengthening. Blood supply to urethral plate is to be preserved at both ends and it is dissected off from both the corpora one after other (Fig. 1F and G) to disassemble the penis into three separate compartments with mobilization of the

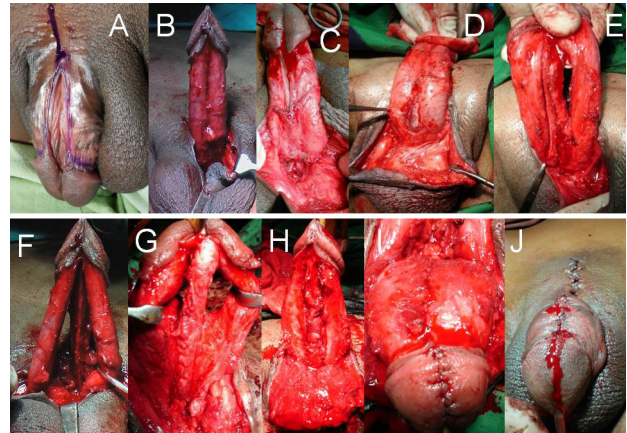


Fig. 1 (A) Peno-pubic epispadias. (B, C) Incision around the epispadiac meatus, coronal Sulcus and urethral plate and Penile de-gloving. (D, E) Urethral plate mobilization. (F, G) Urethral plate dissected off corpora and penis disassembled into 3 separate compartments (2 corpora & urethral plate with spongiosum). (H) Tubularization of urethral plate Spongioplasty ventral fixation of urethra. (I) Corporoplasty and glanuloplasty. (J) Skin closure and final appearance straight penis.

both the corpora and urethral plate with spongiosum leaving only the distal most attachment at glans intact. Corporal bodies are mobilized partially from the pubic rami to lengthen the penis. Tubularization of urethral plate is done after placing a feeding tube (suitable size for age) starting proximally from the bladder neck. Spongioplasty (Vicryl 6–0) is done subsequently (Fig. 1H). Corporal bodies are rotated medially with transposition of neurovascular bundle dorsally, no corporotomy incision is given, but a corporoplasty along the entire length with Vicryl 4 to 6–0 is performed keeping the urethra ventrally. Urethra is fixed with the corpora at its newly created, normal anatomical ventral location. Glanuloplasty and meatoplasty is done to create a conical glans with normal ventral location of meatus having adequate calibre (Fig. 1I). Penile skin is covered by rotation of ventral flaps (Fig. 1J). Mobilization of urethral plate and urethra is done up to bulbar region even in penile epispadias to bring the urethra ventrally and corporal bodies are mobilized to gain the length as well as correction of rotational deformity (Fig. 2). Z plasty is added when required for skin closure and to create adequate peno-pubic angle.

Prepuceplasty was done in all suitable cases when adequate prepuce was available to restore the normal morphology. Gentle pressure dressing was to be applied and check dress was usually done on 5th postoperative day. Third generation cephalosporins and anti-

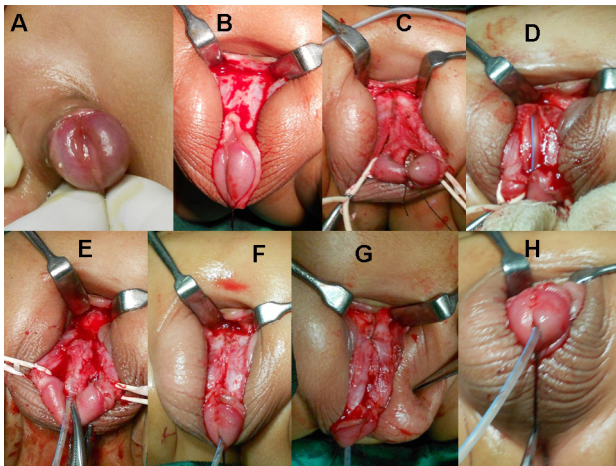


Fig. 2 (A) Penile Epispadias. (B) Penile de-gloving. (C, D) Urethral plate mobilization Urethral plate dissected off corpora and penis dis-assembly. (E) Tubularization of urethral plate and Spongioplasty. (F) Corporoplasty to bring urethra ventrally. (H) Glanuloplasty.

inflammatory drugs were given for 7–10 days postoperatively. Alprazolam was given in paediatric patients to prevent erections for 7 days in postoperative period while adolescent and adults got oestrogen 5 days prior to surgery and continued postoperatively along with alprazolam for 7–10 days. Per urethral catheter is kept for 10–14 days.

Assessment of postoperative results was done for correction of curvature (chordee/penile rotation), cosmesis, patient satisfaction and achievement of continence. Cosmesis of the penis was taken as excellent when penis became straight with conical glans conical having meatus at the tip with projectile straight urinary stream, satisfactory when persisting curvature or torque of less than 20 degree or a non-conical glans but requiring no surgical intervention. Patients having residual curvature more than 30 degree or poor flow/dribbling of urinary stream were considered as poor postoperative result. Patients/parents were interrogated about the erections and are visibly observed in follow up visits. Criteria for continence were taken as fully continent when patients void well without any leakage and had a dry interval of 2–4 h. Patients having dry interval of 1–2 h or nocturnal incontinence were labelled as partially continent, while those having continuous dribbling or dry interval of less than 1 h were taken as incontinent [6]. Patients were followed up at 1, 3, 6 and 12 months and then annually.

Results

Age of the patients varied from 6 months to 26 years with a mean of 9 years. Patients were grouped according to type of epispadias into glanular (2 cases), penile (17 cases) and penopubic (24 cases). In penopubic variety out of 24 patients, 2 (8%), 14 (58%) and 8 (34%) had mild, moderate and severe chordee respectively, Six patients (25%) had mild torque with 5 of them towards right and only 1 towards left, one patient (4.16%) had moderate torque which was towards right. Twenty one (88%) patients had excellent cosmetic outcome with complete correction of chordee/torque, however two (8%) patients had residual chordee and 1 (4%) patient developed torque after the procedure. Though the penile length was not measured but penile length was recorded with in normal range as per age

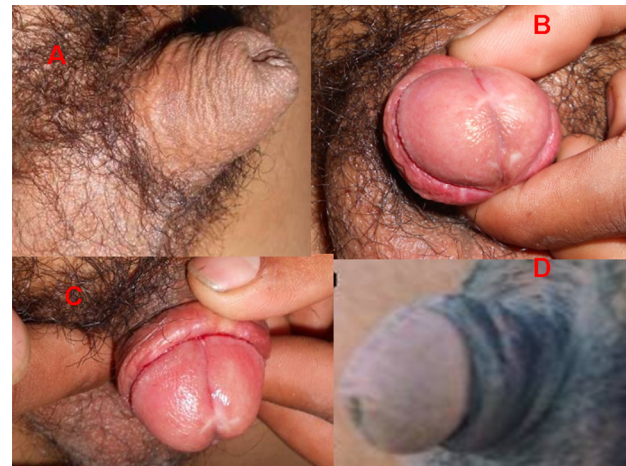

Fig. 3 (A) Post-operative photograph showing straight penis with normal looking prepuce pre after epispadias repair with preputioplasty. (B) Normal glans with slit like opening prepuce. (C, D) Normal looking glans and adequate length of penis.

of the patients, glans was conical with meatus ventrally but there was scar mark on the glans (Fig. 3B, C and D). Post-operative urethro-gram showed normal urethra 75% of cases. None of the patients required any surgical procedure for correction of chordee/torque and were satisfied with the cosmetic result. Preputioplasty was performed in 16 (75%) patients to restore near normal anatomy.

Two patients of peno-pubic variety in our series required z-plasty to achieve complete chordee correction and to create an adequate peno-pubic angle. Postoperatively one patient had complete correction of the curvature, while the other had minimal residual chordee. One patient of peno-pubic epispadias had a deficient urethral plate distally for which tube was created with penile skin flap and anastomosed proximally. He voided with good stream postoperatively without any complication.

In Penile variety out of 17 patients, 2 (12%) had mild, 9 (53%) moderate and 6 (35%) severe chordee respectively. All 17 (100%) had excellent cosmetic outcome with conical glans and meatus at the tip with complete correction of chordee/torque (Fig. 3B, C and D). Preputioplasty was added in 14 (82%) cases and these patients have more satisfactory cosmetic outcome in comparison to their counterparts without preputioplasty (Fig. 3A).

In Glanular variety (2 patients) both had complete correction of curvature with no complication and preputioplasty was performed in both of them. None of the patients developed fistula, stricture, and meatal stenosis or wound dehiscence in any type of epispadias. All the 12 patients in the post-pubertal group reported normal erections and successful ejaculations after the surgery. Post-operative follow up ranged from 2 to 10 years with a mean of 4 years.

Discussion

Historically first case of epispadias was recorded in Byzantine Emperor Heraclius [6,7]. While exstrophy–epispadias complex (EEC) is found in 1 in 10,000 births isolated male epispadias is present in 10% of these cases [8,9]. Epispadias is considered to be

relatively less severe than exstrophy–epispadias complex, but still requires high surgical expertise and repair can be challenging.

In 1845, Dieffenbach became the first surgeon ever to repair the epispadiac urethra by freshening the lateral tissue edges and placing approximating sutures. He however did not try to restore the urethral function and stressed only on cosmetic aspects [10]. In 1895, Cantwell performed the first true urethroplasty [11] for complete epispadias. He completely mobilized the dorsal urethral plate from the corpora cavernosa and trans-positioned the tubularized urethra ventrally and rotated corpora dorsally with approximation in the midline but poor vascular supply of the fully mobilized urethral tube lead to failure of repair in majority of cases. During 1918 Young [12] in order to overcome this complication, detached the urethra from the right corpus cavernosum but left it entirely attached to the left corporeal body and simply rotated it ventrally beneath the corpora. Ischaemic complications were reduced but residual chordee and short penile length persisted in significant number of patients. In 1948 Mays combined Cantwell type tubularization and ventral rotation of the urethral plate with creation of a distal urethra using ventral preputial skin [13] which converted epispadias to hypospadias and resulted in a urethra terminating at the distal penile shaft on the ventrum. This however required second surgery for cosmesis. Swenson in 1958 applied the Denis–Browne principle [14] used successfully in hypospadias repair to male epispadias by burying the longitudinal strip of urethral mucosa and approximating the corpora cavernosa dorsal to it.

In 1984, Woodhouse and Kellett performed a fascial release of tunica albuginea [15] dorsally to correct the intrinsic curvature of the corporeal bodies and prevent shortening of penile length. They stressed on identification of the course of the neurovascular bundles to avoid injury during complete mobilization of urethral plate. Since then many techniques have been introduced but none have stood the test of time apart from modified Cantwell–Ransley and Mitchell Bagli’s total penile disassembly which are commonly performed today.

Partial penile disassembly repair technique has been devised to incorporate the benefits of Cantwell–Ransley and Mitchell–Bagli and to reduce the complication rate associated with the surgery. It aims to achieve all the goals of epispadias surgery through a single procedure unlike the former two techniques thus reducing the morbidity, cost and time interval due to multiple procedures.

In the Partial Penile Disassembly Repair, certain technical modifications have been implied to incorporate the benefits of both Mitchell–Bagli and Cantwell–Ransley procedures. Unlike the Mitchell–Bagli repair, we do not detach the distal most attachment of urethral plate from the glans thus preserving the dual blood supply to the urethra reducing the ischaemic complications and avoiding creation of hypospadiac meatus [16] which occurs in 30–70% cases undergoing Mitchell–Bagli procedure. In comparison to Cantwell–Ransley we extend our proximal level of dissection from the posterior urethra up to the bladder neck. Mobilization of urethral plate in the entire extent helps to achieve complete correction of chordee and torque, bringing the urethra ventrally, performing glanuloplasty and gaining length of the penis. We agree with the Mitchell’s concept of separating urethra from its attachments to the underlying corporal bodies and pelvic diaphragm proximally up to the bladder neck. We mobilize the urethral plate dorsally up to bladder neck and ventrally up to apex of prostate to prevent the

damage of neurovascular bundle. Though the glanular and penile epispadias are minor variant of exstrophy–epispadias complex but mobilization of urethral plate/urethra should be done up to bulb even in these cases to gain the length of penis, cosmesis and alignment of corporal bodies. This allows better positioning of the bladder neck and posterior urethra into the pelvis and tubularization starting from the junction of bladder and urethra. This enhances the outlet resistance which helps to achieve urinary continence. In addition, we perform spongioplasty which further increases the resistance in the posterior urethral zone. Though the continence is not the big problem in these milder form of epispadias but if few patients have incontinence the above mentioned measure helps in continence. The continence rate after Mitchell repair was 80% [16]. This finding suggests that addition of spongioplasty as a second layer helps to improve continence rates by enhancing resistance in the urethra which creates a continent zone from bladder neck to posterior urethra. In Addition, spongioplasty provide good blood supply to urethra which helps in prevention both fistula and stricture. We do not do corporo-corporotomy which is a part of modified Cantwell–Ransley technique. Incision and suturing the corporeal bodies increases the chances of infection, fibrosis and neurovascular damage. Corporal bodies are mobilized partially from their attachment to lengthen the penis, corporoplasty is done with mild rotation keeping the urethra ventrally which also lengthen the penis as well helps in prevention of dorsal urethral fistula which had been one the complication of modified Cantwell–Ransley. Urethra is fixed on the ventral surface of corporal bodies and prepuce is spared for preputioplasty. We performed prepucioplasty in all the suitable cases, 32 of 43 patients (75%), where adequate prepuce was available to restore the normal morphology of penis. We did not come across any preputial necrosis or dehiscence in our patients.

Fistula rates using the Mitchell’s total penile disassembly technique range from 10% to 20% [17–19]. Ransley and colleagues [7] reported a fistula rate of 4% while Pippi Salle JL et al. [20] and Surer and associates [21] found that fistula occurred in 19%. Probable reasons for not having fistula in our series were additional cover in the form of spongioplasty with non-overlapping suture line which has corporeal support dorsally. [6] Urethral strictures following the modified Cantwell–Ransley procedure varied from 5% to 10% [7,20,21]; however we didn’t come across this complication in our series. Strictures were prevented by adequate mobilization, avoiding any tension on suture line and preserving dual blood supply to the urethra.

One of the limitations the study is that the cosmetic result was determined by the surgeons who are inherently biased by their involvement with the surgery. In addition, patient’s satisfaction was assessed in follow up visits and the limitation of using non-standardized questionnaires and reporting bias when answering questions in front of their surgeons. We did not measure the exact length of penis and compared it with normal length according to the age in follow up visits; which also remains the limitation.

Conclusions

Partial Penile Disassembly Repair produces a reliable tubularized neourethra with achievement of continence and complete chordee correction through a single surgery avoiding morbidity and cost associated with multiple procedures. Spongioplasty reconstructs near normal urethra and corporoplasty with spongioplasty also helps

in prevention of urethral fistula. This technique tries to restore the penile anatomy nearest to normal to achieve satisfactory cosmesis. Procedure has low complication rate with all the advantages of Modified Cantwell-Ransley Repair and at the same time is less extensive than total penile disassembly.

Conflict of interest

None declared.

Source of funding

None declared.

Ethical committee

Approved by the ethical committee.

Consent from the patient

Consent from the patient.

Authors' contributions

Amilal Bhat: Concepts, Design, Definition of intellectual content, Literature search, Clinical studies, Experimental studies, Data acquisition, Data analysis, Statistical analysis, Manuscript preparation, Manuscript editing, Manuscript review, Guarantor.

Mahakshit Bhat: Concepts, Design, Definition of intellectual content, Literature search, Clinical studies, Experimental studies, Data acquisition, Data analysis, Statistical analysis, Manuscript preparation, Manuscript editing, Manuscript review, Guarantor.

Rajiv Kumar: Concepts, Design, Definition of intellectual content, Literature search, Clinical studies, Experimental studies, Data acquisition, Data analysis, Statistical analysis, Manuscript preparation, Manuscript editing, Manuscript review, Guarantor.

Vinay Kumar: Concepts, Design, Definition of intellectual content, Literature search, Clinical studies, Experimental studies, Data acquisition, Data analysis, Statistical analysis, Manuscript preparation, Manuscript editing, Manuscript review, Guarantor.

References

- [1] Dees JE. Congenital epispadias with incontinence. *J Urol* 1949;62:513–22.
- [2] Kramer SA, Kelalis PP. Assessment of urinary continence in epispadias: review of 94 patients. *J Urol* 1982;128:290–3.
- [3] Narsimhan KL, Mohanty SK, Singh N, et al. Epispadias repair using the Mitchell technique. *J Pediatr Surg* 1999;34:461–3.
- [4] Ransley PG, Duffy PG. Bladder exstrophy closure and epispadias repair. In: Spitz L, Coran AG, editors. *Rob and Smith operative surgery (paediatric surgery)*. London: Chapman and Hall; 1995. p. 745–59.
- [5] Sarin YK, Manchanda V. Mitchell's technique for epispadias repair: our preliminary experience. *J Indian Assoc Pediatr Surg* 2006;11:31–4.
- [6] Bhat AL, Upadhaya R, Bhat M, et al. Double breasting of bladder neck and posterior urethra for continence in isolated peno-pubic epispadias. *Int Urol Nephrol* 2015. <http://dx.doi.org/10.1007/s11255-015-0947-7>.
- [7] Lascaratos J, Poulakou-Rembelakou E, Rembelakos A, et al. The first case of epispadias: an unknown disease of the Byzantine Emperor Heraclius (610–641 AD). *Br J Urol* 1995;76:380–3.
- [8] Gearhart JP, Mathews RI. Exstrophy-epispadias complex. In: Wein AJ, editor. *Campbell-Walsh urology*. 10th ed. Philadelphia: Saunders Elsevier; 2007. p. 3325–57.
- [9] Ebert AK, Reutter H, Ludwig M, et al. The exstrophy-epispadias complex orphanet. *J Rare Dis* 2009;4:23. <http://dx.doi.org/10.1186/1750-1172-4-23>.
- [10] Mokhless I, Youssif M, Ismail HR, et al. Partial penile disassembly for isolated epispadias repair. *Urology* 2008;71:235–8.
- [11] Dieffenbach JF. *Plastische Operationen an den Harwegan. Urethmoplastice*. Die Operative Chirurgie Leipzig: F.A. Bockhaus, 1846;1:526.
- [12] Cantwell FV. Operative treatment of epispadias by transplantation of the Urethra. *Ann Surg* 1895;22:689–93.
- [13] Young HH. A new operation for epispadias. *J Urol* 1918;2:237–51.
- [14] Mays HB. Epispadias: a plan of treatment. *J Urol* 1972;101:251–4.
- [15] Swenson O. *Pediatric surgery*. New York: Appleton-Century Crofts; 1958.
- [16] Woodhouse CRJ, Kellett MJ. Anatomy of the penis and its deformities in exstrophy and epispadias. *J Urol* 1984;132:1122–4.
- [17] Grady RW, Mitchell ME. Complete primary repair of exstrophy. *J Urol* 1999;162:1415–20 [see comments].
- [18] Mitchell ME, Bagli DJ. Complete penile disassembly for epispadias repair: the Mitchell technique. *J Urol* 1996;155:300–4.
- [19] Zaontz MR, Steckler RE, Shortliffe LM, et al. Multicenter experience with the Mitchell technique for epispadias repair. *J Urol* 1998;160:172–6 [see comments].
- [20] Perovic SV, Djordjevic MLJ, Djakovic NG. Penile disassembly technique for Epispadias repair: variants of technique. *J Urol* 1999;162:1181–4.
- [21] Pippi Salle JL, Jednak R, Capolicchio JP, França IMP, Labbie A, Gosalbez R. A ventral rotational skin flap to improve cosmesis and avoid chordee recurrence in epispadias repair. *Br J Urol Int* 2002;90:918–23.