



African Journal of Urology

Official journal of the Pan African Urological Surgeons' Association
web page of the journal

www.ees.elsevier.com/afju
www.sciencedirect.com



Uro-Oncology

Case report

Prostate cancer revealed by skin metastasis: A case report in black African man



K. Tengue^{a,*}, T. Kpatcha^a, E. Sewa^a, K. Sikpa^a, G. Botcho^a,
E. Leloua^a, A. Amavi^b, A. Mouhari-Toure^c, K. Amegbor^d, E. Dosseh^e

^a Departments of Urology, CHU Sylvanus Olympio, Lome, Togo

^b Departments of Oncology, CHU Sylvanus Olympio, Lome, Togo

^c Dermatology Departement, CHU, Kara, Togo

^d Departments of Anatomopathology, CHU Sylvanus Olympio, Lome, Togo

^e Department of General Surgery, CHU Sylvanus Olympio, Lome, Togo

Received 22 June 2016; received in revised form 11 September 2016; accepted 18 October 2016

Available online 23 November 2016

KEYWORDS

Skin metastasis;
Prostate cancer;
Africa

Abstract

Introduction: Prostate cancer is the most common male malignancy in Togo. Most patients present with advanced and metastatic disease. Skin metastasis from prostate cancer is very rare and it occurs late and often with a poor prognosis. We report a case in a 52-year-old Togolese man where the skin lesions reveal the disease and with a good prognosis three years after treatment.

Observation: In 2012, a 52-year-old man presented in dermatology with multiple painless skin nodules on his chest. He did not have lower urinary tract symptoms. The biopsy of the skin lesion (three nodules) showed a metastasis of adenocarcinoma type tumor and tumor markers performed pointed toward prostate as primary site. In urology a diagnostic biopsy (12 cores) of prostate revealed a high-grade (Gleason grade 4+4) adenocarcinoma. We performed a bilateral orchiectomy as androgen deprivation therapy and one month after this treatment the skin lesions have disappeared.

Conclusion: Skin metastasis of prostate cancer is rare and their recognition remains poor among practitioners requiring biopsy of the lesions. The prognosis could be better in newly diagnosed prostate cancer.

© 2016 Pan African Urological Surgeons Association. Production and hosting by Elsevier B.V. This is an open access article under the CC BY-NC-ND license (<http://creativecommons.org/licenses/by-nc-nd/4.0/>).

Abbreviations: ADT, androgen deprivation therapy; PSA, prostate specific antigen; DRE, digital rectal examination.

* Corresponding author at: Urology Department, CHU Sylvanus Olympio, P.O. Box 14148, Lome, Togo.

E-mail addresses: drtengekodjo@yahoo.fr, kevin.tg@yahoo.fr, tengekodjo88@yahoo.fr (K. Tengue).

Peer review under responsibility of Pan African Urological Surgeons' Association.

<http://dx.doi.org/10.1016/j.afju.2016.10.003>

1110-5704/© 2016 Pan African Urological Surgeons Association. Production and hosting by Elsevier B.V. This is an open access article under the CC BY-NC-ND license (<http://creativecommons.org/licenses/by-nc-nd/4.0/>).

Introduction

Prostate cancer is the most common malignant neoplasm in men and the second cause of cancer-related mortality in men after lung cancer [1]. Also in Togo (West Africa) it is the most common cancer in men [2]. In Africa most patients present with advanced and metastatic disease. The common sites of this metastasis are bones and pelvic lymph nodes. Metastasis to skin is rarely reported with a published incidence of 0.36% [3]. Cases in native Africans are very uncommon despite the high incidence of the disease in this population. This skin metastasis usually occurs late in patients who then have a poor prognosis [4].

We hereby report a case where the skin nodules are the first symptoms of the disease and with a clinically durable response three years after treatment by a bilateral orchiectomy.

Case report

In October 2012, a 52 year-old African man presented in dermatology with nodular lesions. On examination, he had multiple subcutaneous nodules on his trunk. He reported that these lesions developed abruptly over a three-weeks period. The nodules were asymptomatic, painless and had not been previously treated. The biopsy of these skin lesions (three nodules) revealed gland-like structures (Fig. 1) which showed that it was a metastasis of an adenocarcinoma type tumor. Tumor markers performed on serum samples pointed toward prostate as primary site [Carcinoembryonic Antigen for colon: 3.6 ng/mL (<10 ng/mL), Carbohydrate Antigen 19-9 for pancreatic tumor: 4, 56 U/mL (<35 U/mL), PSA for prostate cancer: 65 ng/mL (0-4 ng/mL)].

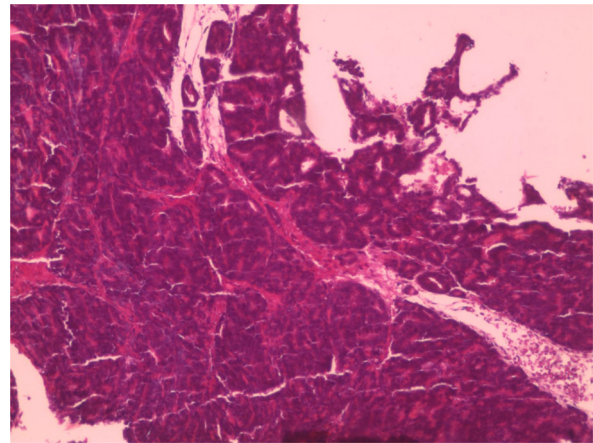


Figure 1 Tumor glands fused giving polyadenoid aspects.

So the patient has been referred to urology for management. He presented to our clinic in urology four months after he had been seen in dermatology. On examination the nodules had spread on the entire chest and the abdomen. He lost weight and was unable to go to work. He did not have lower urinary tract symptoms neither hematuria, nor back pain. There was no illness in the patient history and no prostate cancer disease in the family. On digital rectal examination (DRE), the prostate was enlarged, hard and nodular. His new serum PSA was 96 ng/mL. A diagnostic prostate biopsy (12 cores) revealed a high-grade (Gleason grade 4+4) adenocarcinoma on hematoxylin and eosin section. A CT scan of the chest, abdomen and pelvis revealed no widespread visceral lesions but pelvic lymph nodes dissemination. The bones scintigraphy was not performed because it was not available in the country. So the prostate adenocarcinoma with skin

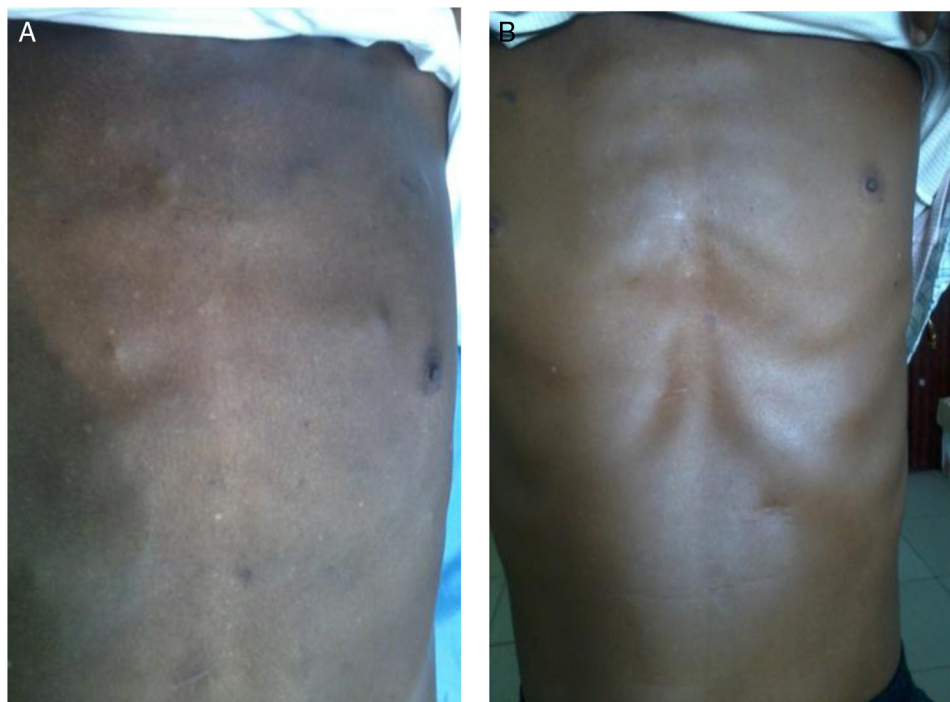

Figure 2 Skin metastatic nodules (A) which disappeared one month after the androgen deprivation therapy (B).

metastasis was confirmed and treatment alternatives were explained and discussed with him.

Then we performed a bilateral orchiectomy as androgen deprivation therapy two weeks after he has been seen in urology. One month after this treatment the skin lesions had disappeared (Fig. 2). Two months later he returned to work. From 96 ng/mL before the treatment, the serum PSA level came down to 12,3 ng/mL after 1 month, to 3,5 ng/mL after 3 months, to 1,4 ng/mL after one year and 0,17 ng/mL after three years.

Discussion

The incidence of prostatic cancer has increased all over the world since the use of prostate specific antigen (PSA) has been adopted as a screening tool. So prostate cancer can now be diagnosed earlier, when the disease is confined to the gland, a condition for which treatments may cure the disease, thereby conferring a good prognosis [5]. However in most African countries, prostate carcinomas are diagnosed late, at the metastatic stage [6] because of the cost of the screening test PSA and the lack of awareness about prostate cancer. Pelvic lymph nodes and bone are the most common sites of metastasis. Nevertheless many other locations have also been identified such as liver, lung, brain. The skin is an uncommon site of metastasis for all cancers and constitutes 5.3% of metastatic sites [3].

Among urologic malignancies, prostate cancer ranks 3rd for metastasis to the skin, after the kidney and the bladder [3]. Skin metastasis from prostate cancer most commonly involve genitalia and suprapubic region [4]. Nowadays, different locations have been described including skin metastasis on head, chest and neck [7,8]. The mechanism of spread of the metastasis is not entirely understood; direct extension, lymphatic and haematogenous spread or combination of these, have all been proposed [3]. Clinically, it has been reported to mimic many other conditions, such as cellulitis, sebaceous cysts, zosteriform lesions, telangiectasias, mammary Paget's disease, Sister Joseph's nodule, basal cell carcinoma, pyoderma, morphea, and more, resulting in poor recognition [9]. The diagnosis is easier if there is a history of prostatic cancer with known disseminated disease. Our patient had no complaints of urinary symptoms and the diagnosis was determined by prostate biopsy analysis on hematoxylin and eosin section after pathologic evaluation of the skin lesion and tumor marker analysis in serum. For our patient the prostate biopsy revealed adenocarcinoma of the prostate.

Therapeutic options for cutaneous metastasis are palliative and include excision, radiation therapy, and intralesional chemotherapy [10]. Such therapies must be carefully selected and used on case by case basis. But it is important to know that the treatment of the primary malignancy may result in regression of those cutaneous metastases. Such as the androgen deprivation therapy performed in our case and other cases. ADT treatments is used for non-organ confined prostate cancer with a drastic decline of circulating PSA together with regression of skin lesions [11].

According to Wang et al. [10] and many other authors [3], the appearance of skin metastases from genitourinary malignancies is associated with a poor prognosis. The average survival is approximately seven months from the presentation of cutaneous metastasis. But this prognosis could be better in a metastasis with a newly diagnosed prostate cancer as in our case and others [12].

Conclusion

Cutaneous metastases from prostate cancer are rare in native Africans. Their clinical appearance may mimic other common dermatologic disorders and definitive diagnosis requires a high index of suspicion and analysis of skin biopsy, tumor marker in serum and in prostate biopsy, especially if there is no history of prostate cancer for the patient and in the family.

Consent

Written informed consent was obtained from the patient for publication of this case report and any accompanying images. A copy of the written consent is available for review by the Editor-in-chief of this journal.

Conflict of interest

The authors declare that they have no conflict of interests.

Authors' contributions

T.K., K.T.M., B.G., L.E., S.K. and S.E. have made contributions to conception and acquisition of data. A.A., M.A. and A.K. have been involved in revising the manuscript critically for important intellectual content. T.K. and D.E. have given final approval of the version to be published and all authors read and approved the final manuscript.

Source of funding

No financial support was received in relation to this article.

Acknowledgments

We thank our patient who has accepted the publication of this case. We thank Dr Ametitovi Joel who has performed the biopsy of the skin lesion and who recommended the patient to our center.

References

- [1] Siegel RL, Miller KD, Jemal A. Cancer statistics, 2015. *CA Cancer J Clin* 2015;65:5–29.
- [2] Darre T, Amegbor K, Kpatcha M, Tengue K, Sonhaye L, Doh K, et al. Cancers urologiques au Togo: profil histoépidémiologique à propos de 678 cas. *J Afr Cancer* 2014;6:27–31.
- [3] Mueller TJ, Wu H, Greenberg RE, Hudes G, Topham N, Lessin SR, et al. Cutaneous metastases from genitourinary malignancies. *Urology* 2004;63:1021–6.
- [4] Reddy S, Bang RH, Contreras ME. Telangiectatic cutaneous metastasis from carcinoma of the prostate. *Br J Dermatol* 2007;156:598–600.
- [5] Salomon L, Azria D, Bastide C, Beuzebec P, Cormier L, Cornud F, et al. Recommendations Onco-Urology 2010: prostate cancer. *Prog Urol* 2010;20:S217–51.
- [6] Gueye SM, Jalloh M, Labou I, Niang L, Kane R, Ndoye M. Profil clinique du cancer de la prostate au Sénégal. *Afr J Urol* 2004;10:203–7.
- [7] Mak G, Chin M, Nahar N, De Souza P. Cutaneous metastasis of prostate carcinoma treated with radiotherapy: a case presentation. *BMC Res Notes* 2014;7:505.
- [8] Brown G, Kurtzman D, Lian F, Sligh J. Eruptive nodules of the head and neck: a case report of metastatic prostate cancer. *Dermatol Online J* 2014;20(2):11.

- [9] Pal D, Talwar V, Doval DC, Yalpota YP, Kumar N. Cutaneous metastasis in prostatic carcinoma. *Indian J Dermatol Venereol Leprol* 2009;75:311–2.
- [10] Wang SQ, Mecca PS, Myskowski PL, Slovin SF. Scrotal and penile papules and plaques as the initial manifestation of a cutaneous metastasis of adenocarcinoma of the prostate: case report and review of the literature. *J Cutan Pathol* 2008;35(July (7)):681–4.
- [11] Perlmutter MA, Lepor H. Androgen deprivation therapy in the treatment of advanced prostate cancer. *Rev Urol* 2007;9(Suppl. 1):53–8.
- [12] Ogunmola AO, Shittu OB, Olapade-Olaopa EO. Cutaneous metastasis from prostate cancer in a nigerian: a case report and literature review. *Afr J Med Sci* 2013;42(September (3)):283–6.