



African Journal of Urology

Official journal of the Pan African Urological Surgeons' Association
web page of the journal

www.ees.elsevier.com/afju
www.sciencedirect.com



Endourology

Original article

Tamsulosin therapy improved the outcome of ureterorenoscopy for lower ureteral stones: A prospective, randomised, controlled, clinical trial



A.S. Abdelaziz^{a,b,*}, A.M. Kidder^{b,c}

^a Faculty of Medicine, Al-Azhar University, Damietta, Cairo, Egypt

^b KSA, Al-Rafie Hospital, El-Siteen Street, P.O. Box 483, Makkah 21955, Saudi Arabia

^c Faculty of Medicine, Zagazig University, Egypt

Received 30 July 2015; received in revised form 22 November 2015; accepted 28 December 2015

Available online 19 November 2016

KEYWORDS

Tamsulosin;
Ureteroscopy;
Ureteral calculi

Abstract

Introduction: Tamsulosin is an α -1A-specific blocker inducing selective relaxation of ureteral smooth muscle and inhibition of ureteral spasms leading to ureteral dilatation that can facilitate retrograde ureterorenoscopy (URS).

Objective: To assess the efficacy of tamsulosin in improving the outcome of URS management of lower ureteral stones.

Patients and methods: This prospective, randomised, controlled, clinical trial was carried out between June 2011 and December 2014. It included 98 patients with lower ureteral stones scheduled for treatment with URS. Before URS, patients were randomly divided into 2 groups; study group including 51 patients, in which pre-URS daily oral dose of tamsulosin 0.4 mg tab, for 1 week, was given and control group including 47 patients who received no additional therapy rather than standard analgesic on demand. The URS outcomes were evaluated and compared between both groups.

Results: The demographic and stone characteristics were comparable between both groups. The mean URS time was significantly shorter in study group than in control group (52.0 ± 14.9 min vs. 71.0 ± 17.3 min; $p=0.039$). Of the 98 patients, 89 (90.81%) had a successful URS procedures. The success rate was

* Corresponding author at: KSA, Al-Rafie Hospital, El-Siteen Street, P.O. Box 483, Makkah 21955, Saudi Arabia.

E-mail addresses: sayedaboyousef@gmail.com, sayedaboyousef4374@yahoo.com (A.S. Abdelaziz), drahmedkhder@gmail.com (A.M. Kidder).

Peer review under responsibility of Pan African Urological Surgeons' Association.

Association.

<http://dx.doi.org/10.1016/j.afju.2015.12.003>

1110-5704/© 2016 Pan African Urological Surgeons Association. Production and hosting by Elsevier B.V. This is an open access article under the CC BY-NC-ND license (<http://creativecommons.org/licenses/by-nc-nd/4.0/>).

94.1% (98/51) in study group compared 89.2% (58/65) in the control group, with statistically significant difference ($p=0.045$). The major complications occurred in 4.25% of patients in control group but in only 1.96% of those received tamsulosin ($p=0.034$).

Conclusion: Post-tamsulosin ureteroscopy was easier and safer; leading to significantly increased stone-free rates and fewer complications.

© 2016 Pan African Urological Surgeons Association. Production and hosting by Elsevier B.V. This is an open access article under the CC BY-NC-ND license (<http://creativecommons.org/licenses/by-nc-nd/4.0/>).

Introduction

Ureterorenoscopy (URS) is one of the most common procedures performed for upper and lower ureteral disorders. However, URS is associated with potential risks and complications [1]. A percentage (5–10%) of patients undergoing URS requires a second procedure for definitive management as the result of failure to access the ureter. The treatment of patients who have undergone a failed URS procedure or who experience complications may be complex [2,3].

Substantial advances in URS have resulted in the procedure being incorporated into routine urological practice in many centres worldwide. An abundance of clinical data and technological progression has enabled the development of novel solutions, which have increased the efficacy of URS and reduced associated morbidity and costs [4].

Ureteroscopic complications are well known, but the predictive factors remain unclear. Careful attention to the selection of instruments and techniques is important to reducing complications related to URS procedures [1].

To facilitate ureteral stone expulsion and decrease post-operative complications, recent studies have recommended a medical expelling therapy (MET) with calcium antagonists, nifedipine, corticosteroids and α -1 blockers [5–7]. Different subtypes of adrenergic receptors, such as α 1a, α 1b and α 1d, have been identified in the distal ureter, with a higher density of α 1d compared to the others. Several studies have demonstrated increased stone expulsion rates for distal ureteral calculi using tamsulosin as a highly selective α 1d adrenoceptor antagonist, which inhibits contraction of ureteral musculature, reduces basal tone, decreases peristaltic frequency and amplitude and decreases intraluminal pressure [5–8]. Based on these observations, we hypothesised that MET with α -1d blocker before endoscopic treatment of ureteral stones may increase the success rate of the procedure and decrease operative complications. The present study aimed to evaluate the efficacy of tamsulosin therapy on the feasibility and success rate of URS management for lower ureteral stones.

Patients and methods

After receiving local institutional review board approval, this prospective, randomised, controlled clinical trial was performed from June 2011 to December 2014. The study protocol was explained to all participants, and they provided written informed consent prior to inclusion.

All patients ≥ 18 years old with a single, radio opaque, lower ureteral stone, 5–10 mm in maximum diameter were included in the study. Patients were evaluated via medical histories, physical examinations and laboratory investigations in the form of complete urine

analysis, urine culture, blood urea and serum creatinine, complete blood cell count, liver function tests and coagulation profile. In addition, abdominal X-rays for kidneys, ureters and urinary bladder (KUB), urinary ultrasonography and intravenous urography (IVU) and/or abdominal computed tomography (CT) were performed in all patients. Pregnant women and patients with a history of endoscopic or open ureteral surgery, persistent renal pain, urinary tract infection (UTI), renal impairment, solitary kidney, bilateral ureteral stones, high-grade hydronephrosis and those on or with hypersensitivity to α -blockers were excluded from the study.

Patients were randomised into two equal groups using a coin toss. In the study group, patients received a daily oral dose of tamsulosin (0.4 mg) for one week before URS, whereas no active treatment was given to members of the control group. All patients were asked to take analgesics (NSAIDs) for moderate and severe pain.

Operative technique

Under spinal or general anaesthesia, cystoscopy was initially carried out to identify the ureteral orifice. A floppy-tipped guidewire (0.038 in.) was inserted into the ureter. After the guidewire was placed, URS was performed using a 7.5 F semi-rigid ureterorenoscope (Karl Storz, Tuttlingen, Germany). Ureteral dilatation was not routinely performed during ureteroscopy except when the truly stenotic ureteric orifice was encountered. Ureteral dilatation was done by balloon dilation systems, which were introduced into the ureter over a guidewire. Disintegration using the Swiss pneumatic lithoclast was performed, and the stone gravel was retrieved using a Dormia basket and/or grasper forceps to ensure removal of all sizable gravel. A ureteric stent was inserted at the end of the procedure for a period of 1–2 days. Internal stents (JJ) were placed for 4–6 weeks in cases with intra-operative complications (e.g. ureteral perforation, false passage) and in solitary kidney patients. The procedure site was covered with perioperative antibiotics and analgesics.

Follow-up and outcome measurements

All patients were evaluated with X-ray KUB and urinary ultrasonography 24 h and 2 weeks after URS. The primary endpoint was URS success, which was defined as no evidence of residual stones >2 mm in diameter and no or minimal complications. The operative time, fluoroscopy time, peri-operative complications, stone-free rate, use of ureteral stents and hospital stay were recorded. The URS complications were reported according to the modified Clavien grading system. Grade I (events without adverse consequences for the patient), grade II (complications comprising blood transfusions or urinary tract infection), grade IIIa (complications requiring intervention under local anaesthesia), grade IIIb (complications requiring intervention under general anaesthesia), grade IVb (single organ

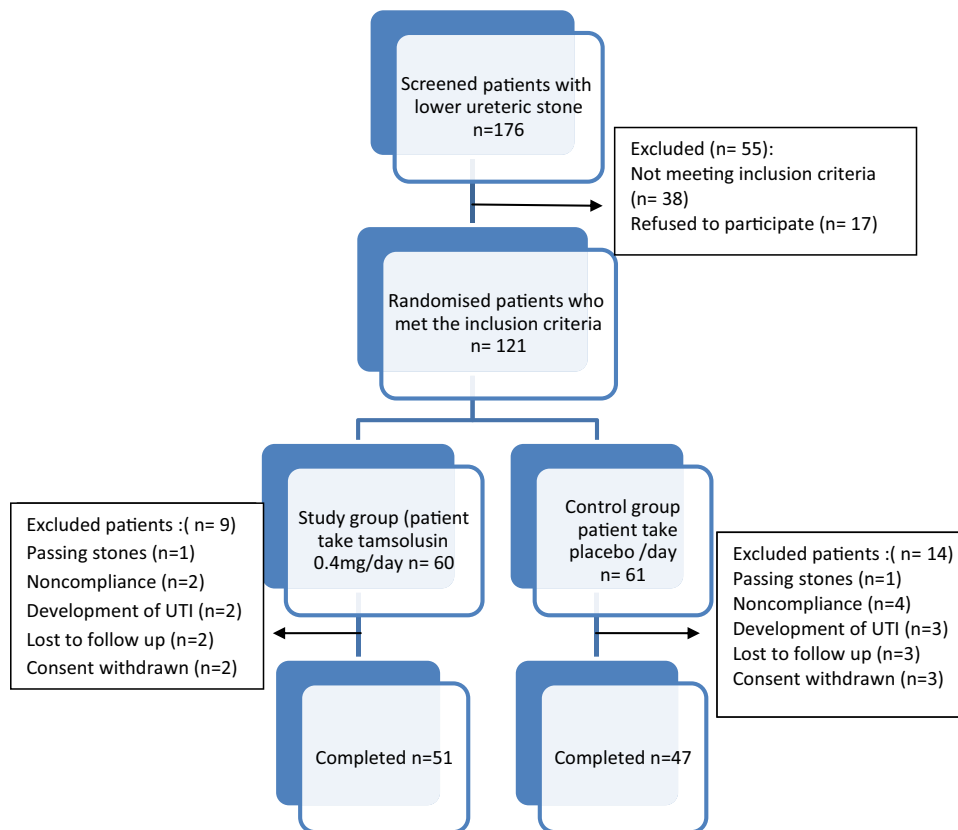


Figure 1 Patient randomisation and disposition.

dysfunction, such as myocardial infarction and renal failure), grade IVb (urosepsis or multi organ dysfunction) and grade V (death) [9].

Statistical analysis

Data analysis was performed using the software programme SPSS 17.0 for Windows XP. The *t*-test and Mann–Whitney test were used for comparison of the numerical variables. The categorical variables were compared using the chi-square and Fisher exact test. Significance was considered as a *p*-value <0.05.

Results

A total of 121 patients met the inclusion criteria; 23 patients were excluded due to noncompliance issues, development of pre-intervention UTIs, passing stones or lost follow-up. Hence, 98 patients were ultimately included: 51 patients in the study group and 47 patients in the control group (Fig. 1). There were no statistically significant differences between patients in the two groups in regard to their demographic and stone characteristics (Table 1).

Operative time was significantly shorter in the study group (52.0 ± 14.9 min vs. 71.0 ± 17.3 min; $p = 0.039$), and most patients in this group did not require ureteral dilatation during URS (82.35% vs. 42.55%; $p = 0.024$). The mean hospitalisation time, operative time and the need for ureteral dilatation and stenting in both groups are demonstrated in Table 2.

Out of 98 patients, 89 (90.81%) were successfully managed by URS in the first session while five (5.10%) were cured in the second session. The overall success rate was significantly higher in the study group compared to the control group (94.11% vs. 87.23%; $p = 0.045$). Failure of the first URS procedure occurred in nine (9.18%) cases: due to the failure to pass the guidewire in three (3.06%), failure of ureteral dilatation in three (3.06), stone migration in two (2.04%) and ureteral perforation prior to stone extraction in one case (1.02%). During the second URS session, one out of six cases had a URS failure due to perforation of the ureter. The overall failure rate was significantly higher in the control group than in the study group (six vs. three; $p = 0.041$). The URS success and failure rates are shown in Table 3.

The overall complication rate was 14.28%, affecting six (11.76%) patients in the study group and nine (19.14%) in the control group. In the study group, three patients showed grade I complications, one showed grade II complications, one showed grade IIIa complications and one showed grade IIIb complications. In the control group, five patients showed grade I complications, one showed grade II complications, one showed grade IIIa complications and two showed grade IIIb complications (Table 4). All reported complications were successfully managed either conservatively or endoscopically.

Discussion

Recent advances in endourology techniques and new instrumentation have largely shifted the treatment of ureteral stones away from open surgery to either minimally invasive methods (e.g. ESWL and

Table 1 Characteristics data in patients submitted to ureteroscopy in both groups.

Characteristics	Patients	Treatment groups (n = 98)		p Value
		Study group	Control group	
Patient, n	98	51	47	0.791
Age, mean \pm SD, y	36.27 \pm 6.7	35	38	0.818
Sex, n (%)	Male	64	30	0.812
	Female	34	17	0.505
Side	Right	45	22	0.592
	Left	53	25	0.611
Stone size mean \pm SD/mm	6.4 \pm 2.7 (4–9)	6.6 \pm 2.3 (5–9)	6.2 \pm 3.2 (4–9)	0.631

Table 2 Intra-operative characteristics of patients.

	Study group (n = 51)	Control group (n = 47)	Overall (n = 98)	p Value	
Operative time (min)	52.0 \pm 14.9	71.0 \pm 17.3	60.2 \pm 15.1	0.039*	
Fluoroscopy time (s)	71.7 \pm 62.6	86.0 \pm 80.1	79.2 \pm 76.0	0.049*	
Ureteral dilatation % (n)	17.64 (9)	48.29 (27)	36.73 (36)	0.041*	
Complications % (n)	Major	4.25 (2)	3.06 (3)	0.040*	
	Minor	7.84 (4)	11.7 (5)	10.01 (9)	0.076
Stone free % (n)	94.11 (48)	87.23 (41)	90.81 (89)	0.045*	
Ureteral stent % (n)	Catheter	58.82 (30)	72.34 (34)	65.30 (64)	0.047*
	JJ	11.76 (6)	19.14 (9)	15.3 (15)	0.045*
	No stent	29.41 (15)	8.51 (4)	19.38 (19)	0.029*
Length of stay (days)	1.2 \pm 0.6	1.7 \pm 0.9	1.3 \pm 0.8	0.072	
Retreatment or secondary intervention	URS	3 (5.88%)	6 (12.76%)	9 (9.18%)	0.041*
	SWL	1 (1.96%)	1 (2.12%)	2 (2.04%)	0.041*
	Ureterolithotomy	0	2 (4.25%)	2 (2.04%)	0.011*

* p < 0.05; p value by Student's *t*-test and chi-square test.

Table 3 Characteristics of success (free stone) and retreatment of patients with failed initial procedure.

Retreatment patients		Initial ureteroscopy		Re-ureteroscopy		Others modalities			
		Study group (n = 51)	Control group (n = 47)	Study group (n = 2)	Control group (n = 4)	ESWL		Ureterolithotomy	
						Study group (n = 1)	Control group (n = 1)	Study group (n = 0)	Control group (n = 2)
Identification of ureteric orifice	Success	50	45	2	4	0	0	0	0
	Failed	1	2	0	0	0	0	0	0
Dilatation of ureter	Not need	16	4	0	0	0	0	0	0
	Success	33	39	2	4	0	0	0	0
Stone migrations	Failed	1	2	0	0	0	0	0	1
	No	48	41	2	4	0	0	0	0
Perforation of ureter	Yes	1	1	0	0	1	1	0	0
	No	49	41	2	3	0	0	0	0
Total stone free	Yes	1	2	0	1	0	0	0	1
	Success	48	41	2	3	1	1	0	2
	Failed	3	6	0	1	0	0	0	0

URS) or even watchful waiting. Moreover, accurate prediction of stone passage may prevent unnecessary intervention and possible complications, especially for distal ureteric stones. The choice of the ideal type of therapy is largely related to the type of equipment available, the type, size, position, degree of impaction and obstruction of the stone, patient preference and the skills and experiences of the surgeon [10,11]. Current guidelines recommend ureteroscopy over other treatments including SWL for the majority of ureteric stones [6].

Although ureteral stones less than 5 mm could pass in up to 98% of cases, fragmented stones following lithotripsy interventions cause some degree of ureteral wall congestion and oedema, interfering with straight gravel passing and even leading to stone impaction and obstruction. Thus, the use of MET necessitates stone passage and decreases the time for spontaneous gravel passage as well as reducing possible risks of renal damage due to prolonged partial ureteral obstruction (greater than 4–6 weeks) and persistent pain or UTI [12,13].

Table 4 The complications and their grades according to the MCCS.^a

Grade	Complications	Study group (n = 51)	Control group (n = 47)	Overall (n = 98)	p Value	
Minor	Grade I	Mucosal injuries	1	1	2	0.505
		Hematuria	1	2	3	0.034 ^a
		Urine retentions	0	1	1	0.024 ^a
		Mechanical failure	1	1	2	0.505
Major	Grade II Grade IIIa Grade IIIb Grade IVa Grade IVb Grade V	Urinary tract infections	1	1	2	0.024 ^a
		Proximal stone migrations	1	1	2	0.505
		Ureteral perforation	1	2	3	0.034 ^a
		Myocardial infarction, pulmonary embolism	0	0	0	0.0
		Urosepsis	0	0	0	0.0
		Death	0	0	0	0.0

^a MCCS: modified Clavien classification system.

Many recent studies have demonstrated excellent results of MET use for distal ureteral stones. In terms of stone expulsion and control of ureteric colic pain, drugs (e.g. calcium channel blockers, nifedipine, corticosteroids, $\alpha 1$ blockers) that can modulate the function of the ureter, which may be obstructed by a stone, can be used. Alpha-1 blockers, in particular $\alpha 1A$ blockers (e.g. tamsulosin), are preferred due to the prevalence of a specific adrenoceptor subtype in the distal part of the ureter. Tamsulosin acts by relaxing the ureteral wall muscle, facilitating gravel expulsion after lithotripsy and aiding the forwarding of instruments through the ureter for improved stone access [10].

Since stone size is the most important factor in all intervention procedures, URS has higher efficacy and success rates than ESWL, but it is more expensive and more invasive [11]. If adjunct therapy such as MET is used before or when the ureteroscope is advanced prior to accessing the stone, these complications can be reduced.

Many recent studies have demonstrated that the efficacy of α -blockers is preferred to the other MET's efficacies after ESWL procedures for proximal ureter stones and the passing of lower ureter stones. Moreover, α -blockers, especially tamsulosin, which is a highly selective sympatholytic agent, may reduce complications after stone breaking and gravel passing in all lithotripsy procedures [14–16].

The exact mechanism of action of α -blockers on the ureteral smooth muscle involves an increase in the expulsion rate of stones or a decrease in the time it takes for stone expulsion, which suggests that α -adrenergic receptor antagonists should be the preferred MET for distal stone expulsion [16].

The research group prospectively analysed different factors that might affect the success and complications of managing ureteric stones with URS. They found that endoscopic interventions without preparation with tamsulosin were associated with increased complication or failure rates. The overall complication rate after URS was 13.07%. Major complications in the form of ureteric perforations were recorded in three cases (3%): one in group A and two in group B, and all patients were stented.

Regarding the modified Clavien classification system, major complications did not occur in our study. However, minor and moderate complications (Grades I, II and III) were reported in 13.07% of all patients, consisting of mucosal injuries, haematuria, UTIs or ureteral

perforation, which significantly decreased in the study group prepared with tamsulosin. Two cases of ureteral perforation occurred with impacted distal ureteric stones (one from each group), and they were successfully managed by ureteroscopy after six weeks. Only one shifted to open after a failed second ureteroscopy.

Stone migration was seen in two patients (2.04%). Due to equipment failure (shortage of equipment for follow-up of the migrating stones, such as flexible ureteroscopy and laser lithotripsy for fragmenting or extracting the migrating stones), one patient from each group underwent successful re-ureteroscopy and stone removal. In addition, ureteroscopy was abandoned in two cases in the control group (4.25%) due to insufficient ureteric orifice dilatation.

There was a significantly higher failure rate in the endoscopic procedures in the control group (12.76%) compared to the study group (5.8%). The overall success rate in the present study was 90.8% (94.1% and 87.2% in the study and control groups, respectively). An 87% stone-free rate has been reported following a single ureteroscopy intervention [17,18].

The researcher noted that the ureteroscopy in patients on tamsulosin was more accessible as the ureteral orifice was more open, dilated, easily visualised and easily intubated without the assistance of a guide wire. Thus, the intramural ureter can be approached employing a 'no-touch' technique without ureteral dilatation, which eliminates the potential trauma, mucosal irritation, and inadvertent manipulation of stones or tumours caused by guidewires and is particularly helpful when the collection system is evaluated for mucosal/intra-luminal lesions.

In patients on tamsulosin, the ureteric orifices were easily identified and dilated and the ureteroscope could be inserted easily, wirelessly or over a guidewire, without dilatation, primarily due to the muscle-relaxing effect of tamsulosin. The present study showed that the necessary degree of ureteric orifice dilatation varied significantly between the two groups. The ureteric orifice was dilated up to 12 F in 9 patients (17.64%) in the study group and in 27 patients (48.29%) in the control group.

The important findings of this research were recorded. First, short operative time was observed when patients were prepared pre-operatively with tamsulosin. This observation may help to explain the difficulties sometimes faced in regard to entering the ureter and overcoming kinking in the ureter resulting from chronic obstruction

from ureteric stones, which has an effect on endoscopic stone management. Therefore, pre-endoscopic preparations might be advised, particularly in non-urgent cases.

Second, there may be benefits when operating on older male patients, including decreased operative time and straightening and aligning of the prostatic urethra.

Third, there were fewer complications and the success rates were higher when patients were prepared for short periods with tamsulosin, which acts as a therapeutic medication in addition to its role in URS preparation.

This was a blinded study. The surgeon was not aware of the use of preparation medications to avoid the effect of this knowledge on the results of the surgical procedures. However, our study has some limitations. First, relatively few patients were included in each group. Second, the exact timing of the endoscopic steps, such as bladder access, ureteral access, lithotripsy and ureteral stenting, as well as subjective experiences and stone factors such as stone composition, were not evaluated in the present study. Thus, the results of this study should be considered as preliminary data, which requires confirmation with a larger sample size in the future.

Conclusions

Post-tamsulosin ureteroscopy was easier and safer; leading to significantly increased stone-free rates and fewer complications.

Conflict of interest

We do not have conflict of interest in our study.

Source of funding

None.

References

- [1] Tanriverdi O, Silay MS, Kadihasanoglu M, Aydin M, Kendirci M, Miroglu C. Revisiting the predictive factors for intra-operative complications of rigid ureteroscopy: a 15-year experience. *Urol J* 2012;9(Spring (2)):457–64.
- [2] Changwei J, Weidong G, Hongqian G, Huibo L, Shiwei Z, Xiaozhi Z, et al. A prospective trial on ureteral stenting combined with secondary ureteroscopy after an initial failed procedure. *Urol Res* 2012;40(October (5)):593–8.
- [3] Singal Rajiv K, Razvi Hassan A, Denstedt John D. Secondary ureteroscopy: results and management strategy at a referral center. *J Urol* 1998;159(1):52–5.
- [4] Geavlete P, Multescu R, Geavlete B. Pushing the boundaries of ureteroscopy: current status and future perspectives. *Nat Rev Urol* 2014;11(7):373–82.
- [5] Bader MJ, Eisner B, Porpiglia F, Preminger GM, Tiselius HG. Contemporary management of ureteral stones. *Eur Urol* 2012;61(4):764–72.
- [6] Zhang M, Ding S, Lu J, Lue Y, Zhang H, Xia Q. Comparison of tamsulosin with extracorporeal shock wave lithotripsy in treating distal ureteral stones. *Chin Med J* 2009;122(7):798–801.
- [7] Ketabchi Ali Asghar, Mehrabi Soha. The effect of tamsulosin, an alpha-1 receptor antagonist as a medical expelling agent in success rate of ureteroscopic lithotripsy. *Nephrourol Mon* 2014;6(1):128–36.
- [8] Badran Yasser A, Ali Tamer A, Abd Elaal Mohamed A, Ali Mahmud, Jamal Adil, Farouk Ahmed. Role of tamsulosin oral control absorption system and alfuzosin in shock wave lithotripsy for renal and upper ureteric calculi. *J Am Sci* 2013;9(6):387–93.
- [9] Mandal S, Goel A, Singh MK, Kathpalia R, Nagathan DS, Sankhwar SN, et al. Clavien classification of semirigid ureteroscopy complications: a prospective study. *Urology* 2012;80(November (5)):995–1001.
- [10] Griwan MS, Singh SK, Paul H, Pawar DS, Verma M. The efficacy of tamsulosin in lower ureteral calculi. *Urol Ann* 2010;2(2):63–6.
- [11] Turk C, Knoll T, Petrik, Sarica K, Skolarikos A, Straub M, et al. Guidelines on urolithiasis. EAU; 2014 <http://www.uroweb.org/gls/pdf/22Urolithiasis>.
- [12] Miller OF, Kane CJ. Time to stone passage for observed ureteral calculi: a guide for patient education. *J Urol* 1999;162(3 Pt. 1):688–90.
- [13] Samplaski MK, Irwin BH, Desai M. Less-invasive ways to remove stones from the kidneys and ureters. *Cleve Clin J Med* 2009;76(10):592–8.
- [14] Singh SK, Pawar DS, Griwan MS, Indora JM, Sharma S. Role of tamsulosin in clearance of upper ureteral calculi after extracorporeal shock wave lithotripsy: a randomized controlled trial. *Urol J* 2011;8(1):14–20.
- [15] Sayed MA, Abolyosr A, Abdalla MA, El-Azab AS. Efficacy of tamsulosin in medical expulsive therapy for distal ureteral calculi. *Scand J Urol Nephrol* 2008;42(1):59–62.
- [16] Tzortzis V, Mamoulakis C, Rioja J, Gravas S, Michel MC, de la Rosette JJ. Medical expulsive therapy for distal ureteral stones. *Drugs* 2009;69(6):677–92.
- [17] El-Nahas AR, El-Tabey NA, Eraky I, Shoma AM, El-Hefnawy AM, El-Assmy AM, et al. Semirigid ureteroscopy for ureteral stones: a multivariate analysis of unfavorable results. *J Urol* 2009;181:1158–62.
- [18] de la Rosette J, Denstedt J, Geavlete P, Keeley F, Matsuda T, Pearle M, et al. The clinical research office of the endourological society ureteroscopy global study: indications, complications, and outcomes in 11,885 patients. *J Endourol* 2014;28:131–9.