



## African Journal of Urology

Official journal of the Pan African Urological Surgeons' Association  
web page of the journal

[www.ees.elsevier.com/afju](http://www.ees.elsevier.com/afju)  
[www.sciencedirect.com](http://www.sciencedirect.com)



### Pediatric Urology

Original article

# Management of the exstrophy-epispadias complex in adolescents and adults



A. Jana\*, K. Maiti, T.K. Mondal, T.K. Majhi

Nilratan Sircar Medical College and Hospital, Kolkata, West Bengal, India

Received 15 December 2015; received in revised form 10 July 2016; accepted 2 September 2016

Available online 15 March 2017

#### KEYWORDS

Exstrophy-epispadias complex;  
Adolescent;  
Adulthood

#### Abstract

**Objectives:** To study the presentation and management of the exstrophy-epispadias complex in adolescents and adults and to evaluate the outcome of the repair.

**Subjects and methods:** This retrospective review of our medical records of adult patients with an exstrophy-epispadias complex managed between January 2010 and June 2015 included one female and 7 male patients. Only patients aged above 10 years who had not undergone any surgical treatment during childhood were included in the study. All patients were subjected to preoperative biopsy from the urinary bladder plate. None of them underwent cystectomy. Seven patients underwent urinary bladder augmentation using ileo-cystoplasty, bladder neck reconstruction with para-urethral tissue closure using a wedge of pubic bone, and single-stage epispadias repair. In one patient epispadias repair was not done due to intraoperative hemodynamic instability.

**Results:** All patients are continent but one in whom epispadias repair was not done and who is waiting for epispadias repair. One patient has developed a urethro-cutaneous fistula at the base of the penis. Two patients developed urinary bladder stones, and both of them were managed by minimally invasive methods. All the patients are on clean intermittent self-catheterization. They are all doing well socially and psychologically.

**Conclusion:** Though exstrophy-epispadias in adolescents and adults is a rare entity, the described modified surgical technique provides good results and improves the patients' social and psychological well being.

© 2016 Pan African Urological Surgeons' Association. Production and hosting by Elsevier B.V. This is an open access article under the CC BY-NC-ND license (<http://creativecommons.org/licenses/by-nc-nd/4.0/>).

#### Introduction

The exstrophy-epispadias complex is a rare congenital malformation with a wide spectrum of clinical features. It can be considered one of the most difficult entities encountered by pediatric surgeons or urologists. The incidence of this entity which has been estimated to range between 1 in 10,000 and 1 in 50,000 live births [1] is rare,

\* Corresponding author.

E-mail addresses: [atanu83ms09@gmail.com](mailto:atanu83ms09@gmail.com) (A. Jana), [maiti.krishnendu@rediffmail.com](mailto:maiti.krishnendu@rediffmail.com) (K. Maiti), [drtapanmondal@yahoo.co.in](mailto:drtapanmondal@yahoo.co.in) (T.K. Mondal), [drtapasuro@gmail.com](mailto:drtapasuro@gmail.com) (T.K. Majhi).

Peer review under responsibility of Pan African Urological Surgeons' Association.

<http://dx.doi.org/10.1016/j.afju.2016.09.001>

1110-5704/© 2016 Pan African Urological Surgeons' Association. Production and hosting by Elsevier B.V. This is an open access article under the CC BY-NC-ND license (<http://creativecommons.org/licenses/by-nc-nd/4.0/>).

but it presents a significant physical, functional, social, sexual and psychological burden for the patients and their families. The male-to-female ratio of bladder exstrophy derived from multiple series is 2.3:1 [2].

Although it is a congenital malformation showing very obvious defects, patients sometimes present to the urologist in adulthood, especially on the Indian subcontinent. This is due to a lack of knowledge, to financial constraints and many other social factors. When started right after birth, reconstructive management of the exstrophy-epispadias complex will yield satisfactory results. The primary objective is to convert the bladder exstrophy into a complete epispadias. The resultant incontinence with balanced posterior outlet resistance not only preserves renal function but also stimulates bladder growth. Typically, epispadias repair is then performed at around six months of age. Bladder neck repair is usually done when the child is four to five years of age. At that time the child has an adequate bladder capacity, and, most importantly, is ready to participate in a postoperative voiding program. It has been claimed that, using repair methods such as the Erlangen, Kelly and complete primary repair of exstrophy (CPRE), continence can be achieved without the need for bladder neck repair, but recent reports have shown the need for an outlet procedure in most patients [1–8]. Due to its exposure to the environment, the exstrophic bladder has a potential for developing malignancy when left untreated for a longer period [9]. The literature on the incidence of adolescent and adult patients with bladder exstrophy is scarce. Herein we report a case series of eight adolescent and adult patients with a bladder exstrophy-epispadias complex who have been treated at our institute.

## Subjects and methods

This retrospective review included the medical records of 8 patients with an exstrophy-epispadias complex managed between January 2010 and June 2015 at our institute. Only patients above 10 years of age at presentation who had not undergone any surgical treatment during childhood were included. Our study group consisted of 1 female and 7 male patients with a mean age at presentation of 17 (range 11–25) years. They all were from a rural background. Five patients were students, while the female patient was a school dropout and was doing household work at the time of presentation. The remaining two patients had not been admitted to school yet. Financial constraints presented the main reason for not seeking medical help earlier. The patients' mental growth and performance at school coincided with their age. They all attended our hospital with the financial help of villagers. The institution provided the entire treatment free of charge.

At presentation in our department, the patients were subjected to laboratory investigations (e.g., complete hemogram, renal function test) and upper tract imaging in the form of ultrasound scan and X-ray of the pelvis.

All patients were informed about the details of the operative procedure and also counselled about the need for clean intermittent self-catheterization (CISC) at regular intervals.

Prior to the definitive procedure, all patients underwent random biopsy from the bladder plate to rule out malignancy

or premalignant changes. None of the patients underwent cystectomy.

Seven patients underwent single-stage complete repair of the exstrophy-epispadias complex, using ileocystoplasty for bladder augmentation without re-implantation of the ureter, para-urethral soft tissue for bladder neck reconstruction and the modified Cantwell-Ransley [10] method for epispadias repair, and abdominal closure without a flap. Bladder neck reconstruction was done by closing the para-urethral tissue with a wedge of pubic bone after performing minimal superior pubic osteotomy. No wedge of the pubis was excised, so no impairment of hip development and walking abilities was to be expected. In one patient epispadias repair was not done due to intraoperative hemodynamic instability. In all patients, the procedure was concluded by primary abdominal closure. In the female patient, the mons pubis was created from local soft tissue (Figs. 1–6).

The patients were discharged after removal of the abdominal drain, urethral stent and suprapubic catheter. All patients were instructed to perform CISC at fixed intervals and after each episode of voiding, to empty the bladder completely, during the first six months.

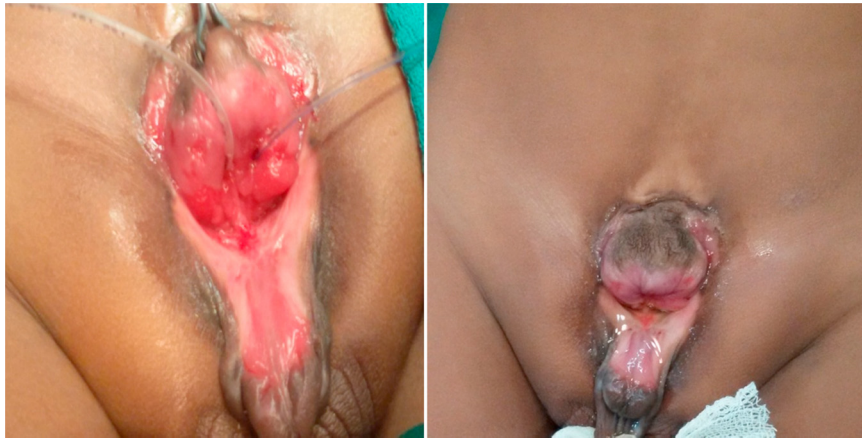All patients were followed up at regular intervals with urine analysis and abdominal ultrasound. They were also interviewed with regard to their psychological and social well-being and their sexual function.

## Results

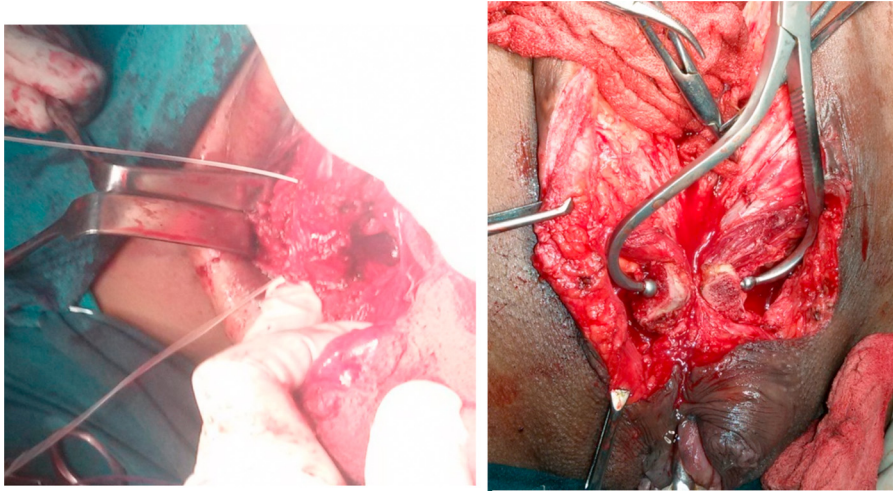
The mean follow up of the patients has been three years. Follow-up investigations include abdominal ultrasound and the evaluation of post-void residual urine. The patients received prophylactic antibiotic medication for the first 6 months. After that, antibiotics have only been continued in patients symptomatic for urinary tract infection (UTI). A micturating cysto-urethrogram (MCU) was not routinely performed. All our patients developed reflux after bladder closure, however reflux in the adult is of minor significance as it does not lead to permanent renal damage or scarring. There may be an increased incidence of recurrent infection due to reflux which can, however, be treated with antibiotics.

The patients were advised to perform regular CISC during the initial 6 months. After this time, mucus production usually diminishes due to changes in the intestinal epithelium. Consequently, the patients require CISC rather infrequently later on.

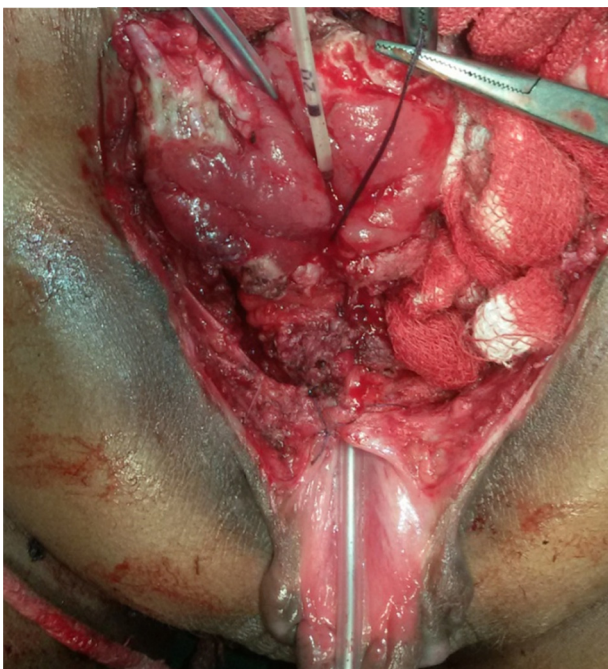
At present, the patients' bladder capacity ranges from 300 to 450 ml. All patients are continent but one in whom epispadias repair was not performed. One patient who has developed a urethro-cutaneous fistula at the base of the penis is awaiting repair. Two patients developed urinary bladder stones, and both of them were managed by minimally invasive methods (one patient with percutaneous cystolitholapaxy (PCCL) and the other with LASER cystolithotripsy). The scar of the anterior abdominal wall is healthy in all patients. Four patients give a history of adequate erection, though none of them are married yet. Two of them complain about some amount of lateral chordee. The female patient is satisfied with the appearance of her external genitalia. All patients are doing well socially and psychologically.



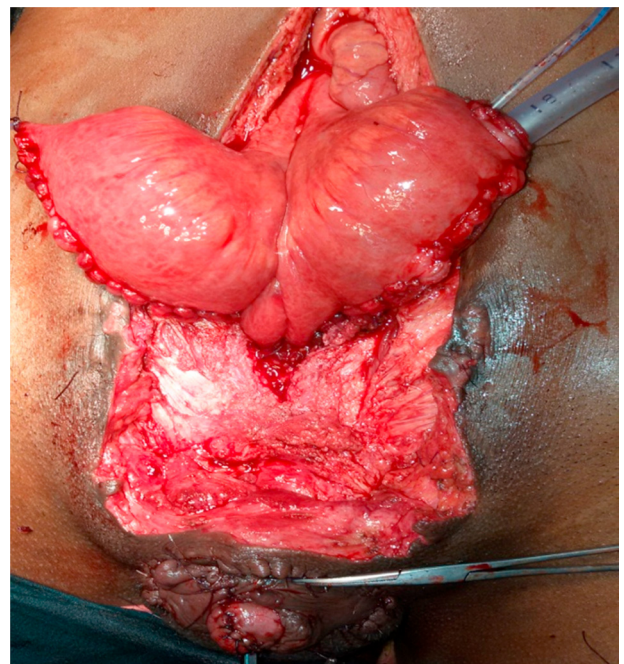
**Figure 1** Pre-operative picture of complete exstrophy-epispadias complex.



**Figure 2** Superior pubotomy.

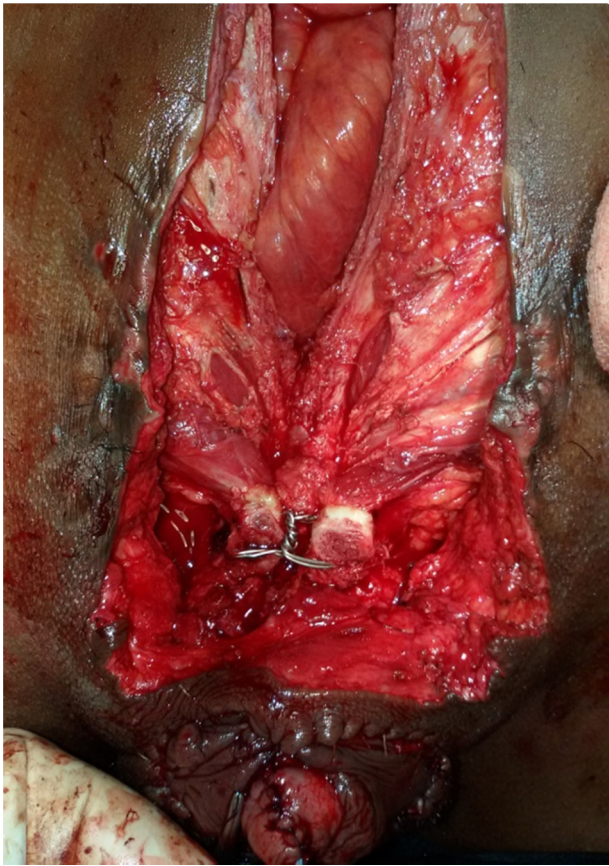


**Figure 3** Bladder neck closure with para-urethral tissue.



**Figure 4** Ileocystoplasty.





**Figure 5** Pubotomy closure.

## Discussion

Initial management of the exstrophy-epispadias complex is usually started at birth with an assessment of the general condition of the neonate. The principle of surgical correction addresses not only the mere closure of the urinary bladder and urethral closure, but also the basic anatomical defect of the disease. Osteotomy is one of the most important steps of surgery for the future continent mechanism. Nowadays, there are two ways of correction: a modern stage repair and a single-stage repair. However, there is no head-to-head comparison of the results of these two procedures. The basic steps are: osteotomy, closure of the urinary bladder, bladder neck reconstruction, epispadias repair and secure abdominal closure. All these procedures have been tested in the pediatric population. But literature on exstrophy-epispadias repair in adults is very sparse. Previously, the bladder template was excised and any kind of

diversion was the preferred option. According to earlier reports, adult patients with bladder exstrophy were reliably and safely managed with bladder neck closure along with continent cutaneous diversion. This can provide acceptable continence without the need for multiple complex and expensive surgeries [11].

While osteotomy is mandatory in pediatric patients, repair can be possible without osteotomy in adults. Mansour [12] et al. showed that abdominal closure without osteotomy is possible when using the primitive bladder muscle plate and urinary diversion in a single stage.

We performed superior pubotomy just lateral to the insertion of the rectus muscles for the ease of abdominal closure.

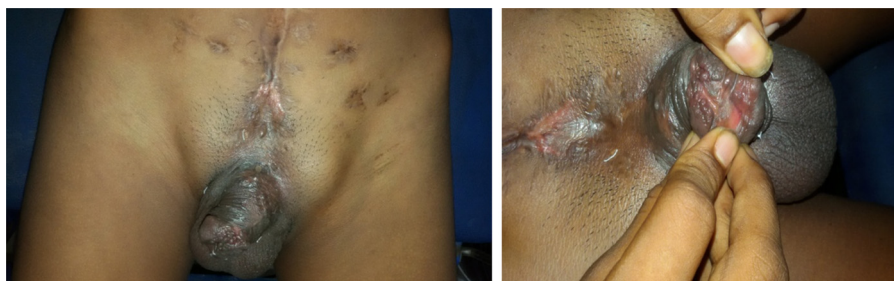Pathak et al. [13] presented their experience of vesical preservation in a small series of adult patients. They treated the patients using ileocystoplasty, bladder neck reconstruction and abdominal wall closure with flaps. They also showed that abdominal closure can be possible without transposition flaps.

We did not excise the bladder template. Our patients underwent a single-stage procedure, and the bladder template was used for ileocystoplasty. After closure of the exstrophy, 100% of the patients develop reflux by rule, and antibiotic prophylaxis should be given. As we use a bowel segment for bladder augmentation, normally a low pressure system is generated. Also, asymptomatic reflux in adults is not really significant. The bladder capacity of the augmented bladder is higher than that of the non-augmented bladder. The most important factor for continence in this group of patients is the bladder capacity. Our patients are all continent as they have an average bladder capacity around 400 ml.

According to Gearhart [14], using the bladder template has a dual advantage: firstly, the requirement of bowel segment is less and secondly, if ureteric re-implantation is required, the native bladder template is a better substrate than the bowel wall.

Possible malignancy in the preserved bladder plate is one concern. Therefore, all our patients were subjected to a pre-operative biopsy to rule out malignancy and pre-malignant changes in the exposed bladder template. Though early closure does not necessarily prevent malignancy at a later time, it takes a longer time to develop malignancy. For this reason, the patients are usually followed up with cystoscopy, starting after 5 years from operation. Our patients are on regular follow up to detect any malignancy at an early stage.

Our study showed that the preservation of the bladder template, limited osteotomy, para-urethral tissue support to the bladder neck



**Figure 6** Post-operative picture after 4 years.

and abdominal closure are a possible method for the management of the exstrophy-epispadias complex in adolescents and adults.

### Conclusion

The exstrophy-epispadias complex in adolescents and adults is a rare entity. A modified surgical technique yields encouraging results providing improved social and psychological conditions for most patients.

### Ethical committee approval

It is a retrospective study and analysis of the authors' medical record and followed up of the patients, the authors did not seek for ethical committee clearance.

### Conflict of interest

The authors have no conflict of interest to declare.

### Source of funding

There is no source of funding to disclose.

### Authors' contributions

Atanu Jana, in association with Krishnendu Maiti, Tapan Kumar Mandal, and Tapas Kumar Majhi, conceptualized and designed the study, as well as wrote the manuscript. In addition, he conducted the clinical and experimental studies and analyzed the data.

### References

- [1] Lattimer JK, Smith MJ. Exstrophy closure: a follow-up on 70 cases. *J Urol* 1966;95:356–9.
- [2] Lancaster PA. Epidemiology of bladder exstrophy: a communication from the International Clearinghouse for Birth Defects Monitoring Systems. *Teratology* 1987;36:221–7.
- [3] Rösch WH, Schott G, Scheuring S, Schrott KM. Long-term outcome analysis of the first 100 complete repairs of bladder exstrophy in Erlanger technique. *BJU* 2001;87:24.
- [4] Baka-Jakubiak M. Combined bladder neck, urethral and penile reconstruction in boys with exstrophy-epispadias complex. *BJU* 2000;86:513–8, <http://dx.doi.org/10.1046/j.1464-410X.2000.00866.x>.
- [5] Cuckow P. The bladder-exstrophy-epispadias-complex. In: Thomas D, Duffy P, editors. *Essentials of pediatric urology*. 2. London: Informa Healthcare; 2008. p. 199–212 [chapter 15].
- [6] Grady RW, Carr MC, Mitchell ME. Complete primary closure of bladder exstrophy: epispadias and bladder exstrophy repair. *Urol Clin North Am* 1999;26:95–109.
- [7] Mitchell ME, Bagli DJ. Complete penile disassembly for epispadias repair: the Mitchell technique. *J Urol* 1996;155:300–3, [http://dx.doi.org/10.1016/S0022-5347\(01\)66649-7](http://dx.doi.org/10.1016/S0022-5347(01)66649-7).
- [8] Gearhart JP, Mathews R. Exstrophy-epispadias complex. In: Wein AJ, Kavoussi LR, Novick AC, Partin AW, Peters CA, editors. *Campbell-Walsh urology*. 9th ed. Philadelphia: Saunders Elsevier; 2007. p. 3497.
- [9] Engel RM. Bladder exstrophy: vesicoplasty or urinary diversion? *Urology* 1973;2:20–4.
- [10] Ransley PG, Duffy PG, Wollin M. Bladder exstrophy closure and epispadias repair. In: Spitz L, Nixon HH, editors. *Paediatric surgery*. 4. London: Butterworths; 1988. p. 620–32.
- [11] Mensah JE, Asante EK, Appeadu Mensah W, Glover-Addy H. Continient cutaneous diversion for bladder exstrophy in adults. *Afr J Urol* 2013;19(June (2)):94–8.
- [12] Mansour AM, Sarhan OM, Helmy TE, Awad B, Dawaba MS, Ghali AM. Management of bladder exstrophy epispadias complex in adults: is abdominal closure possible without osteotomy? *World J Urol* 2010;28(April (2)):199–204.
- [13] Pathak HR, Mahajan R, Imdad Ali N, Kaul S, Adankar MG. Bladder preservation in adult classic exstrophy: early results of four patients. *Urology* 2001;57:906–10.
- [14] Gearhart JP. Editorial comment. *Urology* 2001;57:910.