



## African Journal of Urology

Official journal of the Pan African Urological Surgeon's Association  
web page of the journal

[www.ees.elsevier.com/afju](http://www.ees.elsevier.com/afju)  
[www.sciencedirect.com](http://www.sciencedirect.com)



### Uro-oncology

#### Case report

# Unilateral nodular adrenal hyperplasia: Case series



A.F. Kotb\*, M.A. Atta

Urology Department, Faculty of Medicine, Alexandria University, Alexandria, Egypt

Received 16 August 2015; received in revised form 20 December 2015; accepted 12 January 2016

Available online 26 July 2016

#### KEYWORDS

Adrenal hyperplasia;  
Cushing syndrome;  
Hyperaldosteronism;  
Adrenalectomy;  
Hypertension

#### Abstract

**Introduction:** Nodular adrenal hyperplasia is one of rare causes of adrenocortical hyperplasia. The disease usually presents bilaterally. Few publications discussed the possibility of unilateral disease, in association with hyperaldosteronism or Cushing syndrome.

**Case series:** We are reporting 3 cases of radiologically evident unilateral adrenal hyperplasia. Two cases were diagnosed as having hyperaldosteronism and one case as having Cushing syndrome. Laparoscopic adrenalectomy was done for all the cases. Pathological examination confirmed the diagnosis of nodular hyperplasia. Excellent outcomes were achieved post-surgery.

**Conclusion:** Unilateral nodular hyperplasia is an existent pathology affecting our patients with hyperaldosteronism and Cushing syndrome. The disease may not be rare but actually overlooked as the nodular hyperplasia may be <1 cm.

© 2016 Pan African Urological Surgeons' Association. Production and hosting by Elsevier B.V. This is an open access article under the CC BY-NC-ND license (<http://creativecommons.org/licenses/by-nc-nd/4.0/>).

#### Introduction

Among the causes of adrenocortical hyperplasia is the bilateral nodular hyperplasia. This can be either adrenocorticotrophic hormone (ACTH)-dependent bilateral macronodular

hyperplasia secondary to long-term adrenal stimulation in patients with Cushing's disease or ectopic ACTH syndrome or it can be ACTH-independent bilateral macronodular adrenal hyperplasia (AIMAH). Omura et al. [1] in 2002 reported a unique finding of unilateral micronodular adrenal hyperplasia presenting in 4 cases and highlighted this important pathology that can be easily not detected with standard imaging tests. No further reports have been published concerning that important pathology that can be easily not diagnosed. The aim of our work was to report 3 cases of unilateral nodular hyperplasia, presented in a single year. Two patients presented with hyperaldosteronemia and one boy with Cushing syndrome (CS).

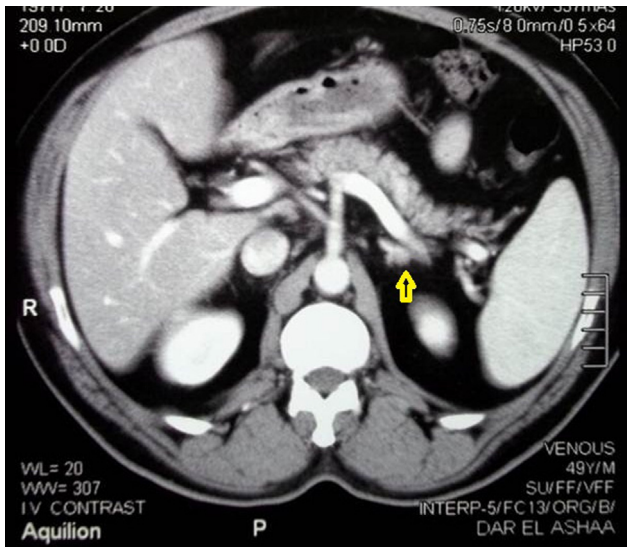
\* Corresponding author.

E-mail address: [drahmedfali@gmail.com](mailto:drahmedfali@gmail.com) (A.F. Kotb).

Peer review under responsibility of Pan African Urological Surgeons' Association.

<http://dx.doi.org/10.1016/j.afju.2016.01.012>

1110-5704/© 2016 Pan African Urological Surgeons' Association. Production and hosting by Elsevier B.V. This is an open access article under the CC BY-NC-ND license (<http://creativecommons.org/licenses/by-nc-nd/4.0/>).

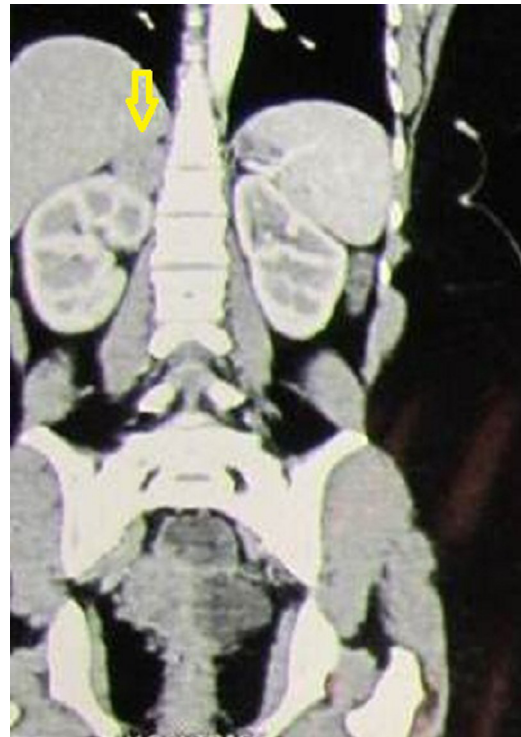

**Figure 1** CT image showing small nodule in left adrenal gland.

Their diagnosis could be easily missed, but they were completely cured with unilateral adrenalectomy.

#### Case 1

A 49-year-old male patient presented with severe persistent headache over 4 years, started with the diagnosis of hypertension not responsive to antihypertensive measures, with frequent admission to intensive care with malignant hypertension. His laboratory tests showed hypokalemia (serum potassium was 2.1 mEq/L). Serum aldosterone was high (31 ng/dL). Reference range 3–19 ng/dL and aldosterone renin ratio (ARR) was 25. CT abdomen and pelvis revealed a small nodule (7 mm) in left adrenal gland that had an initial attenuation of 2 Hounsfield unit and was diagnosed by radiologists as a small lipid rich adenoma (Fig. 1). We counselled the patients and did laparoscopic left adrenalectomy and the pathological assessment revealed macronodular adrenal hyperplasia. The patient was cured and his blood pressure was stable requiring no antihypertensive measures.



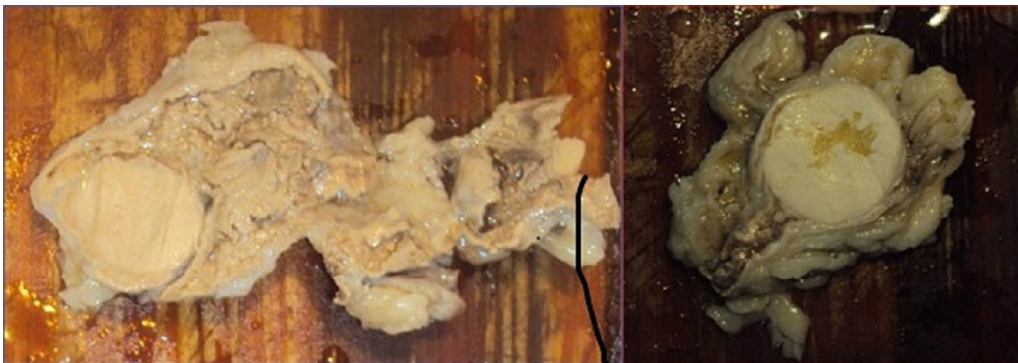**Figure 2** CT image showing adenoma in right adrenal gland.

#### Case 2

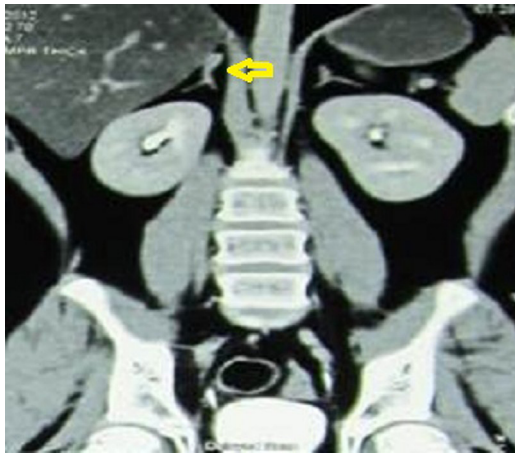
A 37-year-old female patient presented with severe persistent hypertension. Her serum aldosterone was 15 ng/dL and ARR was 60. CT revealed 15 mm adenoma in her right suprarenal gland (Fig. 2). Right laparoscopic adrenalectomy was done. Pathological assessment confirmed the diagnosis of unilateral macronodular hyperplasia (Fig. 3).

#### Case 3

A 12-year-old boy referred to our clinic from endocrinology department with the diagnosis of CS. His CT showed a small 8 mm right adrenal adenoma (Fig. 4). Laparoscopic right adrenalectomy was done. Pathological assessment confirmed the diagnosis of unilateral macronodular hyperplasia.



**Figure 3** Macroscopic pathological image showing macronodular adrenal hyperplasia.



**Figure 4** CT image showing small nodule in right adrenal gland.

### Discussion

Zografos et al. [2] published a case report of radiologically unilateral adrenal hyperplasia that was managed by bilateral adrenalectomy and turned to be bilateral nodular adrenal hyperplasia. That was an important case report as it included the nodular hyperplasia in the differential diagnosis of CS and that entity was commonly not diagnosed due to its rarity. We had a single boy that was similarly diagnosed radiologically as having unilateral small adrenal nodule. However; we only did unilateral adrenalectomy for him, confirming the diagnosis of micronodular hyperplasia, and our patient showed marked improvement with no need to explore the apparently normal other side. Xu et al. [3] studied 27 patients that were diagnosed as having either ACTH independent Cushing syndrome or primary pigmented nodular adrenocortical hyperplasia. In their study, all patients had radiological evidence of bilateral disease. Their patients were managed by unilateral adrenalectomy and this management confirmed long term remission of CS with no need to remove the other adrenal gland.

Recently, Iacobone et al. [4] studied 35 patients presented with primary hyperaldosteronism. Bilateral adrenal enlargement was found radiologically, but laterality was achieved by adrenal vein sampling. Unilateral adrenalectomy achieved excellent long term outcomes. We had 2 cases that showed a radiological evidence of small unilateral adenoma and was diagnosed as having primary hyperaldosteronism. Laparoscopic adrenalectomy was done allowing excellent outcomes and pathological analysis confirmed the diagnosis of nodular hyperplasia. In our cases, the other suprarenal gland was normal radiologically.

### Conclusion

Unilateral nodular hyperplasia is an existent pathology affecting our patients with hyperaldosteronism and Cushing syndrome. The disease may not be rare but actually overlooked as the nodular hyperplasia may be < 1 cm.

### The ethical committee approval

Ethical committee approval from Alexandria University was obtained.

Consent from the patients were obtained with full agreements to keep their personal data anonymous.

### Authors' contributions

Ahmed Kotb: Data collection and analysis and writing the manuscript ([drahmedfali@gmail.com](mailto:drahmedfali@gmail.com))

Mohamed Adel Atta: Data collection and analysis ([m\\_adelatta@hotmail.com](mailto:m_adelatta@hotmail.com)).

### Conflict of interest

No conflict of interest to declare.

### Source of funding

This research received no specific grant from any funding agency in the public, commercial or not-for-profit sectors.

### References

- [1] Omura M, Sasano H, Fujiwara T, Yamaguchi K, Nishikawa T. Unique cases of unilateral hyperaldosteronemia due to multiple adrenocortical micronodules, which can only be detected by selective adrenal venous sampling. *Metabolism* 2002;51(3):350–5.
- [2] Zografos GN, Pappa T, Avlonitis S, Markou A, Chrysikos DT, Kaltsas G, et al. Primary pigmented nodular adrenocortical disease presenting with a unilateral adrenocortical nodule treated with bilateral laparoscopic adrenalectomy: a case report. *J Med Case Rep* 2010;4:230.
- [3] Xu Y, Rui W, Qi Y, Zhang C, Zhao J, Wang X, et al. The role of unilateral adrenalectomy in corticotropin-independent bilateral adrenocortical hyperplasias. *World J Surg* 2013;37(7):1626–32.
- [4] Iacobone M, Citton M, Viel G, Boetto R, Bonadio I, Tropea S, et al. Unilateral adrenal hyperplasia: a novel cause of surgically correctable primary hyperaldosteronism. *Surgery* 2012;152(6):1248–55.