



African Journal of Urology

Official journal of the Pan African Urological Surgeons' Association
web page of the journal

www.ees.elsevier.com/afju
www.sciencedirect.com



Andrology/Male Genital Disorders

Case report

'Opening a can of worms': Bilateral varicoceles as an indicator of underlying portal-hypertension



A. Adam^{a,1,*}, W.C. Mamitele^a, A. Moselane^b, F. Ismail^c

^a Department of Urology, University of Pretoria, Pretoria, South Africa

^b Department of Urology, 1 Military Hospital, Pretoria, South Africa

^c Department of Radiology, University of Pretoria, Pretoria, South Africa

Received 22 December 2015; accepted 24 January 2016

Available online 1 August 2016

KEYWORDS

Varicocele;
Portal hypertension;
Portosystemic shunt

Abstract

The scrotal varicocele is a common finding encountered during clinical examination. A porto-systemic shunt presenting with an associated varicocele is exceptionally rarely reported. Herein, we report such a case in an HIV positive man who presented with bilateral varicoceles. This is only the fifth case of such an association in the world literature. A literature review and the possible underlying pathophysiological mechanisms of this rare association are expanded further.

© 2016 Pan African Urological Surgeons' Association. Production and hosting by Elsevier B.V. All rights reserved.

Introduction

A varicocele is defined as an abnormal tortuosity and dilatation of the testicular veins and pampiniform plexus. This may be present due to absent or incompetent valves, or increased hydrostatic pressure [1]. The left-sided varicocele is much more common (up to 90%) than the right-sided variant [1]. Varicoceles found in relation to porto-systemic shunting is theoretically possible, but are exceptionally rarely reported. Herein, we report such a case in a newly diagnosed HIV positive man with an underlying protein-S deficiency.

* Corresponding author.

E-mail address: aadam81@gmail.com (A. Adam).

¹ Current affiliation: Consultant Urologist, Adult and Paediatric Urology, Head Consultant, Department of Urology, Helen Joseph Hospital, & Head Consultant, Department of Paediatric Urology, Rahima Moosa Mother & Child (Coronation) Hospital, and Division of Urology, Department of Surgery, University of the Witwatersrand, Johannesburg, South Africa. Tel.: +27114890118; fax: +27114890739.

Peer review under responsibility of Pan African Urological Surgeons' Association.

<http://dx.doi.org/10.1016/j.afju.2016.01.006>

1110-5704/© 2016 Pan African Urological Surgeons' Association. Production and hosting by Elsevier B.V. All rights reserved.

Table 1 A tabulated listing of all previous reports (including our index case) of varicoceles associated with a porto-systemic shunt.

Reference	Age	Side/Bilateral	Presenting symptom	Porto-systemic shunt	Portal hypertension	Underlying diagnosis
[1]	45	Right-sided	Infertility	+	+	Liver cirrhosis
[2]	53	Left-sided	'Hydrocele'	+	+	Liver cirrhosis
[3]	63	Left-sided	'Scrotal mass'	+	+	Liver cirrhosis
[4]	65	Right-sided	'Hernia'	+	-	Idiopathic shunt
[*] Index case	32	Bilateral	Orchialgia	+	+	HIV + portal & splenic vein thrombosis, acquired protein S deficiency

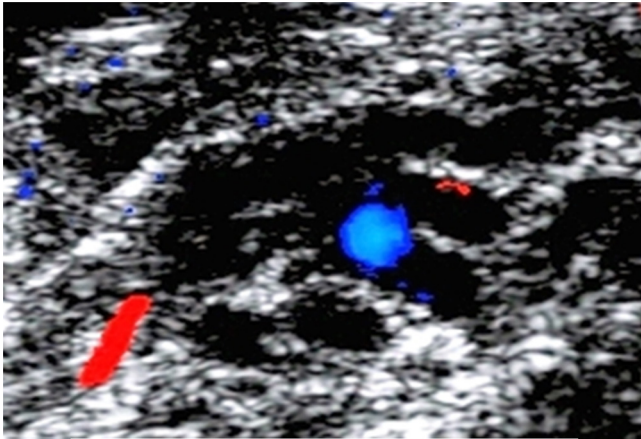


Figure 1 Scrotal doppler ultrasound study demonstrating the right-sided varicocele.

Case report

A 32-year-old man presented with right-sided orchialgia without any prior account of trauma. Examination revealed bilateral varicoceles (grade 3 left and Grade 2 right-sided), which was confirmed on scrotal ultrasound (Fig. 1). Abdominal sonar highlighted features consistent with portal hypertension.

Abdominal Computed Tomography scan, revealed splenic vein thrombosis, and resulting portal hypertension, with para-oesophageal, para-vertebral, retro-peritoneal and anterior

abdominal varices (Fig. 2A & B). Bilateral testicular varicoceles were also detected.

Haematological investigations revealed an acquired protein-S deficiency, which was discovered to be secondary to a newly diagnosed concurrent HIV infection. He did not have evidence of any AIDS defining disease at the time of presentation. This thrombophilic state resulted in splenic and portal vein thrombosis.

Multiple enlarged, tortuous collateral vessels were noted in the retro-peritoneum with the left testicular vein draining into this venous plexus inferior to the left kidney (Fig. 2).

Although the right testicular vein drained directly into the inferior vena cava, this patho-physiological mechanism involved in this right-sided varicocele may be explained by the increase in hydrostatic pressure caused by the porto-systemic shunt, or by extrinsic compression from the conglomerate of collateral veins (Fig. 2).

Our index patient defaulted from follow up, further investigations and refused further treatment.

Discussion

Patients with underlying portal hypertension and a porto-systemic shunt rarely present with a right-sided or bilateral varicocele. A Pubmed search (with cross referencing) using the search terms; 'varicocele AND portal hypertension' and 'varicocele AND porto-systemic shunt' only revealed the following four previously reported cases (Table 1) [1-4].

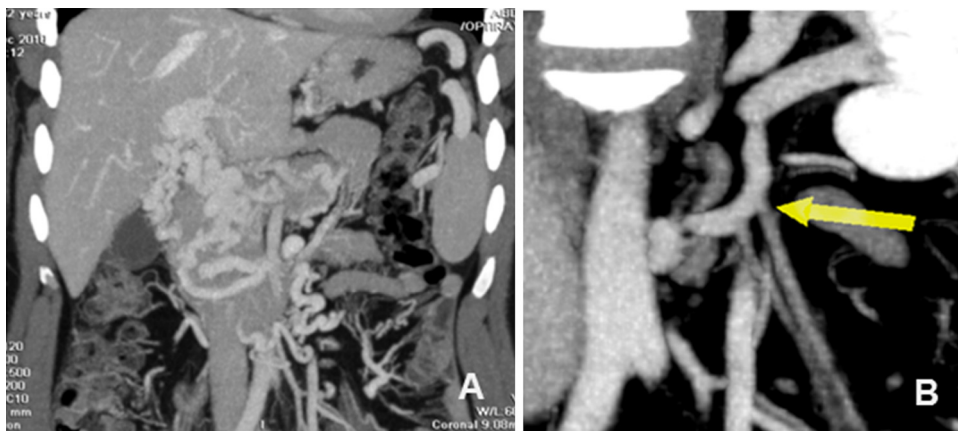

Figure 2 (A) Abdominal contrast enhanced computed tomography scan (coronal view), in the portal venous phase depicting the underlying portal-systemic shunt. Multiple collateral vessels are also present. (B) Coronal venous reconstruction demonstrating the left testicular vein (yellow arrow) draining via the retroperitoneal collateral system to the left renal vein.

Various presenting symptoms have been previously described, including a scrotal mass, hydrocele, hernia or infertility [1–4]. The underlying diagnosis in these patients may go undetected to the ‘unassuming Urologist’. On palpation of a varicocele, the scrotal examination may feel like a ‘bag of worms’ [5], we have now shown that the search for the underlying cause in a bilateral/right-sided varicocele, may be metaphorically similar to ‘opening the can of worms’ to reveal a sometimes sinister underlying diagnosis.

Conclusion

This case further illustrates the possibility of considering the underlying cause in (*atypical*) or *bilateral* varicoceles. The presence of a right-sided varicocele may also reveal an underlying renal cell carcinoma, retroperitoneal fibrosis or associated tumour [5]. With this report we have illustrated another rare association which may present with bilateral varicoceles; portal hypertension with a portosystemic shunt.

Ethical committee approval

Yes, Ethics Number: M160692, July 07, Chairman: Professor Peter Cleaton-Jones.

Conflict of interest

None declared.

Source of Funding

None.

Authors’ contributions

A. Adam: Inception, write-up, structure, literature review, submission.

W.C. Mamitele: Patient report and management.

T.A.D. Moselane: Overall supervision and review.

F. Ismail: Radiological review and reporting.

Acknowledgements

We wish to thank Dr I. Serfontein (Radiologist, Meulmed Hospital, Pretoria), Prof Z.I. Lockhat (Head, Department of Radiology, University of Pretoria and Steve Biko Academic Hospital, Pretoria, South Africa), Dr E.M. Moshokoa (Head, Department of Urology, University of Pretoria and Steve Biko Academic Hospital, Pretoria, South Africa) for their expert opinion and contribution to this manuscript.

References

- [1] Pinggera GM, Herwig R, Pallwein L, Frauscher F, Judmaier W, Mitterberger M, et al. Isolated right-sided varicocele as a salvage pathway for portal hypertension. *Int J Clin Prac* 2005;59:740–2.
- [2] Yardy G, Rafique A, Sellers I, Berman L, Bullock N. A varicocele mimicking a hydrocele in a man with portal hypertension: a case report. *J Med Case Rep* 2008;2:363.
- [3] Schulte-Baukloh H, Kammer J, Felfe R, Stürzebecher B, Knispel HH. Surgery is inadvisable: massive varicocele due to portal hypertension. *Int J Urol* 2005;12:852–4.
- [4] Zahir M, Al Muttairi HR, Upadhyay SP, Mallick PN. Unilateral Giant Varicocele mimicking Inguinal hernia resulting from portosystemic shunt without evidence of portal hypertension: an unusual case report. *Case Rep Surg* 2013;2013:709835, <http://dx.doi.org/10.1155/2013/709835>.
- [5] Mohammed A, Chinegwundoh F. Testicular varicocele: an overview. *Urol Int* 2009;82:373–9.