



African Journal of Urology

Official journal of the Pan African Urological Surgeon's Association
web page of the journal

www.ees.elsevier.com/afju
www.sciencedirect.com



Pediatric Urology

Case report

A case of isolated female epispadias and our approach to treatment



M.S. Arslan ^{a,b,*}, S. Arslan ^{a,b}, H. Zeytun ^{a,b}, E. Basuguy ^{a,b},
M. Ozkir ^c, B. Aydogdu ^{a,b}, M.H. Okur ^{a,b}, I. Uygun ^{a,b}

^a Department of Pediatric Surgery, University of Dicle, Diyarbakir, Turkey

^b Department of Pediatric Urology, University of Dicle, Diyarbakir, Turkey

^c University of Kentucky College of Medicine, 40506 Lexington, KY, USA

Received 19 June 2015; received in revised form 3 September 2015; accepted 13 September 2015

Available online 27 July 2016

KEYWORDS

Female epispadias;
Patulous urethra;
Bifid clitoris;
Urinary incontinence

Abstract

Cases of isolated female epispadias (IFE) without exstrophy of the bladder are quite rare. The clinical symptoms of IFE are abnormal external genitalia with primary urinary incontinence.

Our patient was a 7-year-old girl with total urinary incontinence. Physical examination revealed a patulous urethra, bifid labia minora, and a bifid clitoris. The vagina and hymen appeared to be normal. Uroflowmetry demonstrated an overflow-type pathological voiding pattern with low voiding pressure. A voiding cystourethrogram showed no indications of reflux.

To treat our IFE patient, we performed a single stage genital approach reconstruction of the urethra, clitoris, and labia minora. Follow up with the patient ensured that she was continent and that her external genitals took on an acceptable appearance.

© 2016 Pan African Urological Surgeons' Association. Production and hosting by Elsevier B.V. All rights reserved.

Introduction

Studies of isolated female epispadias (IFE) without exstrophy of the bladder are found only in very limited numbers in the literature and are generally published only in the form of case reports. The incidence of IFE is only 1 in every 448,000 births [1]. In general there may be delays in the diagnoses of these cases as their deformities are covered by the labia majora. The clinical presentation of IFE is defect in the anatomic appearance of the genital region

* Corresponding author. Present address: Department of Pediatric Surgery, Cincinnati Children's Hospital, University of Cincinnati, 3333 Burnet Avenue, MLC 11025, Cincinnati, OH 45229-3039, USA.
E-mail address: mserif.arslan@dicle.edu.tr (M.S. Arslan).

Peer review under responsibility of Pan African Urological Surgeons' Association.

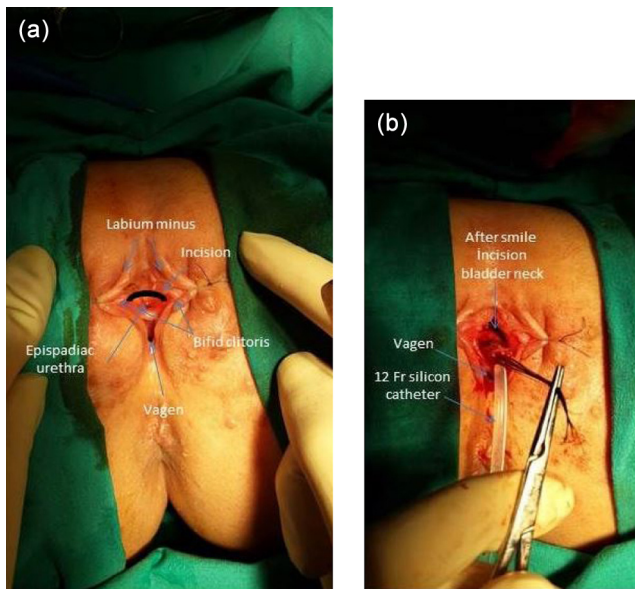


Figure 1 (a) After placing silk suspensory suture in the labia: bifid clitoris, patulous urethral meatus with deficient dorsal wall, depressed mons. (b) Suspension of the urethra; reconstruction of a new urethra with a smile incision.

accompanied by urinary incontinence. Anatomically, the most frequently observed parameters of this anomaly are an epispiadic urethra, a wide and open bladder neck, and bifid clitoris, along with a normal hymen and a normal vagina [2]. The recommended treatment for IFE is a single stage operation reconstructing the bladder neck, urethra, and bifid clitoris in order to achieve normal external genital appearance and urinary continence. We set out in this study to present the case of a patient who was admitted to our clinic because of urinary incontinence, whom we subsequently diagnosed with IFE and treated with a single stage operation.

Case

A 7-year-old girl was admitted to our outpatient clinic complaining of a failure to develop bladder control since birth and skin lesions in the genital area. Physical exam revealed eruptions in the skin of the perineum from continued diaper usage. The urethra was epispiadic in appearance, and a bifid clitoris and bifid labia minora were observed (Fig. 1a). The vaginal orifice and hymen were normal. Voiding cystourethrography showed the bladder capacity to be 220 ml (with a normal age-based value of 270 ml). There were no indications of vesicourethral reflux. Uroflowmetry demonstrated overflow-type voiding with low urethral pressure. Cystourethroscopy indicated that the urethra was wide and very short, with a measured length of 0.5 cm. The bladder neck was fully open. The urethral orifice and bladder mucosa appeared normal.

For the surgical procedure, the patient was positioned in the lithotomy position, and silk suspensory sutures were placed in the front wall of the urethra at close intervals. A smile incision (from 9 to 3 on the clock) was used to free the front wall of the urethra from the clitoris and the surrounding tissues (Fig. 1b). The plane between the urethra and the vagina was not disturbed. Full mobilization of the urethra and the bladder neck was achieved in front. Because the neck of the bladder was so wide, a piece of full-thickness tissue

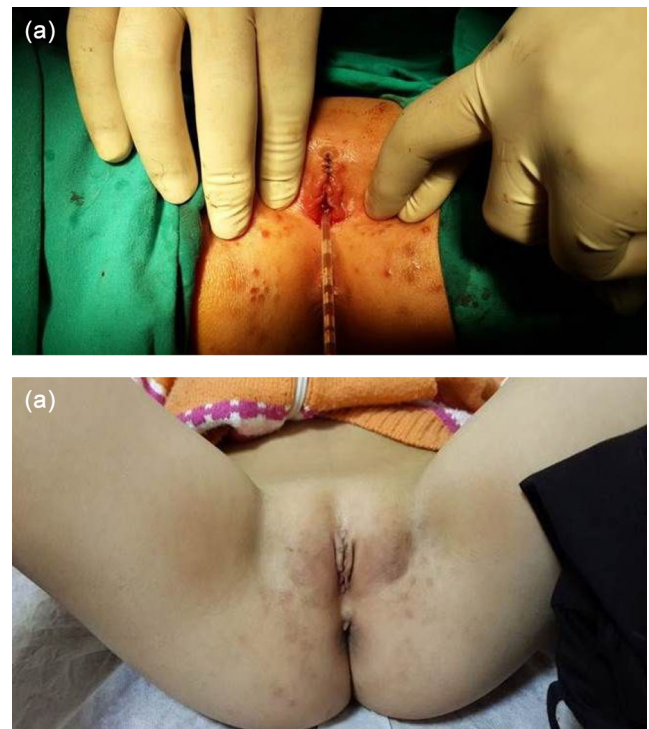


Figure 2 (a) Final appearance after complete reconstruction, with the 12 Fr catheter in place. (b) Appearance of the external genitalia six weeks after surgery.

in the shape of rectangle was excised, consisting of approximately 3 cm of the bladder neck and bladder from beginning from the urethra up. The neck of the bladder and the urethra were tubularized with 5/0 PDS sutures over a 12 Fr silicon Foley catheter, forming a urethra of approximately 3–4 cm in length. The bifid clitoral structures were combined at the midline. The surgical procedure was completed with the reconstruction of the labia minora (Fig. 2a). The Foley catheter in the urethra was removed on the 10th postoperative day. Urethral calibration was observed to be normal.

The patient began urotherapy in postoperative medical treatment, which taught her biofeedback and kegel exercises. At a checkup performed after three months, uroflowmetry with simultaneous electromyography indicated a normal voiding pattern and a bladder capacity of 250 ml. In the course of following up with the patient, it was noted that she had gained urinary continence and that the perineal region eruptions had cleared up (Fig. 2b).

Discussion

IFE is an uncommon congenital anomaly of the lower urogenital tract. The literature reports an incidence of 1 in 484,000 female patients, with cases ranging from neonates to 39-year-old adults [3]. These published cases also exhibited various degrees of urinary incontinence [4]. Similarly in our own case, we observed urinary incontinence accompanied by a low bladder capacity.

Davis classified female epispiadias into three groups according to appearance: mild, moderate, and severe. Mild cases may exhibit only a patulous urethra. In moderate cases, the dorsal surface of the urethra is split. In severe cases the entire length of the urethra

and the neck of the bladder are quite wide and short, rendering the sphincteric mechanism deficient [5]. Mild cases are quite rare in the literature [6]. It is extremely challenging to recognize these cases as they are continent. It would be very difficult to diagnose these cases without separating the labia majora and performing a careful physical exam. However, usually the external appearance is distinctive. In severe cases, because the sphincteric mechanism is deficient and the neck of the bladder is poorly developed, bladder capacity is generally noted to be low. However, in these patients the vagina and the hymen are normally developed [4]. The most frequently encountered causes of incontinence in IFE are incomplete bladder neck, low urethral pressure, and low bladder capacity [7].

Surgical repair is necessary to create an acceptable cosmetic appearance in the genital region, to restore function, and to protect the upper urinary system. Urethral reconstruction together with clitoris and labia minora reconstruction result in an acceptable appearance and restoration of function. In the literature, the traditional definitive IFE operation is presented as a two stage operation. Traditionally, the first stage consisted of genitourethral reconstruction, followed after 1–2 years by the repair of the bladder neck to restore continence [8]. The first single stage reconstruction using the perineal and transvesical approach was described in three cases by Hendren. In their 6-case study, they performed single stage surgery on 3 patients, and on the other three they used the traditional combination procedure [9]. The current IFE treatment method sets out to free the patulous urethra with an incision from the 9 to 3 positions on the clock, immediately followed by the creation of a functional new urethra and genitoplasty in the same step to create an acceptable cosmetic appearance [2–4,8,10,11].

Our patient was a severe case according to the Davis criteria. In her case, urethral resistance was low, the neck of the bladder was incomplete, and the bladder capacity was low. In one surgical session with this patient, we were able to form a 3–4 cm urethra with a bladder neck and urethral reconstruction. Because we were able to provide normal urethral resistance, we observed in our follow-up that the patient's symptoms of incontinence had cleared up, and that the patient was continent.

In conclusion, in female children exhibiting incontinence, to avoid an insufficient diagnosis one must never overlook the necessity of a careful physical examination of the genitals. In diagnosed cases of IFE, we recommend single step urethroplasty, bladder neck reconstruction, and perineoplasty in order to achieve an acceptable cosmetic appearance and a functional urethra.

Authors' contributions

Mehmet Serif Arslan (mserif.arslan@dicle.edu.tr): Interpretation of data, manuscript writing, critical revision.

Serkan Arslan (drserkanarslan@hotmail.com): Interpretation of data.

Hikmet Zeytun (hzeytun333@hotmail.com): Critical revision.

Erol Basuguy (erbas.80@hotmail.com): Critical revision.

Mariah Ozkir (mariah.ozkir@gmail.com): English language review.

Bahattin Aydogdu (bahattinaydogdu@hotmail.com): Critical revision.

Mehmet H. Okur (m.hanifi-okur@hotmail.com): Conception and design of the study.

Ibrahim Uygun (iuygun@hotmail.com): Conception and design of the study.

Ethical committee approval

Approved by the Ethics committee of Human of Dicle University, school of medicine. Ethical committee number is 14/33.

Conflict of interest

The authors declare that they have no conflict of interest to disclose.

Funding

None.

References

- [1] Dees JE. Congenital epispadias with incontinence. *J Urol* 1949;62:513–22.
- [2] Lazarus J, van den Heever A, Kortekaas B, Alexander A. Female epispadias managed by bladder neck plication via a perineal approach. *J Pediatr Urol* 2012;8:244–8.
- [3] Yeni E, Unal D, Verit A, Karats OF. An adult female epispadias without exstrophy was presented with urinary incontinence: a case report. *Int Urogynecol J Pelvic Floor Dysfunct* 2004;15:212–3.
- [4] Shetty MV, Bhaskaran A, Sen TK. Female epispadias. *Afr J Paediatr Surg* 2011;8:215–7.
- [5] Davis DM. Epispadias in females and its surgical management. *Surg Gynecol Obstet* 1928;47.
- [6] Mollard P, Basset T, Mure PY. Female epispadias. *J Urol* 1997;158:1543–6.
- [7] Bhat AL, Bhat M, Sharma R, et al. Single-stage perineal urethroplasty for continence in female epispadias: a preliminary report. *Urology* 2008;72:300–3, discussion 303–304.
- [8] Atilgan D, Uluocak N, Erdemir F, Parlaktas BS. Female epispadias: a case report and review of the literature. *Kaohsiung J Med Sci* 2009;25:613–6.
- [9] Hendren WH. Congenital female epispadias with incontinence. *J Urol* 1981;125:558–64.
- [10] Cheikhelard A, Aigrain Y, Lottmann H, Lortat-Jacob S. Female epispadias man-agement: perineal urethrocervicoplasty versus classical Young-Dees procedure. *J Urol* 2009;182:1807–11.
- [11] Tantibhedhyangkul J, Copland SD, Haqq AM, Price TM. A case of female epispadias. *Fertil Steril* 2008;90(2017):e2011–3.