



## African Journal of Urology

Official journal of the Pan African Urological Surgeon's Association  
web page of the journal

[www.ees.elsevier.com/afju](http://www.ees.elsevier.com/afju)  
[www.sciencedirect.com](http://www.sciencedirect.com)



### Review

# Non-transecting bulbar urethroplasty using buccal mucosa



S. Bugeja\*, S. Ivaz, A.V. Frost, D.E. Andrich, A.R. Mundy

University College London Hospital, Reconstructive Urology Unit, UK

Received 6 September 2015; accepted 30 September 2015

Available online 2 December 2015

#### KEYWORDS

Urethral stricture;  
Bulbar urethroplasty;  
Non-transecting;  
Buccal mucosal graft

#### Abstract

Augmentation urethroplasty using oral mucosal graft has become the standard surgical treatment of long bulbar strictures. In very tight strictures the urethral plate is narrowed to the extent that an almost circumferential substitution with oral graft is necessary, with suboptimal results. If the obliterative segment within a longer stricture is short it is possible, through a dorsal stricturotomy, to excise it in a non-transecting manner, leaving the ventral spongiosum intact and anastomose the mucosal edges to reconstitute the urethral plate to an adequate calibre. The stricturotomy is subsequently augmented with an oral mucosal graft. We describe this technique as the augmented non-transecting anastomotic bulbar urethroplasty. It also allows for use of a narrower and shorter graft. In our hands this procedure is associated with a 100% radiological success rate and a 95% patient satisfaction rate at a mean follow-up of 14.8 months (5.7–52.6 months).

© 2015 Pan African Urological Surgeons' Association. Production and hosting by Elsevier B.V. All rights reserved.

#### Introduction

The surgical treatment of bulbar urethral strictures, and indeed any urethral stricture, is determined by their aetiology, length, location and by previous surgical intervention [1]. Traditionally, short idiopathic bulbar strictures (typically 1–2 cm long) have been

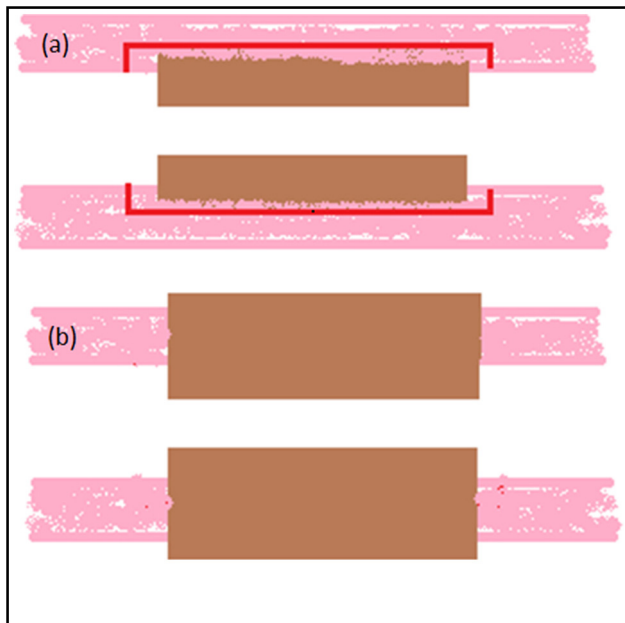
successfully managed by excision of the strictured urethral segment (the spongiofibrosis and the surrounding corpus spongiosum) and tension-free end-to-end anastomosis of the healthy spatulated edges (so called excision and primary anastomosis – EPA) [2,3]. This is associated with excellent long term functional results [4,5] but concerns have been raised about the potential consequences of transecting the spongiosum and disrupting the integrity of the spongiosal blood flow. We have therefore pioneered the non-transecting technique for short idiopathic bulbar strictures [6] which does not disrupt retrograde urethral blood flow and which is possible because of the pathophysiology of these strictures (as opposed to traumatic ones).

Longer bulbar strictures are considered to be unsuitable for excision and anastomosis due to the risk of tension on the anastomosis leading

\* Corresponding author at: Reconstructive Urology, University College London Hospital, Ground Floor Central, 250 Euston Road, NW1 2PG London, UK.

E-mail address: [simbugi@gmail.com](mailto:simbugi@gmail.com) (S. Bugeja).

Peer review under responsibility of Pan African Urological Surgeons' Association.



**Figure 1** Diagrammatic representation showing (a) superficial spongiofibrosis typical of idiopathic bulbar strictures as opposed to (b) the generally transmural fibrosis associated with traumatic strictures. The red line represents the plane through which spongiofibrosis is excised in a non-transsecting manner.

to increased stricture recurrence. Shortening of the penis and curvature during erection are added concerns [7]. These longer strictures are therefore routinely managed by an augmentation procedure, most commonly using an oral mucosal graft, without excision of the stricture [8]. Longer traumatic bulbar strictures which require excision, are usually treated by an augmented anastomotic approach in which, following stricture excision, the ventral aspect of the circumference of the urethra is anastomosed in an end-to-end fashion and the dorsal hemi-circumference is augmented with an oral mucosal graft [4].

Based on these surgical principles, we have been able to combine the use of the non-transsecting anastomotic technique and oral mucosal graft augmentation, for longer bulbar strictures in selected instances. We refer to this as the augmented non-transsecting anastomotic bulbar urethroplasty (ANTABU). This paper describes the technique of ANTABU and explains the underlying stricture pathophysiology which makes this approach possible. We describe the characteristics of those strictures which are suitable for this technique and the advantages and limitations of the procedure and our experience with it.

### Principles underlying non-transsection

The pathology of bulbar strictures differs between idiopathic and post-traumatic (fall-astride) causes even if the strictures are identical in length and location. In the former, the degree of spongiofibrosis is often surprisingly small, limited to around 10% of the thickness of the urethral wall, with well-preserved healthy underlying corpus spongiosum present [9] (Fig. 1a). This is in contrast to strictures following perineal trauma in which spongiofibrosis is usually transmural with no remaining vascularised spongiosal tissue [10] (Fig. 1b).

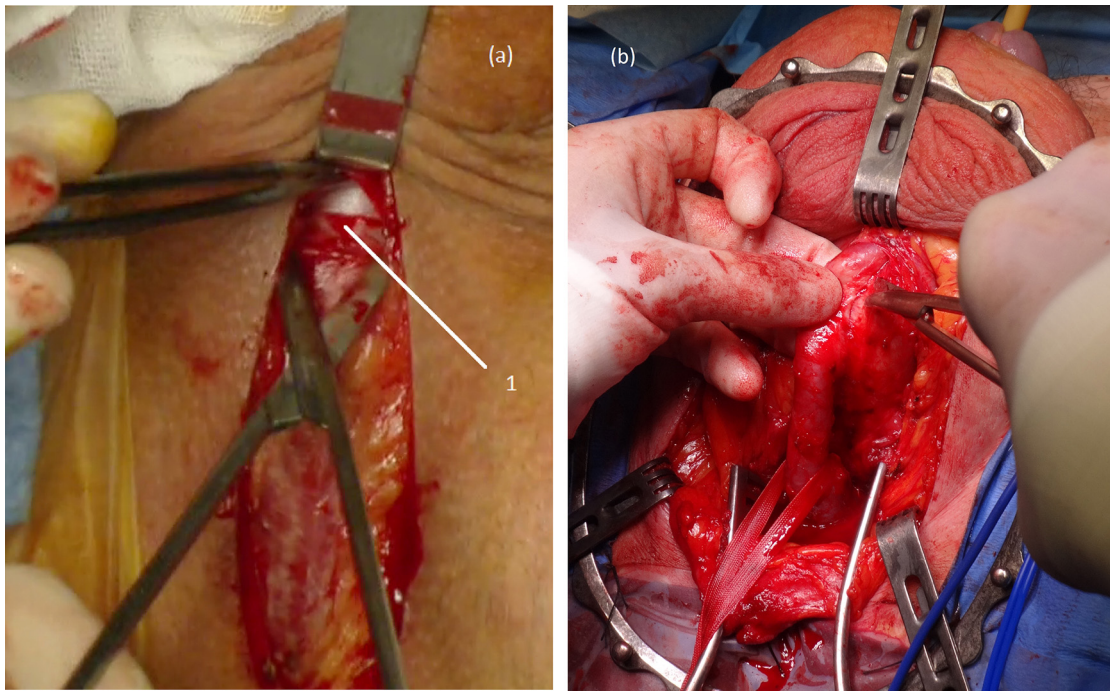
There is therefore no doubt that in traumatic bulbar strictures, transection with complete excision of the strictured segment is mandatory since failure to do so may lead to stricture recurrence in the long term. However, in cases of EPA for non-traumatic bulbar urethral strictures a significant proportion of the excised urethra is indeed healthy vascularised tissue but the nature of the procedures requires transection of the corpus spongiosum and, inevitably, of the urethral arteries within it. Although it is not certain whether this disruption of the retrograde urethral blood flow leads to adverse effects in the long-term, preservation of blood supply is always desirable particularly when the distal vascular supply to the urethra is compromised such as the elderly, those with peripheral vascular disease or micro-vascular disease, hypospadias, previous urethroplasty and patients who may subsequently be candidates for artificial urinary sphincter implantation and might be at increased risk of ischaemic erosion [11].

### Surgical technique – augmented non-transsecting anastomotic bulbar urethroplasty

All patients are assessed clinically and by means of flow rate study, antegrade/retrograde urethrogram and a preoperative symptom and quality of life questionnaire [12,13]. They are admitted to hospital on the day of surgery. Informed consent is obtained in the clinic beforehand and confirmed on review immediately before the surgery. The procedure is performed under antibiotic prophylaxis (gentamycin and co-amoxiclav usually) administered at induction of anaesthesia. Nasal intubation is standard to allow access to the oral cavity if harvesting of an oral mucosal graft is required. The patient is positioned in ‘social’ lithotomy which provides good surgical exposure of the perineum and has a very low incidence of complications [14]. The legs are supported in Allen® Yellofin® stirrups. Anti-thromboembolic stockings and pneumatic intermittent calf compression devices are used routinely. After shaving the perineum the skin is ‘prepped’ using a 2% chlorhexidine gluconate and 70% isopropyl alcohol formulation (ChlorPrep®) and the area draped.

A floppy-tipped hydrophilic guidewire is advanced across the stricture at the start of the procedure in order to facilitate identification of the lumen in very tight strictures once the stricturotomy is made. A midline perineal incision is performed and deepened through the bulbospongiosus muscle to expose the bulbar urethra. Incision of Gallaudet’s fascia allows access to the plane between the urethra and the muscle (Fig. 2a). The bulbar urethra is mobilised proximally and distally off the corpora cavernosa dorsally by incision of Buck’s fascia (Fig. 2b). A 20F Foley catheter is passed up the urethra to identify the distal end of the stricture. A dorsal stricturotomy is then performed by cutting onto the tip of this catheter held in position at this level (Fig. 3a). The stricturotomy is then extended proximally, with the help of a gorget (Fig. 3b), and distally into normal calibre urethra at either end.

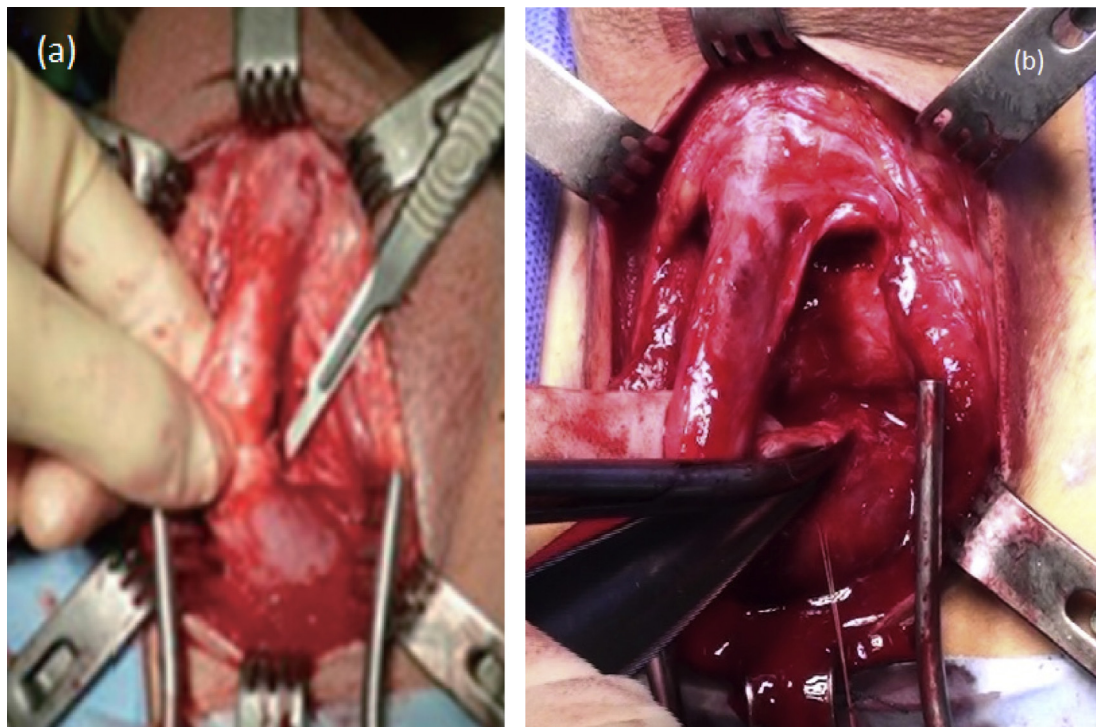
The type of urethroplasty performed will then depend on the length and location of the stricture. If the stricture is generally at the junction of the proximal and middle thirds of the bulbar urethra, short and membrane-like (1–2 mm long), the dorsal stricturotomy can be simply closed transversely after having adequately mobilised the bulbar urethra distally to allow a tension-free closure (Fig. 4). This is a Heineke–Mikulicz-type strictureplasty without excising the stricture [15].



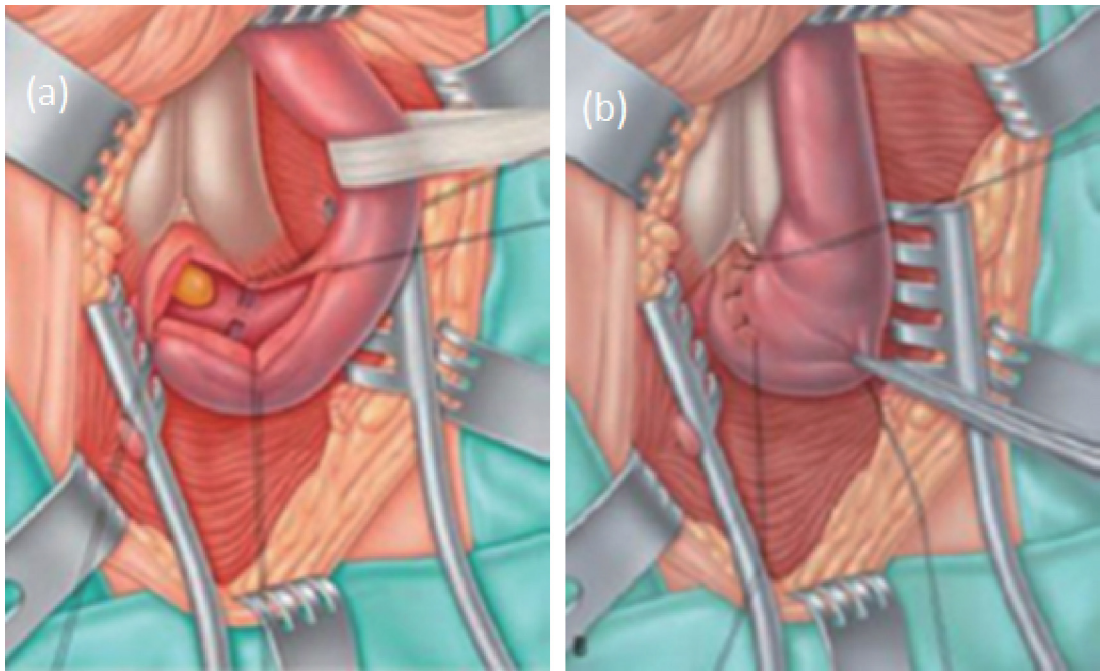
**Figure 2** (a) Gallaudet's fascia (1) incised providing access to the plane between the urethra and the bulbospongiosus muscle. (b) The urethra mobilised dorsally off the corpora cavernosa by incising Buck's fascia.

Proximal non-traumatic strictures which are longer (Fig. 5a), but typically less than 2cm are preferentially managed by a non-transecting anastomotic procedure (NTABU) [16] whereby the superficial spongiofibrosis along the entire length of the stricture

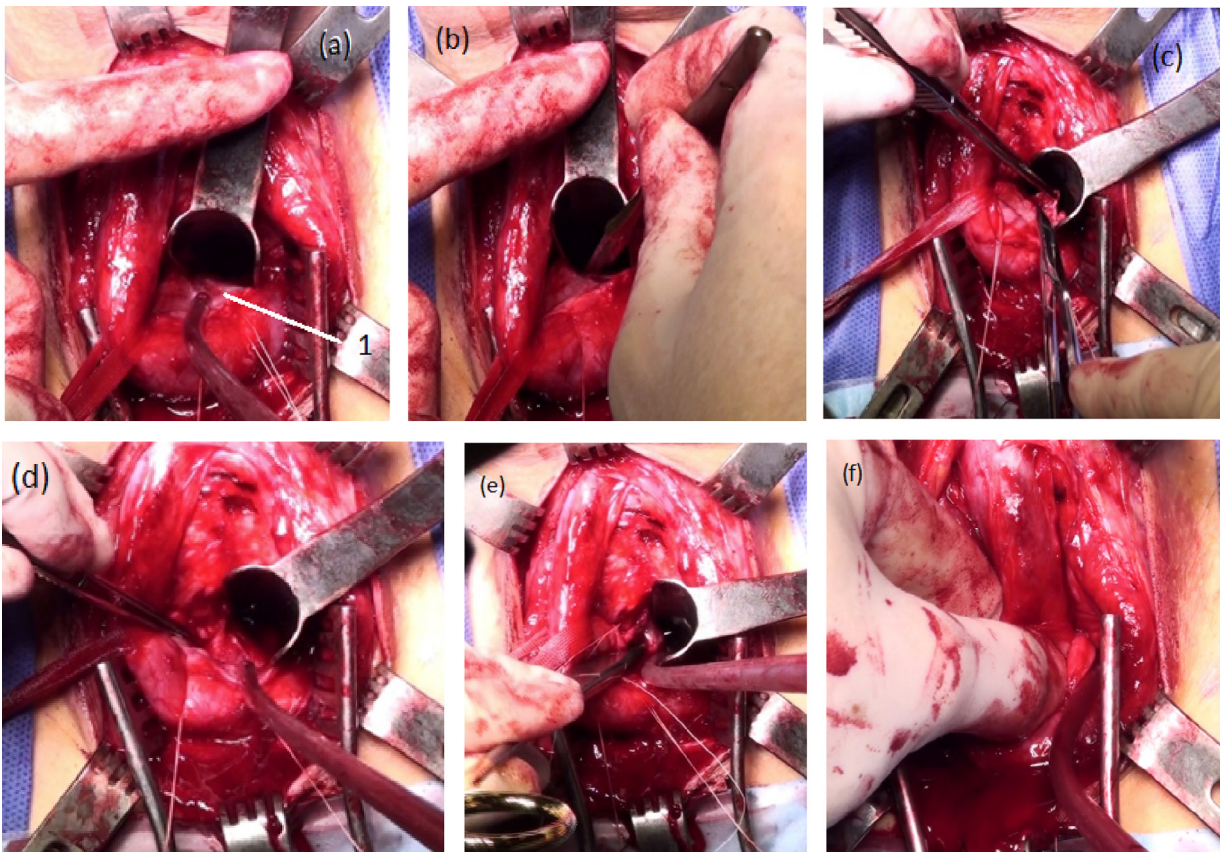
is carefully excised (Fig. 5b) leaving intact the underlying well vascularised ventral spongiosum and the urethral arteries within it (Fig. 5c). The healthy mucosal edges are then carefully anastomosed in an end-to-end fashion using interrupted 5/0 Vicryl® sutures



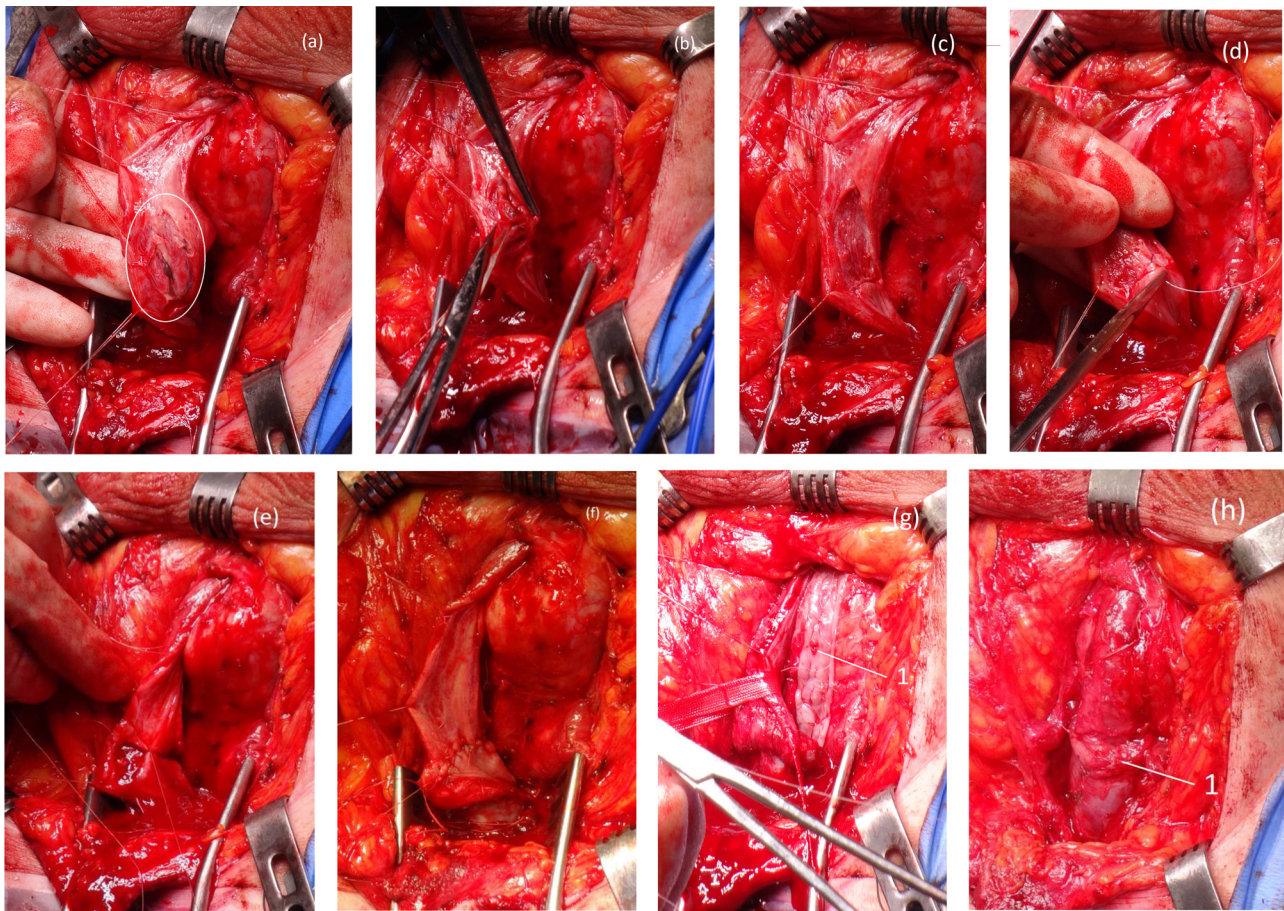
**Figure 3** (a) Dorsal stricturotomy made by cutting onto the end of a Foley catheter at the level of the stricture. (b) Stricturotomy extended proximally into normal calibre urethra.



**Figure 4** Heinecke–Mickulicz-type stricturoplasty (a) dorsal stricturotomy revealing a membrane-like proximal bulbar stricture. (b) Longitudinal stricturotomy closed transversely without excising the stricture.



**Figure 5** (a) Dorsal stricturotomy revealing a proximal bulbar stricture (1). (b) Superficial spongiofibrosis incised and (c) excised in a non-transsecting fashion (d) leaving healthy underlying spongiosal tissue. (e) Mucosal ends anastomosed and (f) stricturotomy closed transversely without tension.



**Figure 6** (a) Tight segment within a longer bulbar stricture. (b) Narrowest portion of spongiofibrosis excised (c) leaving underlying vascularised spongiosum. (d/e/f) Urethral plate reconstituted by end-to-end mucosal anastomosis. (g) Long stricturotomy augmented using a sublingual graft (1) quilted dorsally. (h) Appearance of urethra after suturing edges of stricturotomy to graft edges. Note the characteristic ‘bulge’ of the spongiosum after non-transecting resection of spongiofibrosis and mucosal anastomosis (1).

(Fig. 5d). Full mobilisation of the bulbar urethra distally and occasional development of the intracanal plane allows for a tension-free closure of the dorsal stricturotomy transversely (Fig. 5e).

Longer non-traumatic bulbar strictures are traditionally managed by augmentation of the entire length of the stricturotomy by an oral mucosal graft [17]. However some of these strictures have total or near complete obliterative segments so that the graft is essentially a circumferential substitution in these areas where the residual urethral plate is extremely narrowed or non-existent. Consequently a wider graft needs to be harvested (see comment). In order to avoid this we have combined use of the non-transecting anastomotic technique described above with graft augmentation; the augmented non-transecting technique. If the obliterative segment within a longer stricture (Fig. 6a) is short enough (usually one to two centimetres) to allow a tension-free anastomosis, this is first incised then excised in a non-transecting manner (Fig. 6b and c) and the urethral plate reconstituted by end-to-end mucosal anastomosis (Fig. 6d–f). In such cases the stricturotomy is too long to close transversely (even after full mobilisation) and therefore this is augmented using oral graft as one would in a standard Barbagli-type approach (Fig. 6g). In cases when the stricture is long but not too narrow, or the tighter segment is too long to allow non-transecting excision, the stricturotomy is simply augmented dorsally along its entire length.

A graft is harvested either from the cheek or sublingually for longer strictures. We tend to close primarily all sublingual graft donor sites and, when possible, all donor sites from the cheek. Even though there are conflicting reports as to the advantages and disadvantages of closure vs non-closure of oral graft donor sites, in our practice we find that patients experience significantly less pain and bleeding when the donor site is closed, at least in the early post-operative period.

A 16F silicone Foley urethral catheter is left in situ at the end of the procedure and the perineal wound is closed in layers over a corrugated drain which is removed on the first post-operative day. A suprapubic catheter is not used routinely. A pressure dressing is applied to the perineum and is removed the day following surgery and the patient discharged home. A peri-catheter urethrogram is performed 2 weeks after the surgery and if this shows no extravasation of contrast the catheter is removed.

#### Our experience with augmented non-transecting anastomotic bulbar urethroplasty

Between January 2009 and December 2014, 82 patients with non-traumatic bulbar strictures underwent one of the three non-transecting urethroplasty techniques described (Table 1). Of these,

**Table 1** Summary of cases managed by non-transecting urethroplasty.

	Heineke–Mikulicz strictuoplasty	NTABU	ANTABU
Number of cases	9 (11%)	47 (57%)	26 (32%)
Mean age (yrs)	34.8	36.8	46.7
Mean follow-up (mth)	20.1	14.6	14.8
Mean post-op flow-rate (ml/s)	24.3	34.8	26.6
Radiological Success rate	8 of 9 (88.9%)	46 of 47 (97.9%)	16 of 16 (100%)
Subjective Success rate	8 of 9 (88.9%)	45 of 47 (95.7%)	14 of 16 (87.5%)

26 (31.7%) were treated by ANTABU and all were carried out in the latter half of the series between July 2012 and December 2014. They were followed up clinically and by flow rate analysis at 4 months, 1 year and annually thereafter. Ascending and descending urethrography was performed at 4 months, 1 and 2 years. Patients were not routinely evaluated endoscopically. Subjective outcome was assessed by means of a validated Patient Reported Outcomes Measure (PROM) questionnaire [12,13] at each occasion.

Mean follow-up was 14.8 months (range 5.7–52.6 months). Postoperative urethrography was available in all patients and flow rates in 22 (84.6%). Pre and postoperative PROMS were filled by 20 of the 26 patients (76.9%). Failure was defined as patient dissatisfaction with the outcome, recurrent stricture on urethrogram or need for any other surgical intervention (including dilatation).

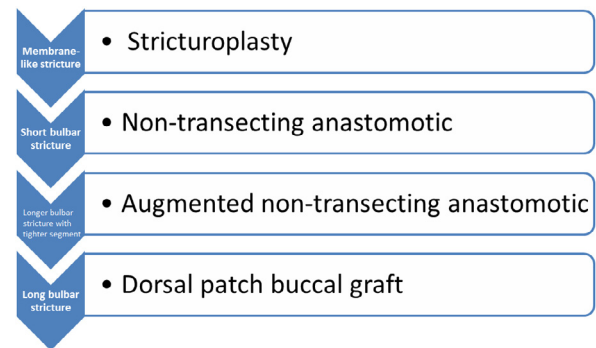
23 of 26 (88.5%) strictures were idiopathic while the other 3 (11.5%) were catheter-related. Mean stricture length was 5.3 cm (range 3–8 cm). The mean length of obliterative spongiofibrosis excised from the stricture in a non-transecting fashion was 1.2 cm (range 0.5–2 cm). The oral graft was harvested from the cheek in 22 (84.6%) patients and sublingually in the remaining 4 (15.4%).

None of the 26 patients had radiological evidence of stricture recurrence. The mean flow rate of the cohort at 1 year postoperatively was 26.6 ml/s. Those patients who had completed pre- and postoperative PROMS questionnaire reported a mean improvement of 11.4 points (range 3–21) in the lower urinary tract symptoms (LUTS) score. This LUTS score is based on 6 symptom questions with a total score ranging between 0 (least symptomatic) and 24. 19 of 20 patients (95%) reported that they were satisfied or very satisfied with the outcome of their surgery. The remaining patient who claimed that he was dissatisfied with the outcome had no evidence of stricture recurrence but still complained of poor flow and urodynamic assessment confirmed the presence of detrusor underactivity.

7 of the 26 patients (26.9%) developed some degree of post-micturition dribble following their surgery. In none of these does this cause any significant bother and they are all managing well by manually ‘milking’ the urethra. Erectile dysfunction lasting longer than 6 months and requiring treatment was reported in 1 patient (3.8%).

### Comment

Stricturotomy and augmentation with buccal mucosal graft have become the standard surgical approach to non-traumatic bulbar strictures which are too long to be amenable to excision or non-transecting anastomotic urethroplasty. The debate continues as to whether the graft should be placed dorsally or ventrally with arguments in favour and against both being cited [18].

**Figure 7** The stepwise approach to bulbar urethroplasty.

We prefer a dorsal approach to bulbar urethroplasty as the stricturotomy is carried out through the thinnest part of the spongiosum. The length of the stricture and degree of spongiofibrosis can be accurately assessed through this approach which provides the versatility to carry out any of the procedures described earlier, in a stepwise approach as depicted in Fig. 7, all without any vascular compromise to the urethra.

Dorsal onlay buccal mucosal graft urethroplasty for most bulbar strictures is associated with excellent success rates [8,19]. They are however less satisfactory in patients with a near obliterative stenosis as part of a longer stricture [20]. Non-transecting excision of the spongiofibrosis in this focal narrowed segment allows reconstitution of the urethral plate to an adequate calibre to allow successful augmentation with a buccal graft. A narrower graft is consequently required which is important for two main reasons. Firstly, it facilitates closure of the donor site, which has been shown to be associated with less morbidity [21]. Secondly, it assumes great significance when using sublingual grafts for longer strictures since these grafts are rarely more than 1 cm in width. Shortening of the ventral aspect by end-to-end mucosal anastomosis means that a shorter graft is generally necessary to augment the dorsal stricturotomy.

Some might argue that the results in this series may not be sustained in the long-term because the follow-up is relatively short. However, most stricture recurrences after urethroplasty become clinically apparent within the first 1–2 years of follow-up [22]. Therefore, we believe that a radiological stricture-free rate of 100% at a mean of 14.8 months augurs well for a satisfactory outcome in the longer term.

### Conclusion

The non-transecting approach to non-traumatic bulbar urethral strictures permits excision of the spongiofibrosis without

compromising the integrity of spongiosal blood flow. When coupled with oral mucosal graft augmentation of the dorsal stricturotomy, this allows excision of the narrowest segment of a longer bulbar stricture, reconstituting the urethral plate to a wider calibre, avoiding an almost circumferential substitution in this area. This also permits the use of narrower and shorter oral grafts with reduced donor site morbidity. We have demonstrated excellent results with this technique in the short to intermediate term.

## References

- [1] Mundy AR, Andrich DE. Urethral strictures. *BJU Int* 2011;107:6–26.
- [2] Morey AF, Watkin N, Shenfeld O, Eltahawy E, Giudice C. SIU/ICUD consultation on urethral strictures: anterior urethra – primary anastomosis. *Urology* 2014;83:S23–6.
- [3] Mundy AR. Anastomotic urethroplasty. *BJU Int* 2005;96:921–44.
- [4] Eltahawy Ea, Virasoro R, Schlossberg SM, McCammon Ka, Jordan GH. Long-term follow-up for excision and primary anastomosis for anterior urethral strictures. *J Urol* 2007;177:1803–6.
- [5] Santucci Ra, Mario La, McAninch JW. Anastomotic urethroplasty for bulbar urethral stricture: analysis of 168 patients. *J Urol* 2002;167:1715–9.
- [6] Andrich DE, Mundy AR. Non-transecting anastomotic bulbar urethroplasty: a preliminary report. *BJU Int* 2012;109:1090–4.
- [7] Guralnick ML, Webster GD. The augmented anastomotic urethroplasty: indications and outcome in 29 patients. *J Urol* 2001;165:1496–501.
- [8] Barbagli G, Guazzoni G, Lazzeri M. One-stage bulbar urethroplasty: retrospective analysis of the results in 375 patients. *Eur Urol* 2008;53:828–33.
- [9] Mundy AR, Andrich DE. Non-transecting bulbar urethroplasty. In: Brandes SB, Morey AF, editors. *Advanced male urethral genital reconstructive surgery*. 2014. p. 531–40.
- [10] Cavalcanti AG, Costa WS, Baskin LS, McAninch Ja, Sampaio FJB. A morphometric analysis of bulbar urethral strictures. *BJU Int* 2007;100:397–402.
- [11] Jordan GH, Eltahawy EA, Virasoro R. The technique of vessel sparing excision and primary anastomosis for proximal bulbous urethral reconstruction. *J Urol* 2007;177:1799–802.
- [12] Jackson MJ, Chaudhury I, Mangera A, Brett A, Watkin N, Chapple CR, et al. A prospective patient-centred evaluation of urethroplasty for anterior urethral stricture using a validated patient-reported outcome measure. *Eur Urol* 2013;64:777–82.
- [13] Jackson MJ, Sciberras J, Mangera A, Brett A, Watkin N, N'dow JMO, et al. Defining a patient-reported outcome measure for urethral stricture surgery. *Eur Urol* 2011;60:60–8.
- [14] Andrich DE, Mundy AR. Complications of social lithotomy. *BJU Int* 2010;106:40–1.
- [15] Pocivavsek L, Efrati E, Lee KYC, Hurst RD. Three-dimensional geometry of the Heineke–Mikulicz strictureplasty. *Inflamm Bowel Dis* 2013;19:704–11.
- [16] Bugeja S, Andrich DE, Mundy AR. Non-transecting bulbar urethroplasty. *Transl Androl Urol* 2015;4:41–50.
- [17] Andrich DE, Mundy AR. What is the best technique for urethroplasty? *Eur Urol* 2008;54:1031–41.
- [18] Barbagli G, Palminteri E, Guazzoni G, Montorsi F, Turini D, Lazzeri M. Bulbar urethroplasty using buccal mucosa grafts placed on the ventral, dorsal or lateral surface of the urethra: are results affected by the surgical technique? *J Urol* 2005;174:955–7, discussion 957–8.
- [19] Mangera A, Patterson JM, Chapple CR. A systematic review of graft augmentation urethroplasty techniques for the treatment of anterior urethral strictures. *Eur Urol* 2011;59:797–814.
- [20] Welk BK, Kodama RT. The augmented nontransected anastomotic urethroplasty for the treatment of bulbar urethral strictures. *Urology* 2012;79:917–21.
- [21] Rourke K, McKinny S, St Martin B. Effect of wound closure on buccal mucosal graft harvest site morbidity: results of a randomized prospective trial. *J Urol* 2012;79:443–7.
- [22] Meeks JJ, Erickson Ba, Granieri Ma, Gonzalez CM. Stricture recurrence after urethroplasty: a systematic review. *J Urol* 2009;182:1266–70.