



African Journal of Urology

Official journal of the Pan African Urological Surgeons' Association
web page of the journal

www.ees.elsevier.com/afju
www.sciencedirect.com



Review

Ventral onlay graft bulbar urethroplasty using buccal mucosa



H. Wessells

Department of Urology, University of Washington, 1959 Pacific Avenue NE, Box 356510, Seattle, WA 98195, United States

Received 29 October 2015; accepted 29 October 2015

Available online 21 January 2016

KEYWORDS

Urethra;
Stricture;
Free graft;
Substitution

Abstract

Objective: To assess the ongoing role of ventral onlay oral mucosa free graft in the treatment of bulbar urethral stricture.

Methods: Detailed review of technical consideration and outcomes from the author's institution along with review of other peer reviewed literature.

Results: Of 62 patients undergoing ventral onlay buccal mucosa urethroplasty, 19% had recurrence of stricture, and an additional 5% exhibited diverticulum formation. Complications were self-limited. Previously published case series and meta-analysis demonstrate similar results.

Conclusion: Ventral onlay remains an effective and versatile part of the armamentarium for bulbar urethral stricture.

© 2015 Pan African Urological Surgeons' Association. Production and hosting by Elsevier B.V. All rights reserved.

Introduction

Urethral strictures have plagued men since antiquity, with etiologic evolution reflecting changes in population distribution, human diseases, occupational hazards, and environmental factors [1]. African urologists have contributed substantially to the advance in techniques of urethroplasty, notably Quartey [2] who sought to reconstruct long bulbar urethral strictures due to gonococcal

urethritis, and El-Kasaby [3], a pioneer in the use of buccal mucosa for anterior urethroplasty. Bulbar urethral strictures, due to anatomical and etiological differences from strictures in the penile urethra, can be treated effectively with very high success rates. In this location, stricture outcomes are less impacted by variables such as prior irradiation; comorbid medical conditions; deficiencies in genital skin; or lichen sclerosus. However, due the greater ease and safety of endoscopic procedures, many patients undergo innumerable dilations or internal urethrotomies, even when success is unlikely [4]. The long-term consequence of this practice pattern will be to increase the length of strictures, rendering some unsuitable for primary anastomotic repair and instead requiring substitution procedures such as oral graft urethroplasty.

E-mail address: wessells@uw.edu

Peer review under responsibility of Pan African Urological Surgeons' Association.

<http://dx.doi.org/10.1016/j.afju.2015.10.001>

1110-5704/© 2015 Pan African Urological Surgeons' Association. Production and hosting by Elsevier B.V. All rights reserved.

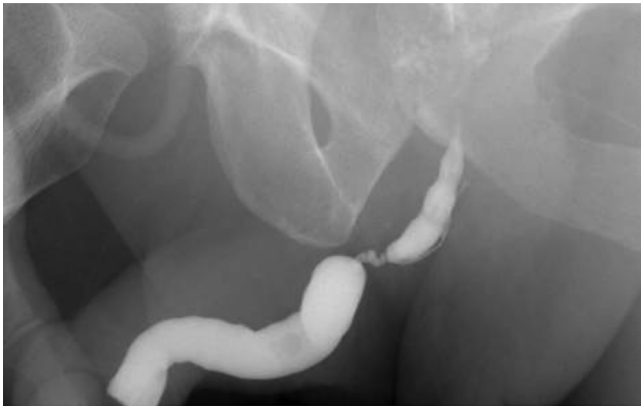

Figure 1 Retrograde urethrogram showing a 2.5 cm proximal bulbar stricture.

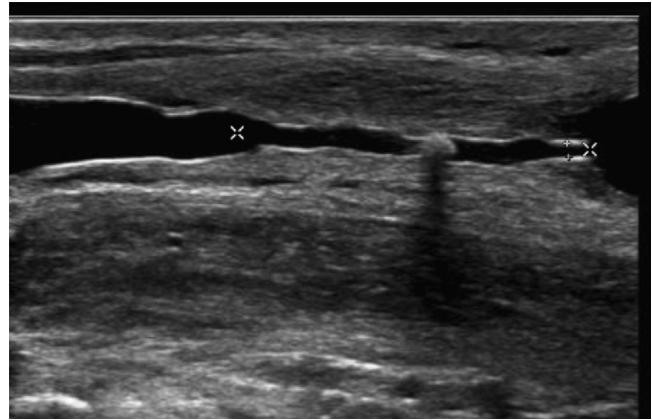


Figure 2 Ultrasound urethrogram showing details of stricture from Fig. 1. Note small stone in midsection of stricture, and narrowness of lumen.

Contemporary urethral stricture disease in the United States most commonly is caused by idiopathic and traumatic causes [5]. Although accurate statistics have not been determined for African men, traumatic bulbar urethral strictures are postulated to predominate, reflecting the burden of motor vehicle, pedestrian, and other transport injuries, and war, on young men across the continent. The Global Burden of Disease Study 2013 ranks these as major sources of disability worldwide, with a greater burden in developing countries [6]. In contrast, iatrogenic and idiopathic causes will increase in prevalence in parallel with the increasing frequency of urological interventions in the aging male across the world. This paper reviews the diagnostic concerns, technique, and outcomes of substitution urethroplasty using ventrally placed oral mucosa and speculates on the future of urethroplasty.

Methods

Preoperative evaluation

Cystoscopy is a simple way to confirm the presence of suspected urethral stricture disease. However, it has limited value in preoperative planning because it cannot determine the length of the stricture or the status of the more proximal urethra. This is of particular importance to the current discussion, because ventral onlay approach allows easy extension of the substitution “onlay” or “patch graft” into the most proximal portions of the anterior urethra.

The combination of retrograde urethrogram and voiding cystourethrogram accurately assesses the bulbar urethra and determination of the length of a stricture along with its functional significance. Techniques for retrograde and voiding urethrography have been reviewed elsewhere [7]. However, one point requires elaboration related to *bulbar* urethral stricture: the penis must be adequately stretched so that the pendulous portion of the penile urethra and the penoscrotal junction are appropriately visualized (Fig. 1).

Ultrasonography [8] provides a very accurate delineation of a bulbar urethral stricture and may be valuable in assessing the luminal diameter of the stricture (Fig. 2), which determines strategies for addressing very narrow portions of a longer stricture (see below).

Reconstructive considerations

Antegrade and retrograde blood supply of the corpus spongiosum is key to successful bulbar urethroplasty because it affords the reconstructive surgeon the ability to mobilize, excise [9] and reanastomose the urethral plate in combination with free graft tissue transfer [10]. However, many strictures exceed the limits of urethral mobilization and primary anastomosis, leading to the innovations in substitution urethroplasty. Free grafts have been used for reconstruction of complex urethral strictures since the 1960s [11]. No controlled clinical study has definitively shown superiority of oral mucosa to full thickness genital skin, and odds of recurrence are similar to earlier series using penile skin [12]. Nevertheless, ease of harvesting and lack of donor site morbidity have led to widespread adoption of oral mucosa for substitution urethroplasty.

A brief algorithm for the treatment for urethra strictures is shown in Fig. 3. Strictures greater than 2 cm in length in the bulbar urethra generally require substitution urethroplasty with a free graft, although longer gaps can be bridged depending on the elasticity of

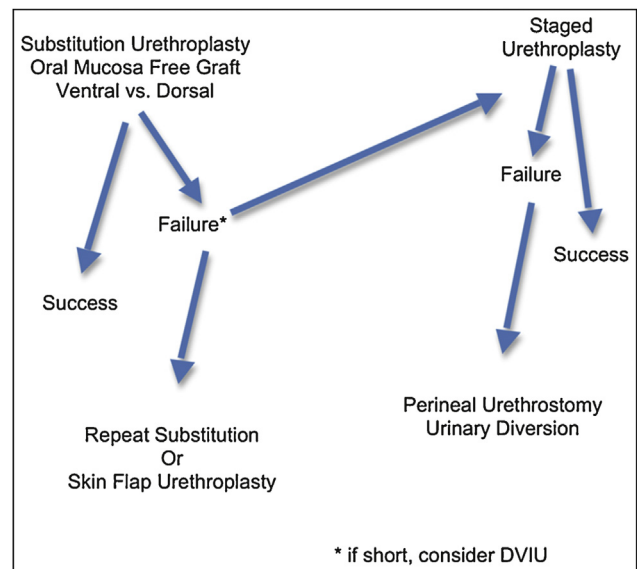


Figure 3 Algorithm for the treatment of bulbar urethral stricture.

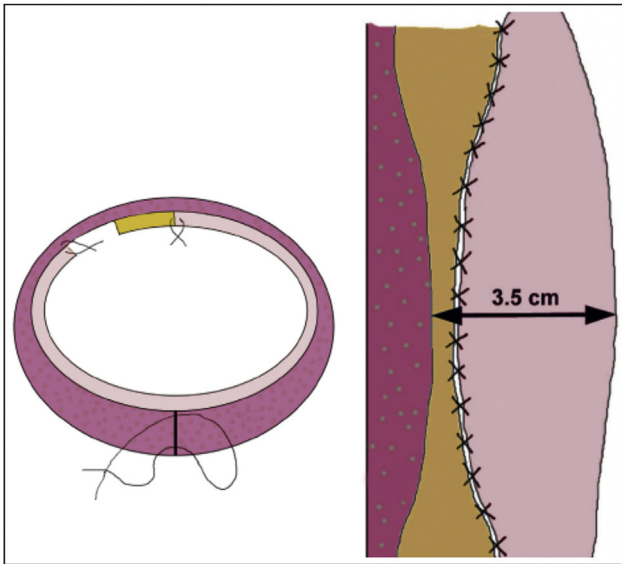


Figure 4 Schematic of how to address narrowing of urethral plate without excision of the stricture (from Barbagli et al. [19], with permission).

the corpus spongiosum and location of the stricture [13]. Systematic review suggests that dorsal grafting offers equal success rates compared to ventral [14,15]; in our hands the rates of success were not statistically different (85% vs. 81%) [16]. An earlier single institution series suggested equal outcomes for penile skin versus buccal mucosa [17], but more recent systematic review suggests inferior outcomes for penile skin [15]; few centers can achieve success rates above 90% with long term follow up [18]. The higher rate of success of dorsal onlay determined in some case series may reflect lead time bias in the earlier literature, because ventral onlay techniques have been disseminated for a longer time interval than dorsal.

When a segment of a bulbar urethral stricture is obliterated or nearly obliterated the reconstruction must address the narrowest portion, either by excision of the most severe portion of the stricture, with dorsal reanastomosis and ventral onlay reconstruction (augmented anastomotic urethroplasty [9]) or using a strategy advanced by Barbagli and associates [19] in which a portion of the spongiosum is not covered with the graft and allowed to heal by secondary intention (see Fig. 4). This latter conceptual advance may reduce the need to perform augmented anastomotic procedures.

Surgical technique

Patients undergoing bulbar urethroplasty require the lithotomy position. An experienced member of the surgical team should position the legs to minimize potential compression of the peroneal nerve or excessive flexion of the knee. Risk of lower extremity complications is influenced by use of Trendelenberg, knee position, external compression, method of leg support, duration of surgery, and patient factors including age and body mass index [20–22].

The technique of oral mucosa harvesting is covered elsewhere in this edition and for the sake of brevity will not be repeated [23]. Optimal graft take depends on imbibition of nutrients and thus all fat and muscle are removed from the undersurface of the graft.

Ventral onlay free graft substitution takes advantage of outstanding visualization of the proximal-most bulbar urethra and the excellent vascularity of the recipient site. Exposure of the corpus spongiosum requires that the surgeon either split the overlying bulbospongiosus muscle in the midline, or follow the more contemporary vogue of mobilization and retraction of the muscle. Extensive mobilization of the corpus spongiosum is not required with ventral onlay, and its vascular supply from perforators originating in the corpus cavernosum should not be sacrificed.

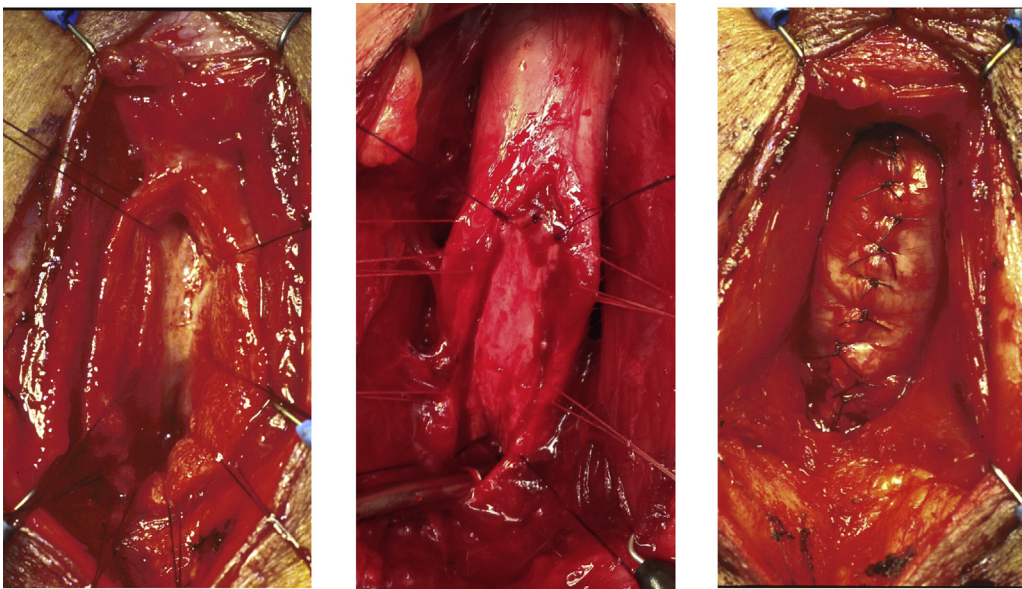


Figure 5 **Ventral onlay graft.** (a) Ventral urethrotomy in anticipation of ventral onlay substitution urethroplasty. (b) Ventral placement of buccal mucosa free graft. (c) Spongioplasty after ventral onlay free graft.

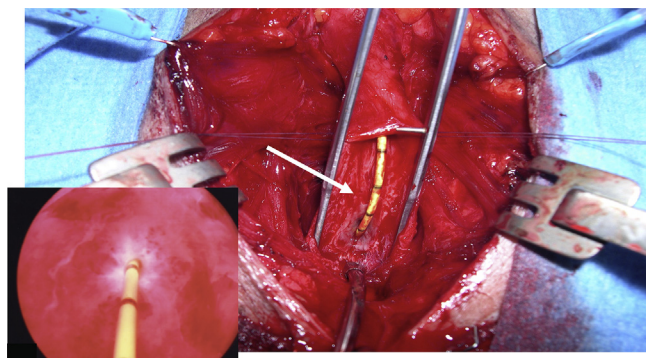


Figure 6 Augmented anastomotic urethroplasty by ventral onlay for a long bulbar urethral stricture. Inset shows appearance of the distal aspect of a very tight segment of a longer stricture. Arrow shows spongiosum after ventral urethrotomy.

The distal extent of the stricture is marked using a 20 Fr. catheter, placed *per urethra* until resistance is met. Barbagli and Kulkari (personal communication, May 17, 2015) suggest that ventral onlay is ideal for strictures in which the distal-most extent of the stricture is **proximal** to the distal margin of the bulbospongiosus muscle. The implication is that the stricture extends closer to the external sphincter proximally, in which case ventral approach allows superb visualization and precise suturing of the onlay graft as far proximal as the *veru montanum*.

A ventral urethrotomy must be made through the entire length of the stricture, extending into healthy urethral epithelium and spongy tissue (Fig. 5). By placing stay sutures through the ventral surface of the corpus spongiosum, at the level of the catheter tip, the corpus spongiosum is incised in the ventral midline with a scalpel until the catheter is exposed. The urethrotomy is then extended proximally, placing additional full thickness stay sutures at close intervals for hemostasis and to aid subsequent identification of the mucosal for anastomosis. The urethrotomy is extended until the entire stricture has been incised.

Proximal and distal calibration of the urethra should confirm a minimal urethral lumen of 28 Fr. The apex of graft is anastomosed to the proximal apex of the urethrotomy with a series of interrupted sutures; running 5-zero absorbable suture then completes the anastomosis along each side of the graft. The distal graft is then trimmed to size and approximated to the distal apex with interrupted sutures (Fig. 5). The apical lumen is calibrated and a 16 Fr Foley catheter inserted before or after completion of graft suturing. Next, to support the graft and allow appropriate take, the corpus spongiosum is closed with interrupted 4–0 absorbable sutures (Fig. 5).

If a portion of the stricture is extremely fibrotic or narrow (Fig. 6), the underlying graft bed may be poor or the spongiosum may not adequately cover the graft. In such cases excision of that portion of the stricture, followed by dorsal reanastomosis, should be performed in conjunction with grafting (Figs. 7 and 8).

To finish the closure, the bulbospongiosus muscle, Colles' fascia, and skin are all closed with interrupted or running absorbable sutures. Drains are rarely required with ventral onlay because the spongiosal closure is very hemostatic.

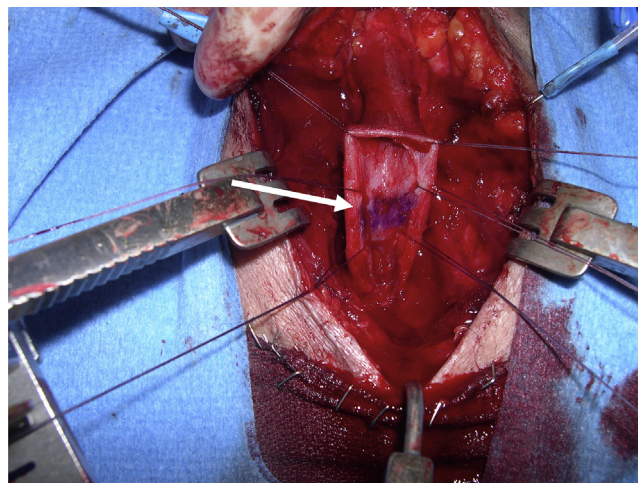


Figure 7 Augmented anastomotic urethroplasty. Segment of obliteration, with no visible mucosa, marked with ink for excision (arrow).

Postoperative care and follow up

Patients undergoing bulbar urethroplasty can be discharged in less than 24 h. Routine catheter care and limited physical activity are observed until a voiding cystourethrogram or pericatheter retrograde urethrogram is performed at week 2. If contrast extravasation persists, the catheter is replaced and a repeat study is completed in 1–2 weeks. If the amount of extravasation is minor, voiding is allowed or catheter drainage is reinstated for one more week without repeat imaging. Patients refrain from sexual activity for 4 weeks. Perineal precautions limit pressure on the repair and prohibit bicycle riding for 3 months.

Results

Patient characteristics

We previously reported our combined outcomes of dorsal and ventral onlay bulbar urethroplasty [16]; the current analysis is restricted to the subset of patients who underwent ventral onlay. Mean age of these 62 patients was 40 years, and strictures had undergone prior intervention in 87%. Stricture length averaged 3.9 cm, indicating the need for substitution urethroplasty. The other demographic features were not relevant to technique or outcomes. Intraoperative bleeding is modestly high with ventral onlay, but none of the 62 required transfusion (data not shown).

Complications

Minor surgical complications include incisional bleeding, hematuria, and diverticulum formation, occurred in less than 5% of patients after substitution urethroplasty [16]. Complications of the lithotomy position can include peroneal neuropraxia, back pain, and rare compartmental syndrome of the calf. None occurred in the current sample. Other complications of urethroplasty include infection, fistula formation, sexual dysfunction and stricture recurrence (see below).

Donor site complications include contraction, pain or minor difficulties with food or saliva. Sexual dysfunction occurs after urethroplasty and therefore baseline assessment of function is

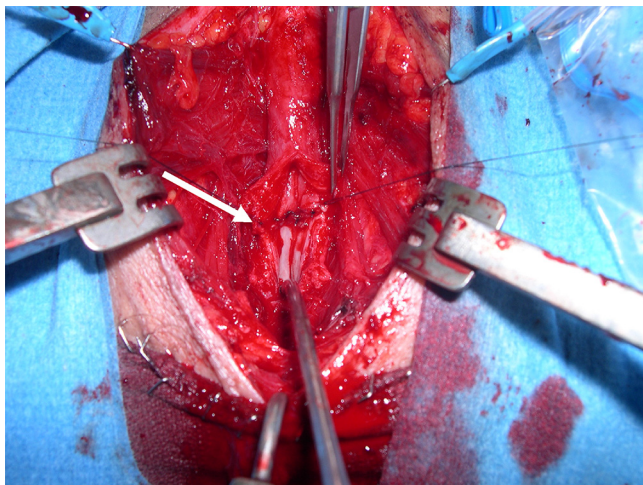


Figure 8 Augmented anastomotic urethroplasty. Reapproximation of dorsal urethral plate (arrow) after excision of portion of stricture, the so-called “roof strip anastomosis”.

advisable. Approximately 40% of men experience a degree of erectile dysfunction after urethroplasty, although the majority return to baseline within 1 year [24–27]. Orgasmic dysfunction, in particular abnormal ejaculation, is prevalent in men with urethral stricture disease, and is likely to improve postoperatively [25].

Outcomes and follow up

No consensus method of follow up after urethroplasty has been consistently adopted worldwide [28]. We assess outcomes with uroflowmetry and cystoscopy at 3 and 12 months, and then expectantly after the first year. Our rate of stricture recurrence after ventral onlay, defined by need for repeat intervention for the stricture, with a mean follow up of 38 months was 19% (see Table 1). Time to recurrence was up to 5 years after surgery. The majority of recurrent strictures occur at either the proximal or distal end of the graft. These create ring-like narrowing that spares the majority of the graft, and require DVIU. Approximately 5% of patients required repeat urethroplasty, which may be by anastomotic techniques if isolated to one end of the grafted urethra, or by repeat substitution using a dorsal oral mucosa graft onlay approach or a ventral skin flap urethroplasty. With a small sample size, analysis of variables that predict failure is limited.

Discussion

Ventral onlay buccal mucosa urethroplasty is the workhorse of bulbar urethroplasty for many reconstructive surgeons. Easy visualization of the corpus spongiosum and urethra, excellent support of the free graft with ventral spongioplasty, and optimal access to the most proximal portion of the bulbar urethra offer advantages over dorsal onlay. Our findings are consistent with prior systematic reviews [14,15], showing success rates of 81%. Current evidence, although of low quality, demonstrates non-inferiority of ventral onlay to dorsal. A randomized controlled trial or large pragmatic trial would be necessary to definitively answer this question. Given the similarly low rate of recurrence, such a study would require a very large sample size. Several randomized trials exist in bulbar urethroplasty, but they all compare dorsal oral mucosa graft to penile skin flap [29].

Table 1

| | Ventral onlay (N=62) |
|-------------------------------------|----------------------|
| Demographic characteristics | |
| Age, yrs (SD) | 40.1 (13.3) |
| BMI, kg/m ² (SD) | 30.2 (7.3) |
| Diabetes, N (%) | 5 (8%) |
| Current smoker, N (%) | 7 (11%) |
| Stricture characteristics | |
| Etiology, N (%) | |
| Trauma/Instrumentation | 25 (40%) |
| Lichen sclerosis/infection | 5 (8%) |
| Hypospadias | 2 (3%) |
| Radiation | 3 (5%) |
| Unknown | 27 (43%) |
| Prior procedure, N (%) | |
| Prior DVIU, N (%) | 44 (71%) |
| Prior dilation, N (%) | 33 (53%) |
| Prior urethroplasty, N (%) | 5 (8%) |
| Prior stent, N (%) | 4 (6%) |
| Surgical characteristics | |
| Stricture length, cm (SD) | 3.9 (1.17) |
| Graft size, cm ² (SD) | 9.5 (1.91) |
| Augmented anastomosis, N (%) | 9 (15%) |
| Surgical complications | |
| Mean follow-up, months | 38.2 (34.6) |
| Incisional bleeding, N (%) | 1 (1.6%) |
| Hematuria, N (%) | 1 (1.6%) |
| Diverticulum, N (%) | 3 (5%) |
| Failure, N (%) | 12 (19%) |
| Mean time to failure, months (SD) | 67.6 (72.2) |
| Failure – initial management, N (%) | |
| DVIU | 8 (13%) |
| Urethroplasty | 3 (5%) |
| SP tube | 1 (2%) |

Adapted from Figler et al. [16].

It is likely that the majority of case series in the literature have significant selection bias introduced by the decision to place a graft either dorsally or ventrally. In our series division of the urethral plate was performed with both ventral and dorsal onlay procedures (i.e. augmented anastomotic urethroplasty), and did not portend a higher failure rate [16]. Theorizing that the division of the plate may affect the spongiosal vascular support of the graft, we have used dorsal onlay more commonly in these settings (data not shown). Thus we have more recently used ventral onlay for strictures that do not require augmented anastomotic techniques, and therefore may be less complex.

The successful reconstructive urologist must develop skills in both ventral and dorsal onlay; the decision is complex and requires a synthesis of information including etiology, location, length and degree of narrowing of the stricture; knowledge of prior surgical interventions; and graft bed and donor site considerations. A novel application of the concept of ventral onlay free graft demonstrates its enduring value. Zinman and associates [30] recently described ventral buccal onlay for some of the most complex strictures, using the gracilis muscle flap as a vascularized bed for engraftment that can overcome severely compromised urethral pathology. The grand challenges of urethral reconstruction relate to absence of tissue for transfer, absence of tissue for coverage, and severe compromise of the urethral bed. Thus, epispadias and hypospadias, radiation, battlefield injuries, and necrotizing soft tissue infection create almost unsalvageable urethral conditions. The severe proximal bulbar and

membranous urethral stricture, constrained physically by the separation of the crura, presence of the bony pubis, and watershed vascular supply between the prostatic and bulbar urethra, prevent the use of staged procedures with any effectiveness.

Classic ventral and dorsal onlay procedures remain the workhorse of bulbar urethra reconstruction and have been carefully described here and elsewhere in this edition. However, when prior stenting, prostatectomy, radiation, straddle injury, or pelvic fracture creates obliteration and full thickness fibrotic defects, options become limited. If the segment of abnormal urethra exceeds the elasticity and extensibility of the bulbar urethra, and the two ends cannot be reapproximated, prospects are grim. The alternatives are unsatisfactory: tubularized skin flaps, hair bearing tissue transfer, or radical solution such as forearm free flap urethra reconstruction [33]. Engineered urethra substitutes [31] and engineered epithelial grafts [32] will prove to be important future solutions to this grand challenge. In the meantime, however, the strategy described by Zinman and associates [30] represents a significant conceptual advance and alternative surgical strategy for some of the most difficult strictures.

The ability to successfully perform free graft urethroplasty in the most unfit and compromised beds is a major step forward. Applying their extensive experience using the gracilis muscle flap in rectourethral fistula repair, the buccal mucosa ventral onlay graft is re-envisioned. Until engineered solutions can provide not only urothelium and smooth muscle, but also the molecular signals for improved vascularization of the construct, the strategy described by Zinman and associates is the next best thing.

Conclusion

Ventral onlay buccal mucosa urethroplasty has stood the test of time and offers a straightforward successful solution for long strictures in the bulbar urethra. With outcomes comparable to dorsal onlay, a greater ease of dissection, exposure, and graft placement, it merits continued use. Conceptual advances such as the augmented anastomotic approach and the gracilis muscle support will extend its use and increase probability of long term success in patients with compromised urethras.

Conflict of interest

No conflict of interest.

References

- [1] Santucci RA, Joyce GF, Wise M. Male urethral stricture disease. *J Urol* 2007;177:1667–74.
- [2] Quartey JKM. One stage penile/preputial island flap urethroplasty for urethral stricture. *J Urol* 1985;134:474.
- [3] El-Kasaby AW, Fath-Alla M, Noweir AM, El-Halaby MR, Zakaria W, El-Beialy MH. The use of buccal mucosa patch graft in the management of anterior urethral strictures. *J Urol* 1993;149:276.
- [4] Figler BD, Gore JL, Holt SK, Voelzke BB, Wessells H. High regional variation in urethroplasty in the United States. *J Urol* 2015;193:179–83.
- [5] Fenton AS, Morey AF, Aviles R, Garcia CR. Anterior urethral strictures: etiology and characteristics. *Urology* 2005;65:1055–8.
- [6] Vos T, Barber RM, Bell B, Bertozzi-Villa A, Biryukov S, Bolliger, et al. Global, regional, and national incidence, prevalence, and years lived with disability for 301 acute and chronic diseases and injuries in 188 countries, 1990–2013: a systematic analysis for the Global Burden of Disease Study 2013. *Lancet* 2015;9995:743–800.
- [7] McCallum RW. The adult male urethra: normal anatomy, pathology, and method of urethrography. *Radiol Clin North Am* 1979;17:227–44.
- [8] Morey AF, McAninch JW. Sonographic staging of anterior urethral strictures. *J Urol* 2000;163:1070–5.
- [9] Guralnick ML, Webster GD. The augmented anastomotic urethroplasty: indications and outcome in 29 patients. *J Urol* 2001;165:1496–501.
- [10] Wessells H, Morey AF, McAninch JW. Single stage reconstruction of complex anterior urethral strictures: combined tissue transfer techniques. *J Urol* 1997;175:1271–4.
- [11] Devine PC, Horton CE, Devin Sr CJ, Devine Jr CJ, Crawford HH, Adamson JE. Use of full thickness skin grafts in repair of urethral strictures. *J Urol* 1963;90:67–71.
- [12] Wessells H, McAninch JW. Current controversies in anterior urethral stricture repair: free-graft versus pedicled skin-flap reconstruction. *World J Urol* 1998;16:175–80.
- [13] Morey AF, Kizer WS. Proximal bulbar urethroplasty via extended anastomotic approach—what are the limits? *J Urol* 2006;175:2145–9.
- [14] Mangera A, Patterson JM, Chapple CR. Systematic review of graft augmentation urethroplasty techniques for the treatment of anterior urethral strictures. *Eur Urol* 2011;59:797–814.
- [15] Wang K, Miao X, Wang L, Li H. Dorsal onlay versus ventral onlay urethroplasty for anterior urethral stricture: a meta-analysis. *Urol Int* 2009;83:342–8.
- [16] Figler BD, Malaeb BS, Dy GW, Voelzke BB, Wessells H. Impact of graft position on failure of single-stage bulbar urethroplasties with buccal mucosa graft. *Urology* 2013;82:1166–70.
- [17] Wessells H, McAninch JW. Use of free grafts in urethral stricture reconstruction. *J Urol* 1996;155:1912–5.
- [18] Barbagli G, Kulkarni SB, Fossati N, Larcher A, Sansalone S, Guazzoni G, et al. Long term follow-up and deterioration rate of anterior substitution urethroplasty. *J Urol* 2014, pii:S0022-5347(14)00293-6 [epub ahead of print].
- [19] Barbagli G, Montorsi F, Guazzoni G, Larcher A, Fossati N, Sansalone S, et al. Ventral oral mucosal onlay graft urethroplasty in nontraumatic bulbar urethral strictures: surgical technique and multivariable analysis of results in 214 patients. *Eur Urol* 2013;64:440–7.
- [20] Angermeir KW, Jordan GH. Complications of the exaggerated lithotomy position: a review of 177 cases. *J Urol* 1994;151:866–8.
- [21] Anema JG, Morey AF, McAninch JW, Mario LA, Wessells H. Complications related to the high lithotomy position during urethral reconstruction. *J Urol* 2000;164:360–3.
- [22] Beraldo S, Dodds SR. Lower limb acute compartment syndrome after colorectal surgery in prolonged lithotomy position. *Dis Colon Rectum* 2006;49:1772–80.
- [23] Markiewicz MR, Lukose MA, Margarone 3rd JE, Barbagli G, Miller KS, Chuang SK. The oral mucosa graft: a systematic review. *J Urol* 2007;179:387–94.
- [24] Anger JT, Sherman ND, Webster GD. The effects of bulbar urethroplasty on erectile function. *J Urol* 2007;178:1009–11.
- [25] Erickson BA, Granieri MA, Meeks JJ, Cashy JP, Gonzalez CM. Prospective analysis of erectile dysfunction after anterior urethroplasty: incidence and recovery function. *J Urol* 2010;183:657–61.
- [26] Feng C, Xu YM, Barbagli G, Lazzeri M, Tang CY, Fu Q, et al. The relationship between erectile dysfunction and open urethroplasty: a systematic review and meta-analysis. *J Sex Med* 2013;10:2060–8.
- [27] Blaschko SD, Sanford MT, Cinman NM, McAninch JW, Breyer BN. De novo erectile dysfunction after anterior urethroplasty: a systematic review and meta-analysis. *BJU Int* 2013;112:655–63.
- [28] Jordan G, Chapple C, Heyns C, editors. Urethral strictures. An international consultation on urethral strictures. Montreal: Societe Internationale d'Urologie; 2010.
- [29] Dubey D, Vijian V, Kapoor R, Srivastava A, Mandhani A, Kumar A, et al. Dorsal onlay buccal mucosa versus penile skin flap urethroplasty

- for anterior urethral strictures: results from a randomized prospective trial. *J Urol* 2007;178:2466–9.
- [30] Palmer DA, Buckley JC, Zinman LN, Vanni AJ. Urethroplasty for high risk, long segment urethral strictures with ventral buccal mucosa graft and gracilis muscle flap. *J Urol* 2015;193:902–5.
- [31] Raya-Rivera A, Esquiliano DR, Yoo JJ, Lopez-Bayghen E, Soker S, Atala A. Tissue-engineered autologous urethras for patients who need reconstruction: an observational study. *Lancet* 2011;9773:1175–82.
- [32] Osman NI, Hillary C, Bullock AJ, MacNeil S, Chapple CR. Tissue engineered buccal mucosa for urethroplasty: progress and future directions. *Adv Drug Deliv Rev* 2015;69–76:82–3.
- [33] Nelson AK, Wessells H, Friedrich JB. Review of microsurgical posterior urethral reconstruction. *J Reconstr Microsurg* 2011;27:179–86.