



## African Journal of Urology

Official journal of the Pan African Urological Surgeons' Association  
web page of the journal

[www.ees.elsevier.com/afju](http://www.ees.elsevier.com/afju)  
[www.sciencedirect.com](http://www.sciencedirect.com)



### Review

# Management of anterior urethral strictures with buccal mucosa: Our pioneering experience



Abdelwahab Elkassaby\*, Mohamed Kotb

*Department of Urology, Faculty of Medicine, Ain Shams University, Egypt*

Received 21 January 2016; accepted 25 January 2016

Available online 2 March 2016

#### KEYWORDS

Anterior urethral strictures;  
Urethroplasty;  
Buccal mucosa graft

#### Abstract

Urethral stricture management is a challenging surgery. Multiplicity of techniques means that none of them is ideal. No single technique is appropriate for all situations and the successful surgeon should have a store of operations to choose from according to each specific case. This review aims to provide an update on the different uses of buccal mucosal graft as a reconstructive and replacement tool for anterior urethral strictures management.

© 2016 Pan African Urological Surgeons' Association. Production and hosting by Elsevier B.V. All rights reserved.

#### Historical background

Buccal mucosa graft (BMG) was first use as a urethral reconstructing tool by Humby in 1941. He used a lower lip graft for a patient with multiple hypospadias repair presented with penoscrotal fistula [1]. This was followed by a long period of inactivity.

In 1978, we started using buccal mucosal grafts for management of crippled hypospadias. Preliminary results were not encouraging. The first published series were by Burger et al., in 1992, who described the use of buccal mucosal graft in six patients; three of them with prior failed hypospadias repair and shortage of genital

skin [2]. Again the results were unsatisfactory till 1995, when Duckett et al. successfully used buccal mucosa for urethral reconstruction after hypospadias, epispadias and urethral strictures [3].

In 1993, El-Kassaby et al. published the first series for anterior urethral stricture repair using buccal mucosal grafts. 20 patients underwent 1-stage correction of an anterior urethral stricture using a buccal mucosa patch graft. This technique was used for short strictures (1–2 cm) that usually required a 2–4 cm repair. Results were successful in 18 patients, while 2 redo surgery for recurrent stricture [4].

#### Anatomic and histologic considerations

The oral mucosa is the mucous membrane lining the inner aspect of the mouth. It has two major layers, namely the epithelium and the underlying connective tissue (termed lamina propria). Another

\* Corresponding author.

Peer review under responsibility of Pan African Urological Surgeons' Association.

submucosa layer can be found just beneath the lamina propria and is not easily discriminated from it [5]. Oral mucosa could be further subdivided into three categories (based on function and histology); Masticatory, Lining and Specialized mucosa.

Masticatory mucosa is formed of keratinized stratified squamous epithelium, found on the dorsum of the tongue, hard palate and attached gingiva. Its structure allows it to resist the abrasion of rough food particles.

Lining mucosa is formed of nonkeratinized stratified squamous epithelium, found almost everywhere else in the oral cavity, including buccal, labial and alveolar mucosa [5,6].

- Buccal mucosa refers to the membrane lining of the inner surface of the cheeks from the line of contact of the opposing lips anteriorly to the line of the pterygomandibular raphe (lateral to retromolar trigone) posteriorly. The medial boundary is the line of attachment of the buccal mucosa to the upper and lower alveolar ridges superiorly and inferiorly. It consists of stratified squamous epithelium (oral epithelium) and an underlying connective tissue (lamina propria) [7].
- Labial mucosa refers to the inside lining of the lips.
- Alveolar mucosa refers to the mucosa between the gums and the buccal/labial mucosa.

Specialized mucosa found specifically in the regions of the taste buds on lingual papillae on the dorsal surface of the tongue that contains nerve endings for general sensory reception and taste perception [5,6].

### Anterior urethral strictures

The anterior urethral stricture equals narrowing of the anterior urethra. The pathology is explained mainly by fibrosis and scarring of the urethral epithelium together with the spongy erectile tissue of corpus spongiosum [8].

### Etiology of anterior urethral strictures

Too many causes participate in this process. Infection, trauma and lichen sclerosis are considered as the most common etiologies. However, most causes of urethral strictures remain unknown, but they are probably due to a remote unrecognized perineal trauma or recurrent attacks of urethral mild infections (as *Neisseria gonorrhoea* or *Chlamydia*) [9].

The pathological process includes injury to the urethral epithelium or the underlying corpus spongiosum leading to healing by a scar which ends by an anterior urethral stricture. Trauma, usually straddle, either presents as acute retention and urethral bleeding, or more often goes unrecognized and presents later with obstructive voiding complaints. Iatrogenic trauma to the urethra could be the cause, as catheterization and endoscopic procedures, but it decreases with fine manipulation of the urethra [10].

Lichen sclerosus et atrophicus is another common chronic inflammatory condition that affects the anterior urethra as well as the foreskin and glans. It is considered as a frequent cause of phimosis, meatal stenosis and long anterior strictures.

Use of skin in reconstruction of the urethra frequently results in re-stricturing due to recurrent lichen sclerosis or to Koebner phenomenon which is recurrence of the skin condition in diseased skin [11].

Lichen sclerosis characterized with uncertain etiology, varied presentation, and multiple treatments. In early stages, a short course of steroids, topical or systemic, can control the disease and prevent progression. Surgical treatment by circumcision can be curative if the disease is treated early when still localized. Progression to long segment stricture or panurethral stricture will necessitate more sophisticated management [12].

### Presentation of urethral stricture patients

These patients usually present with lower urinary tract obstructive symptoms or recurrent urinary tract infections such as prostatitis or epididymitis. Some patients also present with urinary retention. But with detailed history, most of these patients are found to have tolerated notable voiding obstructive symptoms for a long period of time before progressing to complete obstruction [10].

### Evaluation of anterior urethral strictures

To start treatment, the nature of the stricture including stricture anatomy should be accurately determined. The location and length of the stricture is determined using radiography [13], urethroscopy, flexible cystoscopy [14] and ultrasonography [15]. The depth and density of the scar in the spongy tissue is more difficult to estimate but it could be measured by ultrasonography or magnetic resonance imaging. Morey and McAninch found that ultrasonography accurately defines the extent of spongiofibrosis in bulbar urethra [15]. It usually exceeds the appearance of the stricture length measured in the contrast studies. It is very beneficial for reconstructive urologists to attend the urethrography or doing it by themselves.

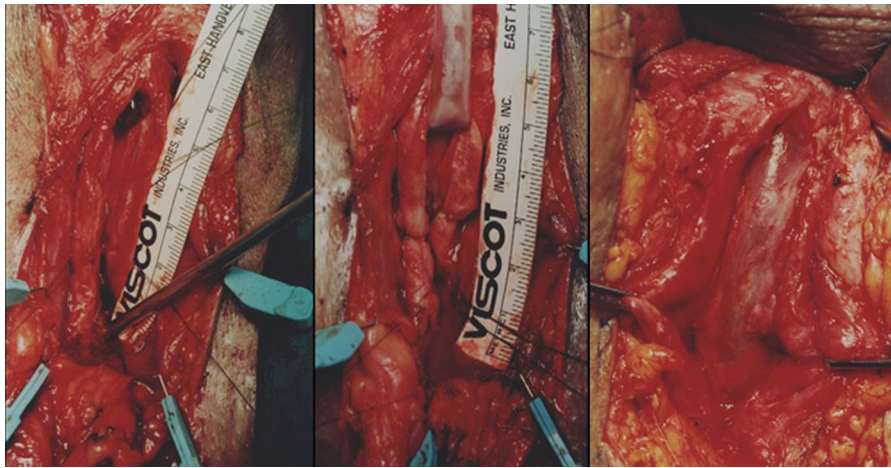
Even by the use of all of these tools, the final and most accurate evaluation of stricture will be available during surgery assisted by antegrade or retrograde endoscopy.

### Management of anterior urethral strictures

It has been said that there is no tissue better than the urethra to replace the urethra. This is true for short stricture in the bulbar urethra amenable for excision and primary anastomosis. But this is however not possible to achieve with longer strictures to avoid the risks of excessive mobilization and penile curvature. That's why urologists should be familiar with the use of many surgical techniques to deal with any condition of the urethra during surgery.

Among these techniques, penile grafts have been used to reconstruct the urethra in those strictures. To improve the survival and vascularity, the use of local flaps has also been advocated. Flaps however are technically demanding, and are not suitable in cases of Lichen Sclerosus.

In pursuit for the best graft material, bladder mucosa and buccal mucosal grafts have been used. The use of the latter has many advantages [4,16].



**Figure 1** Augmented Russell Technique showing closure of the roof using buccal mucosal graft after excision of strictured segment [18].

### Treatment options for anterior urethral strictures

Different treatment options are available for management of anterior urethral strictures depending on stricture site and length. This includes:

1. Excision with partial anastomosis: Heusner, Dugas, Hamilton Russell.
2. Excision with primary anastomosis: Heitz, Boyer, Marion.
3. Staged restoration.
4. Flap reconstruction.
5. Graft reconstruction (Skin, Bladder and Buccal)
6. Recently: tissue culture, acellular matrices.

### Augmentation and substitution urethroplasty

#### *Excision with partial anastomosis* *Heusner, Dugas, Hamilton Russell*

The use of excision techniques in the treatment of urethral strictures was summarized by Hamilton Russell in (1915). These techniques are not preferred by many surgeons because further stricture formation gave disappointing long-term results [17].

In 2007, El-Kassaby and colleagues present their 10-yr experience with one-stage repair of long bulbar urethral strictures using augmented dorsal strip anastomosis in >234 cases. Bulbar urethral strictures had a mean of 4.2 cm of which a mean of 2.8 cm diseased urethral segment was incised. Followed by excision of most of the fibrosed spongiosum, suturing of the roof (Russell) and grafting the floor with Buccal mucosal graft. The overall success rate exceeded 93% [18] (Fig. 1).

Ventral defect in “Augmented Russel Dorsal strip Anastomosis” could be covered using free graft of nonhirsute genital skin, buccal mucosa, bladder submucosa, or a bipediced penile skin flap (Fig. 2).

#### *Excision with primary anastomosis* *Heitz, Boyer and Marion*

Applied by Marion in (1912) and Heitz-Boyer in (1922), excision of the stenosed segment, end-to-end anastomosis, and suprapubic cystostomy improved the success with stricture surgery. In 1975,

Turner Warwick reported excellent results of an oblique end-to-end anastomosis in the bulbous urethra [17].

#### *Staged repair techniques*

Staged repair of long bulbar urethral strictures is one of the oldest forms of urethral reconstruction. Multistage reconstruction involves exposure of the urethra to the outside with or without excision and grafting. 3–12 months later, after the inflammation settles down and the graft becomes well taken, the defect is closed.

In 1911, Hamilton Russell used external urethrotomy for the relief of long recurrent urethral strictures especially anterior urethral strictures. He incised the urethra for the whole length of the stricture and then sutured the edges of the urethra to the adjacent skin, thus creating an artificial hypospadias [17].

An extension of the Hamilton Russell technique, the buried-skin technique was introduced by Denis Browne in (1949). Denis Browne established that a strip of penile skin would inevitably form a tube if left *in situ* and buried by closing the skin over it.

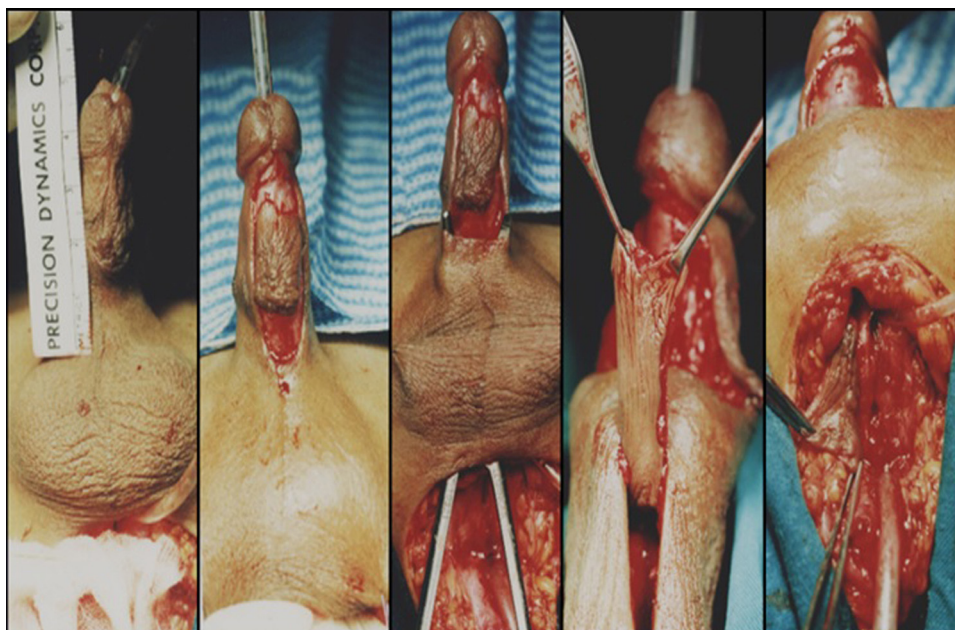
John Swinney (1952) excised the stricture and all scar tissue and then closed the raw area with adjacent skin. The second stage was a Theirsch-Duplay [17].

Recently, staged repair is limited to some specific indications. This includes strictures associated with chronic inflammation, previous recurrent infections or abscess, radiation, spinal cord injuries, fistulas, false passages, urethral diverticula, and failed prior repair [19].

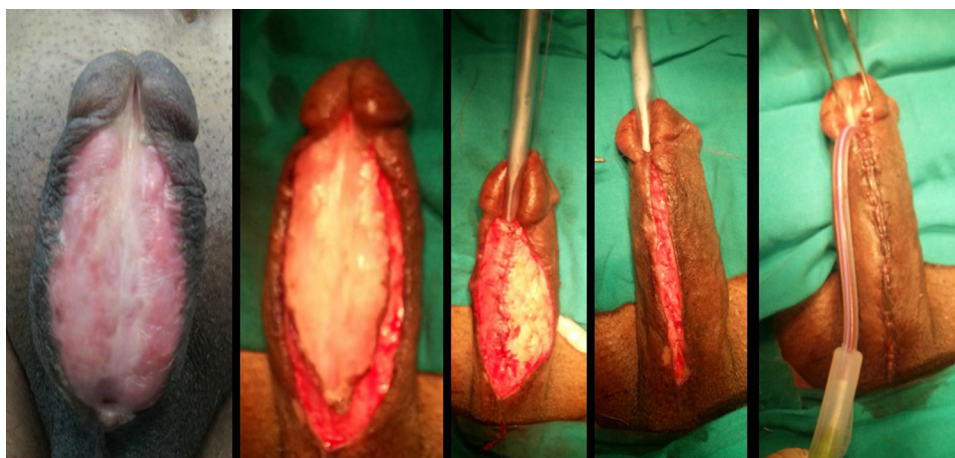Staged repair includes excision of unhealthy tissues followed by bridging of the defect by a graft and later tubularization [20] (Fig. 3). We use Full-thickness skin grafts (FTSG), Split-thickness skin grafts (STSG) or buccal grafts in these procedures.

#### *Flap reconstruction*

The first description of an island of skin with an axial blood supply used for urethral reconstruction was by Duckette in 1980 [21].



**Figure 2** “Augmented Russell Dorsal strip Anastomosis” showing augmentation of the ventral floor defect using ventral penile flap.



**Figure 3** Second stage repair of long urethral stricture following first stage buccal mucosal grafting.

Quarley (1983) described a similar technique using the flap to reconstruct the urethra following strictures anywhere from the external meatus to the prostatic urethra [22].

#### Graft reconstruction

##### Skin grafts

Since (1953) Presman and Greenfield, used preputial skin graft to manage a bulbar urethral stricture [23]. Later Devine and Horton popularized the technique using free full thickness hairless skin graft to reconstruct the urethra in a one-stage repair of hypospadias [24]. Extragenital full thickness skin has not been a popular graft tissue for urethral replacement due to suboptimal results [25].

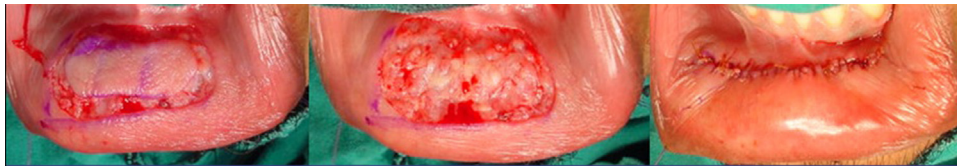Barbagli et al. (1996), following the concept advocated by Monseur, introduced the dorsally placed graft. It allows better mechanical support for the graft with an adequate vascular bed for the graft from the underlying corporeal bodies [26].

Two main types of skin grafts are available according to the thickness of graft taken; split-thickness and full thickness skin grafts. split-thickness graft (STG) includes the epidermis and the superficial dermal (intra-dermal) plexus. A full-thickness graft (FTG) includes the epidermis, the superficial dermis and the deep dermis. They are more durable and does not contract as STG. Extragenital full-thickness skin grafts carry increased mass, which generally makes them more fastidious than genital full-thickness grafts (*i.e.*, preputial and penile skin grafts) [27].

##### Bladder epithelial graft

Memmelaar (1947) was the first to report the use of bladder epithelium for urethral reconstruction [28].

Bladder epithelium has been an attractive material for construction of the neourethra in repeat repairs of hypospadias and other complex urethral anomalies. They tend to have more favorable vascular



**Figure 4** Lower lip buccal mucosal graft.

characteristics. It is accustomed to exposure to urine, resists shrinkage, and is readily available in adequate amounts [29].

There was a high incidence of meatal problems with the use of bladder epithelium as a urethral substitute. The exposed epithelium behaves similar to the exstrophy bladder epithelium, which hypertrophies, becomes sticky, and eventually metaplastic. It develops mucin-secreting glands, leading to prolapse and/or stenosis [30]. We avoided this in our ongoing series of panurethral stricture repair following Lichen sclerosis. Our technique includes the proximal use of bladder mucosa and the distal repair using buccal mucosal graft with nice results yet. Future studies should take in consideration that randomization is not possible because different techniques are not suitable for all cases.

#### *Buccal mucosal graft*

*Advantages of buccal mucosal grafts.* Various factors have contributed to the acknowledgement of buccal mucosal grafts (BMGs) as an ideal substitute for the urethra, including easy accessibility and manual handling, resistance to infection, compatibility with a wet environment, a thick epithelium and a thin lamina propria, and favorable graft host vascular relationship allowing early inosculation.

Buccal mucosal graft has a ‘pan laminar plexus’, which provides optimal vascular take [27].

The buccal mucosa patch graft is hairless and can tolerate trauma and infection adequately with high power of regeneration [4].

The oral mucosa also protects the host against invading pathogens through tough lamina propria that provides resistance to tear forces and protect against microorganisms. This protection from microorganisms is also due to cell shedding from the surface layer, therefore minimizing colonization. The oral mucosa contains a competent immune system keeping the oral mucosa in a healthy state despite the heavy microbial load usually found in the oral cavity [31,32].

Buccal mucosa differs from intestinal mucosa in that it does not have an adsorptive capacity, although differences in permeability exist in direct correlation to the thickness of the epithelial barrier [5,33].

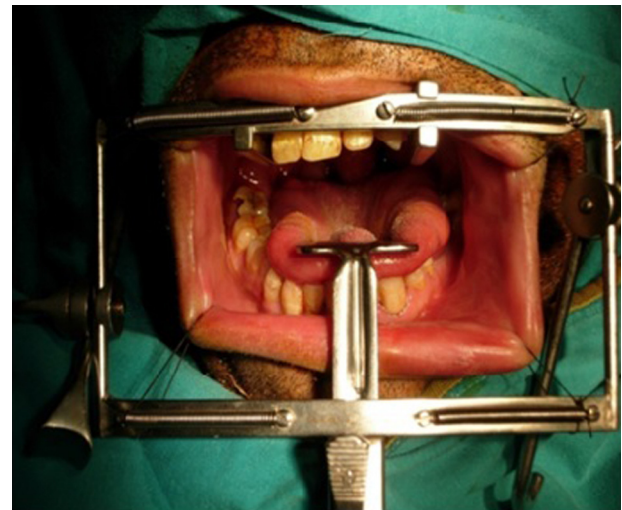
#### **Surgical technique**

1. Graft harvest
2. Position
3. Urethroplasty with Buccal Mucosal Graft (Exposure, Mobilization, Graft placement, Closure, Post-operative care).

#### *Harvesting of buccal mucosal graft*

##### *Donor site*

At the beginning of our experience, we started by harvesting a lower lip graft then shifted to cheek one or two sides (Fig. 4). Now Lip



**Figure 5** Dingman mouth gag with 3 blades for cheek buccal mucosal graft harvesting.

grafts are limited to long strictures, if needed, together with bilateral cheek graft. We rarely use lingual mucosa.

#### *Technique*

The technique of harvesting the graft has been variable; some authors prefer harvest of the graft before exposing the stricture to shorten the time in lithotomy position [34].

Our preference is the 2-team approach. This decreases the timing of the surgery but it needs proper decision making before the surgery.

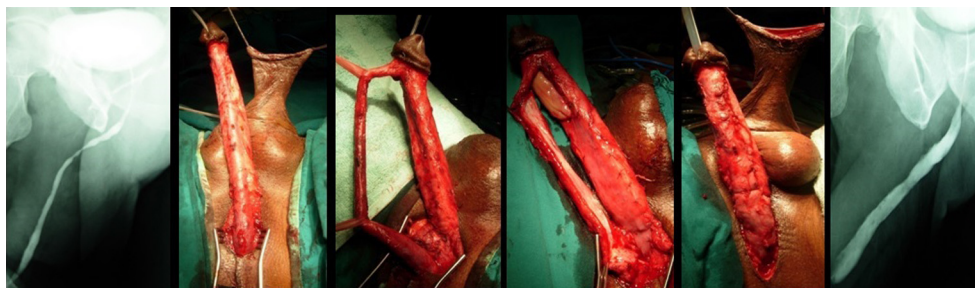
General anesthesia by nasal intubation is preferred. Followed by sterilization and draping of the oral cavity and the perineal field in the same time. Sterilization of the mouth using chlorhexidine and Betadine for the perioral area.

We also prefer using the Dingman mouth gag with 3 blades (Fig. 5). Other simpler mouth retractors are also available. This could be helped by some stay and/or everting sutures to the lips if needed.

Stensen duct is marked. Also the graft is marked on the cheek and/or the lower lip. A mixture of lidocaine and epinephrine could be injected along the lateral borders of the graft to stretch the graft and decrease bleeding.

The graft is separated from the underlying buccinator with care to avoid deeper dissection in the muscle where the branches of neurovascular plane lies.

The donor site is inspected for hemostasis using bipolar cautery and epinephrine soaked gauzes are left to stay for few minutes while the



**Figure 6** Complete Perineopenile Degloving.

graft is de-fattened. The graft is held for de-fattening as this helps the graft take at the recipient site.

The graft is handed to the urethral tray table, and the donor site is closed using continuous 3-0 vicryl. The epinephrine soaked cotton is left at the donor site which will be rechecked at the end of the surgery before discharge to recovery. Some surgeons prefer only hemostasis for the graft with some edge sutures without approximating the two opposing edges. This is preferred in wide grafts especially from the lips.

We use an antibiotic solution to soak the graft after harvest.

#### *Patient positioning*

In Ain Shams University, we access to the perineum through a low lithotomy position while some surgeons prefer the exaggerated lithotomy [35]. Compartment syndrome is more frequent in the low lithotomy position, this result from calf compression leading to decreased venous outflow and increased pressure within the leg compartments resulting in decreased arterial inflow and ischemic injury. So pressure on the calf muscles especially by the assistant surgeon should be avoided.

#### *Urethroplasty using buccal mucosal graft*

##### *Exposure*

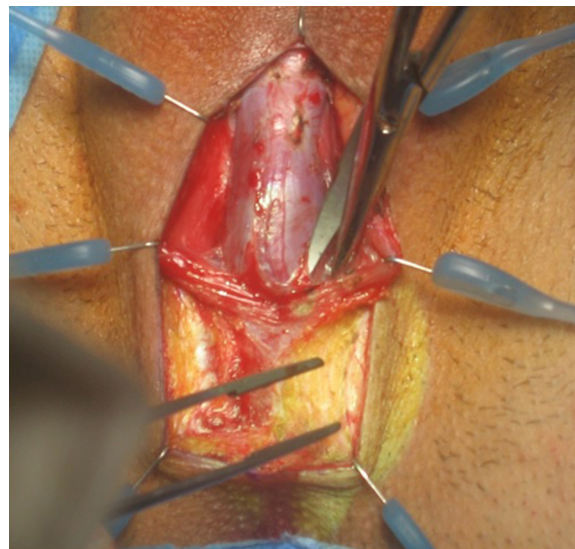
Short anterior urethral strictures could be managed through a penile degloving incision followed by urethral mobilization and penile skin graft.

For longer strictures, especially those due to lichen sclerosis or with deficient non-hirsute penile skin, buccal mucosa could be used with different incision approach:

**Perineal incision:** a lambda shaped incision is sharply outlined in the perineum (some surgeons prefer a longitudinal incision)

Kulkarni et al. described in 2000 a new, full length (penile and bulbar), one-stage oral mucosal graft urethroplasty in patients with panurethral strictures due to lichen sclerosis [36].

Our technique for management of such strictures includes perineal incision together with another subcoronal penile degloving incision. This allows full penile retrieval through the perineum in what we call “Complete Perineopenile Degloving” (Fig. 6). This technique offers easier repair of panurethral stricture down to the meatus.



**Figure 7** The urethra is exposed by retraction of the ischiocavernosus muscles.

##### *Mobilization*

Dissection is carried down to the midline fusion of the ischiocavernosus muscles, which is completely separated from the spongiosum (Fig. 7).

The corpus spongiosum is detached from its bond to the perineal body, and the proximal blood supply is divided. The dissection is carried proximally as far as the membranous urethra (Fig. 8).

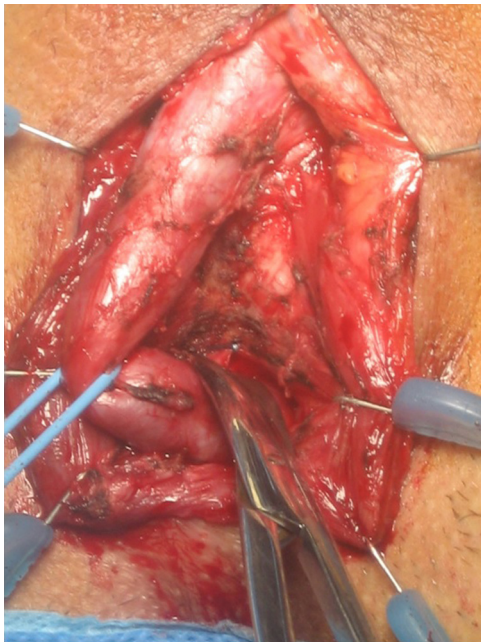
Distally the corpus spongiosum is detached from the triangular ligament to the mid scrotal level, and separated from the corpora cavernosa, with excision of parts of Buck’s fascia (Fig. 9).

In 2009, Barbagli modified his own technique [37]; combining the use of muscle and nerve sparing bulbar urethroplasty with the full length dorsal urethral opening from Kulkarni’s technique. This offers preservation of the lateral vascular supply to the urethra, the central tendon of the perineum, the bulbo-spongiosum muscle and its perineal innervations [38].

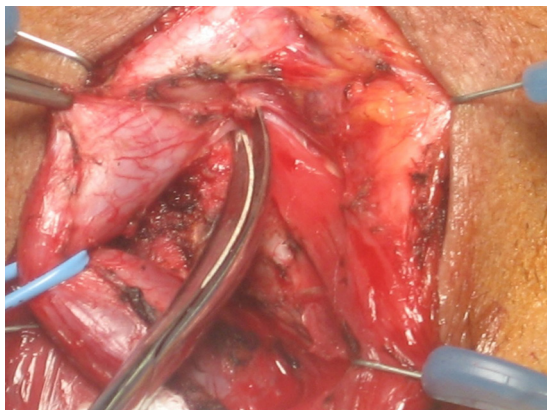
##### *Graft placement*

###### *Dorsal grafting*

The proximal end of the stricture is localized using cautious ante-grade passage of curved urethral metal dilator. This is very important especially in long strictures reaching the membranous or proximal



**Figure 8** The urethra mobilized from the corpora and from the perineal body.



**Figure 9** Distal dissection of the urethra.

bulbar area. Another method includes the use of antegrade flexible cystoscopy.

Localization of the distal segment is usually by large caliber neleton plastic catheter. This goal could be also achieved using retrograde urethroscopy. Also sterile methylene blue injection in the distal end will give better identification of the healthy mucosa especially in long strictures.

The limit of the stricture is marked on the urethra and using a sharp scalpel the urethra is opened dorsally. Urethral stricture is either incised dorsally if the stricture caliber is wide or it is excised. The edges are checked and débrided of any fibrous tissue, the urethra is then spatulated dorsally. The graft is then spread fixed to the triangular ligament and corpora cavernosa.

The graft is meshed using a sharp scalpel then the edge of the graft is sutured to the spatulated urethra. The floor of the urethra is reapproximated. This is done by holding the 2 lateral ends together by 3-0

PDS avoiding epithelium, then epithelium is closed by 6-0 Vicryl and the corpus spongiosum is sutured together by 4-0 PDS. Also some surgeons prefer suturing full thickness urethral wall instead of double layered suturing.

The lateral edges of the stricturotomy are then sutured to the graft using 4-0 Vicryl thus completing the onlay (Fig. 10).

#### *Ventral grafting*

The urethra is opened ventrally. The urethra is the spatulated ventrally.

The graft is then placed and meticulously sewn to the epithelium. With the graft in place the bulk of the corpus spongiosum is then sutured to the graft to begin the spongioplasty. This will add better graft revascularization and "Take". Finally the adventitia and the remaining bulk of the corpus spongiosum are sutured by PDS sutures.

#### *Ventral, dorsal or lateral grafts*

The dorsal onlay procedure for bulbar strictures got some advantages over traditional ventral onlay urethroplasty. Fixing the graft to the undersurface of the corporal bodies appears to provide both an excellent blood supply and good mechanical support, reducing shrinkage, chordee formation and ventral graft sacculation [26]. Lateral grafting also provides minimal unilateral dissection and should be taken in consideration in some cases. The three approaches; ventral, dorsal or lateral [39] graft positioning, has provided the same success rates and stricture recurrence rate [40].

#### *Urethral substitution with buccal graft*

In long strictures, if involving the penile urethra and causing penile curvature, the penile urethra should be excised and totally replaced by buccal mucosal graft as a first stage repair then retubularization of the graft in the second stage because tube replacement is not recommended anymore. This is a form of substitution urethroplasty.

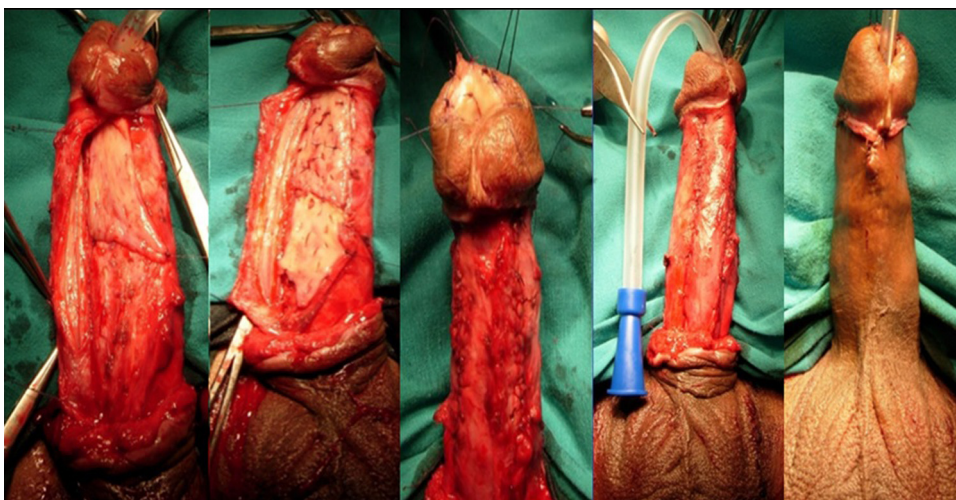
In case of "Multistage urethroplasty" of the penile urethra by buccal graft, care should be taken to facilitate reconstruction of the bed of the applied grafts by putting the penile dartos in the lateral parts of the applied grafts. So the graft should not be applied directly on the tunica albuginea of the penile corpora. This will facilitate the future tubularization of the taken grafts in the second stage from the lateral sides.

#### *Closure*

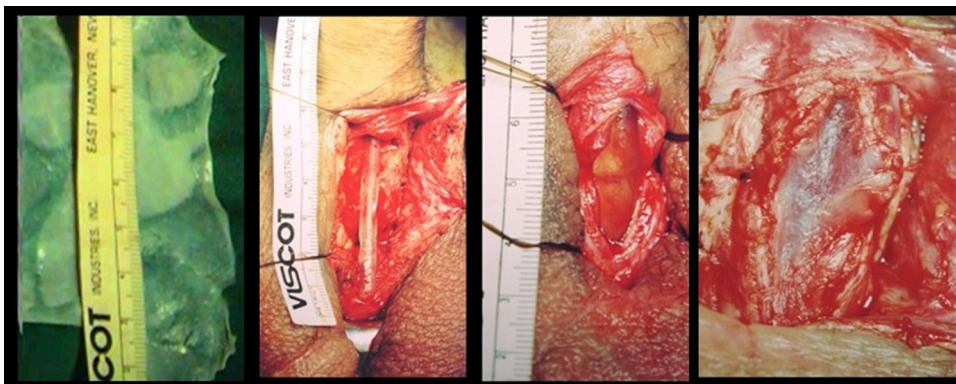
Foley silicon urethral catheter is passed before closing the anastomosis. It should be of smaller caliber than the neleton catheter used for repair. Hemostasis is reassured then closure of wound in layers leaving small caliber suction drain.

#### *Postoperative care*

1. Patient remains in bed rest for the first 48 h then allowed ambulating with assistance; activity is limited to walking and reclining in the bed with no prolonged sitting. The patient is advised to maintain mild activity till the catheters are removed in 4 weeks.



**Figure 10** Urethral dorsal grafting with buccal mucosal graft for long penile urethral stricture due to lichen sclerosis.



**Figure 11** The use of acellular collagen matrix grafting as an off the shelf engineered tissue in management of urethral strictures.

2. Diet is allowed as tolerated with no restrictions, stool softener is given for 10 days. Oral gel could be used and cold soft food till healing of oral graft bed.
3. Antibiotic covering gram negative organism is given IV for 48 h then the patient is started on suppressive therapy for 4 weeks.
4. Neurovascular checks for compartment syndrome, as well as DVT and atelectasis prophylaxis is taken into account.
5. In 4 weeks the patient returns for the voiding trial after removal of the urethral catheter. The suprapubic tube is plugged and removed in 2 days.
6. After voiding trial, they were followed up at 3 months with uroflowmetry, retrograde urethrogram (RGU).
7. Patients were further followed-up with uroflowmetry at 3 months interval and RGU every 6 months interval for the first 2 years. And later on if needed

#### *Recurrent strictures*

The ideal therapy for recurrent stricture after open urethroplasty has not been established. Repeat urethroplasty is frequently a complex and lengthy procedures.

Flaps are preferred for substitution urethroplasty because of the theoretical advantage that they carry their own blood supply leading

to better viability chances. Recently, there has been a trend toward grafts, particularly buccal mucosal free grafts.

Buccal mucosa could be used in primary and salvage urethroplasties, as dorsal onlay, ventral onlay, and as tubed grafts in urethral strictures. The buccal graft is an excellent and available source of material for urethral replacement in complex urethroplasties.

Multistage procedures may represent a better choice in repeated urethroplasties especially in the presence of severe fibrosis or recurrent near infections.

#### **The future of anterior urethral stricture surgery**

The future of anterior urethral substitutes seems to lie on Tissue Engineering. Acellular collagen matrix grafting as an off the shelf engineered tissue was introduced by Elkassaby et al. in 2003 [41]. This will obviate the need for tissue transfer in patients with long and complex strictures with no limitations as regards the quantity or quality of urethral substitutes available in any given patient (Fig. 11). Good primitive results are available but long term follow up together with cost control are still needed. Nowadays, it is unclear whether cell seeding could be an advantage in the nearby future.



**Conflict of interests**

None.

**Funding**

None.

**References**

- [1] Humby G. A one-stage operation for hypospadias repair. *Br J Surg* 1941;29:84–92.
- [2] Bürger RA, Müller SC, el-Damanhoury H, Tschakaloff A, Riedmiller H, Hohenfellner R. The buccal mucosal graft for urethral reconstruction: a preliminary report. *J Urol* 1992;147(3):662–4.
- [3] Duckett JW, Coplen D, Ewalt D, Baskin LS. Buccal mucosal urethral replacement. *J Urol* 1995;153(5):1660–3.
- [4] El-Kasaby AW, Fathalla M, Noweir AM, El-Halaby MR, Zakaria W, El-Beialy MH. The use of buccal mucosa patch graft in the management of anterior urethral strictures. *J Urol* 1993;149(2):276–8.
- [5] Nanci A. Ten cate's oral histology: development, structure and function. 7th ed. St. Louis, MO, USA: Mosby Elsevier; 2008. p. 411.
- [6] Bath-Balogh M, Fehrenbach MJ. Illustrated dental embryology, histology, and anatomy. Elsevier; 2011. p. 106. ISBN-13: 978-1437717303 ISBN-10: 1437717306.
- [7] Squier CA, Kremer MJ. Biology of oral mucosa and esophagus. *J Natl Cancer Inst* 2001;(29):7–15. Monographs.
- [8] Andrich DE, Mundy AR. Urethral strictures and their surgical treatment. *BJU Int* 2000; 86:571–580.580.
- [9] Fenton AS, Morey AF, Aviles R, Garcia CR. Anterior urethral strictures: etiology and characteristics. *Urology* 2005;65(June (6)):1055–8.
- [10] Jordan GH, Schlossberg SM. Surgery of the penis and urethra. In: Walsh PC, Retik AB, Vaughan Jr ED, editors. *Campbell's urology*, 4, 8th ed. Philadelphia: WB Saunders; 2002. p. 3886–952.
- [11] Venn S, Mundy A. Urethroplasty for balanitis xerotica obliterans. *BJU* 1998;81:735–7.
- [12] Stewart L, McCammon K, Metro M, Virasoro R. SIU/ICUD consultation on urethral strictures: anterior urethra-lichen sclerosus. *Urology* 2014;83(3 Suppl):S27–30.
- [13] McCallum RW, Devine CJ. Method of dynamic retrograde and voiding cystourethrography in urethral stricture. *AUA Update Ser* 1991;10. Lesson 12.
- [14] Jezior J, Jordan GH. Management of bulbous urethral stricture. *AUA Update Ser* 2003;22(1):2–7.
- [15] Morrey A, McAninch J. Sonographic staging of anterior urethral strictures. *J Urol* 2000;163:1070–5.
- [16] Barbagli G, Lazzeri M. Surgical treatment of anterior urethral stricture diseases: brief overview. *Int Braz J Urol* 2007;33(4). Rio de Janeiro.
- [17] Murphy LJT. The urethra, in the history of urology. Charles C Thomas: Springfield, IL; 1972. p. 453–82.
- [18] El-Kassaby AW, El-Zayat TM, El-Azzazy S, Osman T. One-stage repair of long bulbar urethral strictures using augmented Russell dorsal strip anastomosis: outcome of 234 cases. *Eur Urol* 2008;53:420–4.
- [19] Secrest CL. Staged urethroplasty: indications and techniques. *Urol Clin N Am* 2002;29:467–75.
- [20] Schreiter F, Noll F. Mesh graft urethroplasty using split thickness skin graft or foreskin. *J Urol* 1989;142:1223–6.
- [21] Duckette Jr JW. Transverse preputial island flap technique for repair of severe hypospadias. *Urol Clin N Am* 1980;7:423.
- [22] Quartey JKM. One Stage penile/preputial island flap urethroplasty for urethral stricture. *J Urol* 1985;134:474.
- [23] Presman D, Greenfield D. Reconstruction of the perineal urethra with a free full thickness skin graft from the prepuce. *J Urol* 1953;69:677–80.
- [24] Devine PC, Horton CE, Devine Sr CJ, Devine Jr CJ, Crawford HH, Adamson JE. Use of full thickness skin grafts in repair of urethral strictures. *J Urol* 1963;90:67–71.
- [25] Webster GD, Brown MW, Koefoot Jr RB, Sihelnick S. Suboptimal results in full thickness skin graft urethroplasty using an extrapenile skin donor site. *J Urol* 1984;131:1082–3.
- [26] Barbagli G, Selli C, di Cello V, Mottola A. A one stage dorsal free graft urethroplasty for bulbar urethral strictures. *Br J Urol* 1996;78:929–32.
- [27] Jordan GH. Principles of tissue transfer techniques in urethral reconstruction. *Urol Clin N Am* 2002;29:267–75.
- [28] Memmelaar J. Use of Bladder mucosa in a one stage repair of hypospadias. *J Urol* 1947;58:68.
- [29] Kinkead TM, Borzi PA, Duffy PG, Ransley PG. Long term follow up of bladder mucosa graft for male urethral reconstruction. *J Urol* 1994;151:1056–8.
- [30] Weingartner K, Kozakewich HP, Hendren WH. Nephrogenic adenoma after urethral reconstruction using bladder mucosa: report of 6 cases and review of the literature. *J Urol* 1997;(September):158.
- [31] Novak N, Haberstok J, Bieber T, Allam JP. The immune privilege of the oral mucosa. *Trends Mol Med* 2008;14:191–8.
- [32] Page RC, Schroeder HE. Pathogenesis of inflammatory periodontal disease. A summary of current work. *Lab Invest* 1976;34:235–49.
- [33] Lavelle CLB. *Applied oral physiology*. 2nd ed. Costa Mesa, CA, USA: Wright Publishing Company; 1988. p. 244.
- [34] Morey A, Mc Aninch JW. Technique of harvesting buccal mucosa for urethral reconstruction. *J Urol* 1996;155:1696–7.
- [35] Angermeier KW, Jordan GH. Complications of the exaggerated lithotomy position: A review of 177 cases. *J Urol* 1994;151:866–8.
- [36] Kulkarni SB, Kulkarni JS, Kirpekar DV. A new technique of urethroplasty for balanitis xerotica obliterans. *J Urol* 2000;163:352.
- [37] Barbagli G, Selli C, Tosto A, Palminteri E. Dorsal free graft urethroplasty. *J Urol* 1996;155:123.
- [38] Barbagli G, De Stefani S, Annino F, De Carne C, Bianchi G. Muscle and nerve sparing bulbar urethroplasty: a new technique. *Eur Urol* 2008;54:335.
- [39] Kulkarni S, Barbagli G, Sansalone S, Lazzeri M. One-sided anterior urethroplasty: a new dorsal onlay graft technique. *BJU Int* 2009;104(October (8)):1150–5.
- [40] Barbagli G, Palminteri E, Guazzoni G, Montorsi F, Turini D, Lazzeri M. Bulbar urethroplasty using buccal mucosa grafts placed on the ventral, dorsal or lateral surface of the urethra: are results affected by the surgical technique? *J Urol* 2005;174:955–7.
- [41] El-Kassaby AW, Retik AB, Yoo JJ, Atala A. Urethral stricture repair with an off the shelf collagen matrix. *J Urol* 2003;169(1):170–3.