



African Journal of Urology

Official journal of the Pan African Urological Surgeon's Association
web page of the journal

www.ees.elsevier.com/afju
www.sciencedirect.com



Review

Dorsal onlay graft bulbar urethroplasty using buccal mucosa



G. Barbagli^a, S. Balò^a, S. Sansalone^b, M. Lazzeri^{c,*}

^a *Centro Chirurgico Toscano, Arezzo, Italy*

^b *Department of Experimental Medicine and Surgery, University of Tor Vergata, Rome, Italy*

^c *Department of Urology, Istituto Clinico Humanitas IRCCS, Clinical and Research Hospital, Rozzano, Italy*

Received 28 September 2015; received in revised form 29 September 2015; accepted 30 September 2015

Available online 2 December 2015

KEYWORDS

Buccal mucosa;
Bulbar urethra;
Surgical technique;
One-stage urethroplasty

Abstract

In 1996, Barbagli described the use of the free graft from Devine's technique with the dorsal urethral opening from Monseur's technique. Such technique was termed new dorsal onlay graft urethroplasty or Barbagli's procedure. It can be used for penile urethral stricture repair and different types of dorsal onlay graft urethroplasty for bulbar urethral stricture repair. The current paper describes, step by step, Barbagli technique of dorsal onlay graft bulbar urethroplasty using buccal mucosa. The preoperative patient evaluation and postoperative course and follow-up are finally showed.

© 2015 Pan African Urological Surgeons' Association. Production and hosting by Elsevier B.V. All rights reserved.

Introduction

In 1953, Presman and Greenfield first described the use of preputial skin as free graft in the treatment of bulbar urethral strictures [1]. In 1963, Devine et al., after having successfully used a full thickness skin graft in a one-stage reconstruction of hypospadias, extended its use to bulbar urethral stricture repair in a preliminary series of 6 patients [2]. In 1979, Devine et al. widely popularized the use of free skin grafts in the reconstructive urethral surgery [3,4]. In

1980, the French urologist Monseur reported the results of 219 urethral strictures (197 cases from Zaire and 22 cases from Normandy) treated using a new urethroplasty described by the same author in 1968 [5,6]. The urethra is longitudinally opened along its dorsal surface and fixed over the albuginea of corpora cavernosa, so as to promote the transformation of the urethral mucosa plate into a tube, according to the Duplay's and Denis Browne's "buried skin strip principle" [6–8].

In 1996, we combined the use of the free graft from Devine's technique with the dorsal urethral opening from Monseur's technique, and first described a one new dorsal onlay graft urethroplasty for penile urethral stricture repair and different types of dorsal onlay graft urethroplasty for bulbar urethral stricture repair [9,10]. In our

* Corresponding author.

E-mail address: massimo.lazzeri@humanitas.it (M. Lazzeri).

Peer review under responsibility of Pan African Urological Surgeons' Association.

techniques, the free graft (skin or buccal mucosa) is sutured over the albuginea of the corpora cavernosa and the urethra, fully opened along its dorsal surface, is rotated to cover the graft which serves as an epithelial buried roof-strip facilitating the regeneration of urethral mucosa thus considerably reducing the time for urethral regeneration. According to experimental and clinical studies by Weaver and Schulte and Moore, the dorsal buried epithelial strip facilitates urethral regeneration without the formation of the scar tissue [11–13]. Over time, our original technique (also named “Barbagli’s procedure”) was better defined and many changes were suggested by various authors [14–17].

We here describe, step by step, our current technique of dorsal onlay graft bulbar urethroplasty using buccal mucosa including the preoperative patient evaluation and postoperative course and follow-up. The aim of this study is to make these safe techniques easily reproducible in the hands of any surgeon.

Subjects and methods

Pre-operative evaluation of patient

Pre-operative evaluation includes clinical history, physical examination, urine culture, residual urine measurement, uroflowmetry, retrograde and voiding cystourethrography, and urethral ultrasound. Ideal candidates for this type of urethroplasty are those presenting long (ranging from 3 to 8 cm) bulbar strictures in the distal part of the bulbar urethra, also involving the proximal part of the penile tract. The stricture etiology and length do not influence the choice of the surgical technique. In more proximal bulbar strictures we prefer a ventral onlay urethroplasty according to our technique and results [18]. In obese patients with fat perineum the dorsal approach to the urethra may presents some difficulties. This technique may also be used in patients with previously failed bulbar urethroplasty or repeated urethrotomy. With some modifications, this technique may be used also for panurethral stricture repair. Patient age it is not a factor which influenced the success rate, and this technique should not be withheld from patients on the basis of age.

Preparation of patient for surgery

Three days prior to surgery, the patient should begin using chlorhexidine bidet for genitalia cleansing twice a day. The day before surgery the patient receives intravenous prophylactic antibiotics.

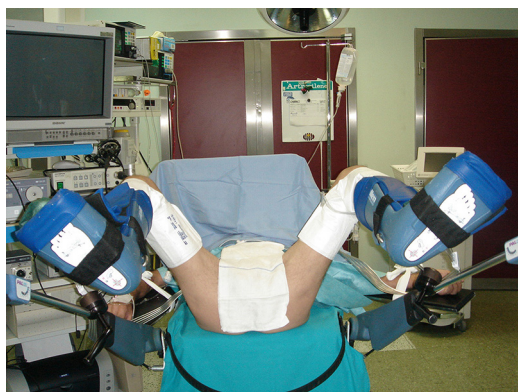

Figure 1 The patient is placed in the simple lithotomy position with Allen stirrups and sequential inflatable compression sleeves.

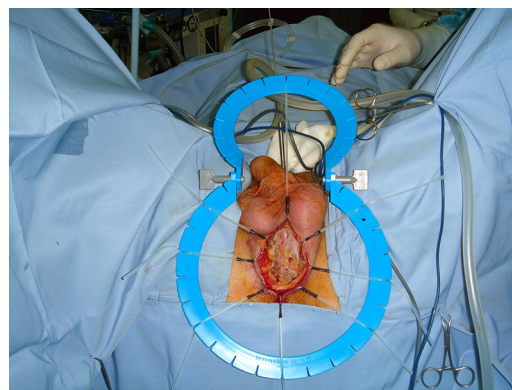


Figure 2 The plastic ring retractor with plastic hooks in place.

Instruments for dorsal onlay graft bulbar urethroplasty using buccal mucosa

The following instruments are suggested:

- Allen stirrups (Fig. 1).
- Sequential inflatable compression sleeves (Fig. 1).
- Kilner-Doughty mouth retractor.
- Plastic ring retractor with plastic hooks (Fig. 2).
- Nasal speculum with modified tip (Fig. 3).
- Bipolar electrocautery.
- 5-zero polyglactin sutures (or similar).

Preparation of patient for surgery

The patient is placed in the simple lithotomy position (Fig. 1). The patient’s calves are placed in Allen stirrups with sequential inflatable compression sleeves and the lower extremities are then suspended by placement of the patient’s feet within the stirrup boots (Fig. 1). Proper positioning ensures that there is no pressure on any aspect of the calf muscles and no inward boot rotation, so as to avoid peroneal nerve injury. The suprapubic area, scrotum and perineum are shaved and draped appropriately. The patient is draped in two separated parts so that two surgical teams can work simultaneously. Each team has its own set of surgical instruments. One team harvests and prepares the oral graft, while the second team exposes the urethra. Pre-operative urethroscopy is performed using a 7F rigid ureteroscope to evaluate the stricture and to insert a sensor 3F guide wire into the urethra until reaching the bladder (Fig. 4A and B).




Figure 3 Nasal speculum with modified tip.

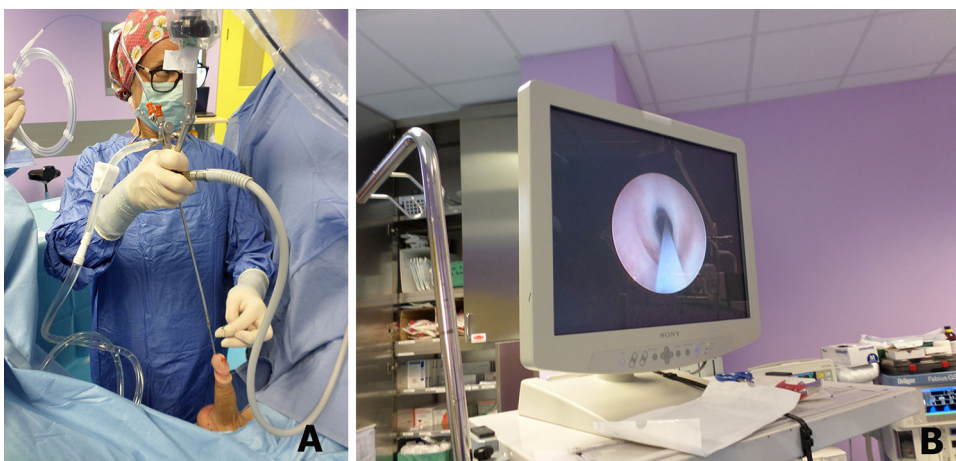


Figure 4 (A) Urethroscopy is performed using a 7F rigid ureteroscope. (B) A sensor 3F guide wire is inserted through the stricture until reaching the bladder.

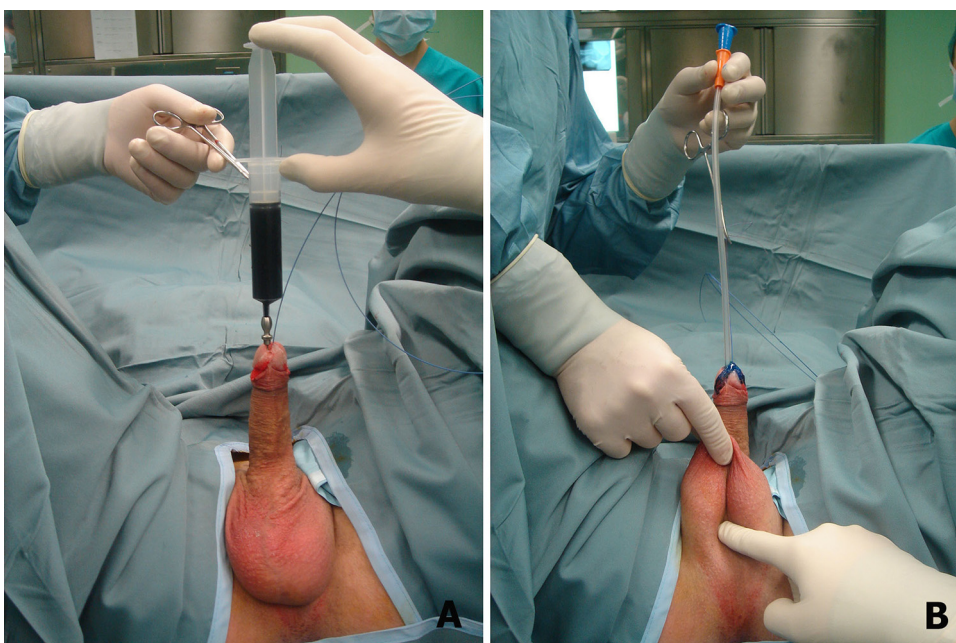


Figure 5 (A) Methylene blue is injected into the urethra. (B) The distal part of stenosis is identified and marked inserting a 16F Nelaton catheter.

Methylene blue is injected into the urethra to better define the diseased urethral mucosa (Fig. 5A). The distal part of stenosis is identified and marked inserting a 16F Nelaton catheter with a round tip up to the point of resistance (Fig. 5B).

Surgical technique

Dorsal onlay graft bulbar urethroplasty using buccal mucosa

A midline perineal incision is made and the ring retractor with plastic hooks is put in place (Fig. 2).

The bulbar urethra is dissected from the corpora cavernosa along the left side, starting from the distal tract where muscles are absent, leaving the bulbo-spongiosum muscle and the central tendon of the perineum intact. The urethra is completely dissected from the corpora cavernosa for a long tract (Fig. 6A). The urethra is rotated

180°, the dorsal urethral surface is exposed and fully opened and the urethral stricture is evaluated (Fig. 6B). The stricture is then opened for its entire length by extending the urethrotomy distally and proximally (Fig. 6B). The proximal urethral opening is evaluated by inserting the nasal speculum (Fig. 6C). Once the entire stricture has been incised, the length and width of the remaining urethral plate is measured. Two milliliters of glue are injected over the corpora cavernosa (Fig. 7A). The oral mucosal graft is spread and fixed over the glue bed, the apices of the graft are sutured to the proximal and distal apices of the urethrotomy, and the margin of the oral graft is sutured to the margin of the urethral mucosal plate (Fig. 7B). A Foley 16F grooved silicone catheter is inserted (Fig. 7C). The bulbar urethra, with the intact bulbo-spongiosum muscle, is rotated to its original position over the graft (Fig. 8AB). Interrupted 5-0 polyglactin sutures are used to stabilize the urethral margins onto the corpora cavernosa over the graft on the left side. At the end of the procedure, the graft is completely covered by the

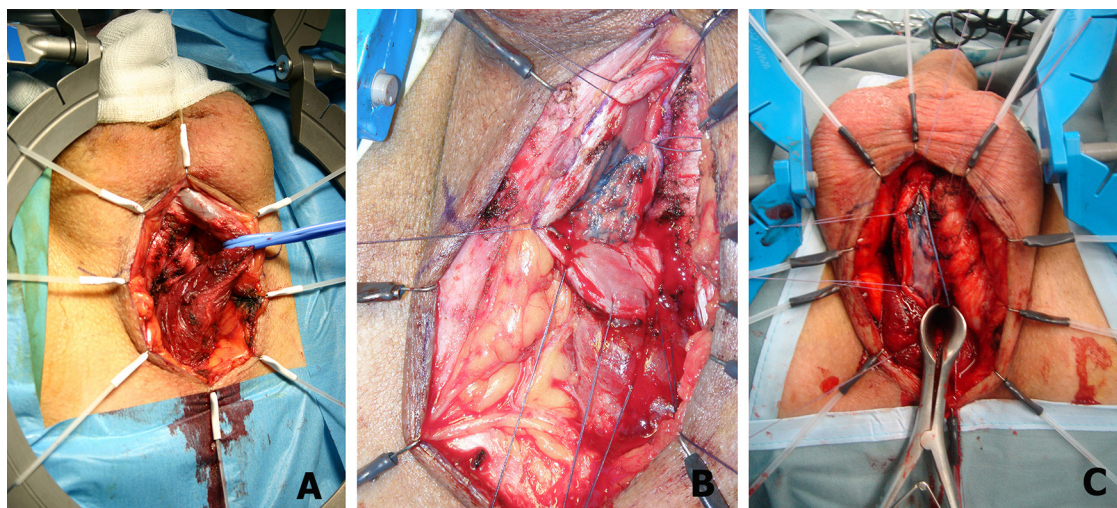


Figure 6 (A) The urethra is dissected from the corpora cavernosa. (B) The urethra is rotated 180° and the stricture is opened for its entire length. (C) The proximal urethral opening is evaluated by inserting the nasal speculum.

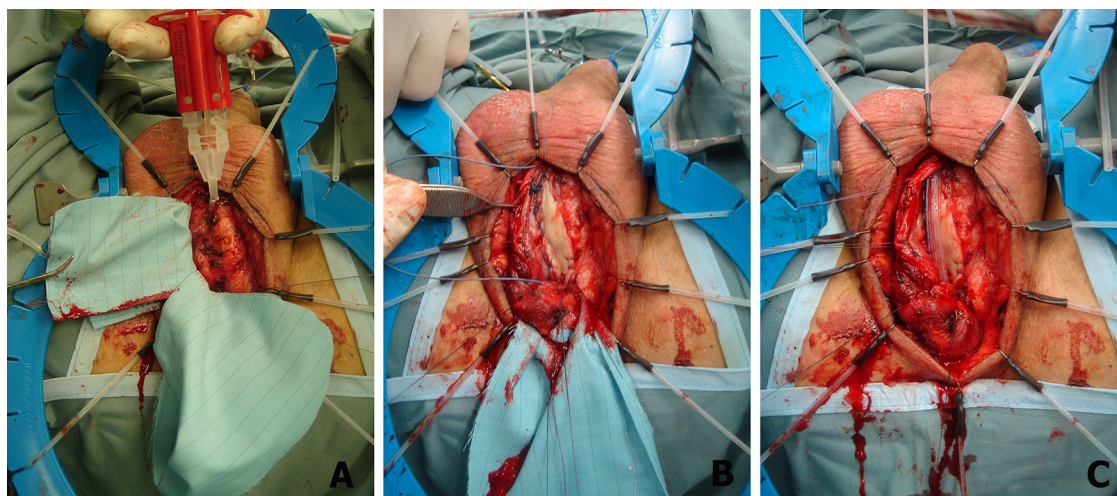


Figure 7 (A) Two milliliters of glue are injected over the corpora cavernosa. (B) The oral mucosal graft is fixed over glue bed, and sutured to the margins of the urethral mucosal plate. (C) A Foley 16F grooved silicone catheter is inserted.

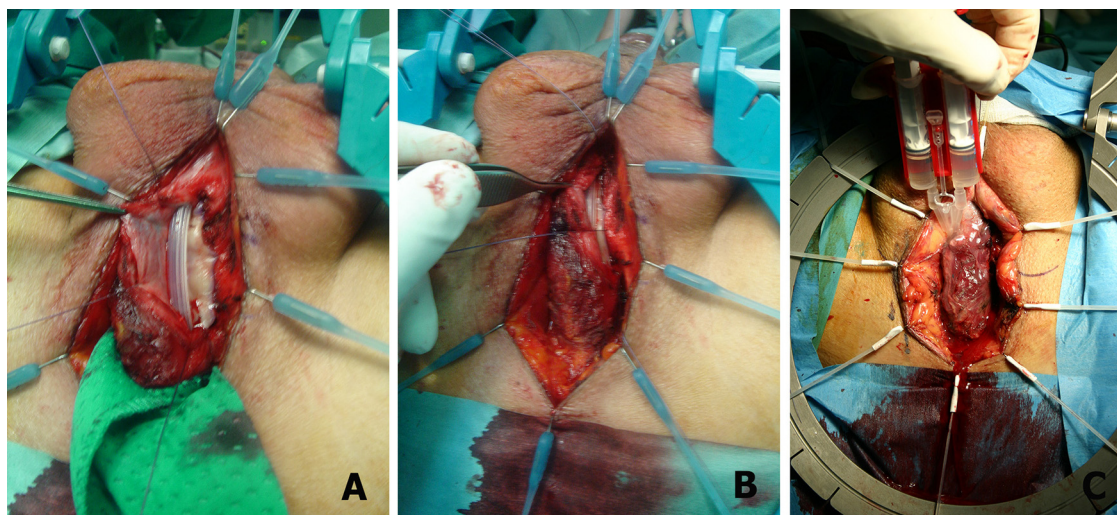


Figure 8 (A and B) The bulbar urethra, with the intact bulbo-spongiosum muscle, is rotated to its original position over the graft. (C) Two milliliters of glue are injected over the suture line.

urethra, then by the muscles, and 2 ml of glue are injected over the suture line (Fig. 8C). The perineal fat and the skin are closed with interrupted absorbable sutures. A drain is necessary only for long grafting procedure. The catheter is left in place for 4 weeks.

Postoperative course and follow-up

An ice bag is applied to the check to avoid pain and hematoma. A clear liquid diet and ice cream is given initially, and then advanced to a soft and regular diet. The patient ambulates on the first post-operative day and is discharged from the hospital three days after surgery. All patients receive postoperative broad-spectrum antibiotics and are maintained on oral antibiotics until the catheter is removed. At 4 weeks after surgery, the bladder is filled with contrast medium, the Foley catheter is removed and voiding cystourethrography is obtained. Clinical outcome is considered a failure when any postoperative instrumentation was needed, including dilation. Uroflowmetry and urine culture are repeated every 4 months in the first year and annually thereafter. When symptoms of decreased force of stream are present and uroflowmetry is less than 14 ml per second, the urethrography, urethral ultrasound and urethroscopy are repeated.

Discussion

Over time, our original technique of dorsal onlay graft bulbar urethroplasty has been greatly improved and new changes are continuously being suggested, including the using of glue, a muscle and nerve sparing approach, and a minimally invasive technique [19–21].

At the beginning of our learning curve, the penile skin was the preferred material for any type of substitution urethroplasty. But, it is interesting to evaluate the success rate of penile skin in bulbar urethral reconstruction over time. In 1998, the success rate of the dorsal onlay graft urethroplasty using penile skin as a substitute material, with a mean followup of 21.5 months, was 92% [22]. In 2001, the success rate, with a mean followup of 43 months, decreased from 92% to 85% [23]. In 2004, the success rate, with a mean followup of 71 months, again decreased from 85% to 73% [24]. In 2008, the success rate, with a mean followup of 111 months, again decreased more from 73% to 65.8% [25]. Finally, in 2014, the success rate, with a mean followup of 190 months, was 63.6% [26]. In 16 years, the success rate of dorsal onlay graft bulbar urethroplasty using penile skin as a substitute material decreased from 92% to 63.6% [22–26]. It is now interesting to evaluate the trend of buccal mucosa when used in the same technique. In 1998, the buccal mucosa, preliminarily used in only 6 patients, showed a 100% success rate at 13.5 month mean followup [22]. In 2005, the success rate on 23 cases with a 42 months mean followup, was 85% [27]. In 2014, the success rate on 81 cases with a 111 month mean followup, was 80.2% [26]. In 16 years, the success rate of dorsal onlay graft bulbar urethroplasty using buccal mucosa as a substitute material decreased from 100% to 80.2% [22,26,27]. It is evident that buccal mucosa is superior to the penile skin in dorsal onlay graft bulbar urethroplasty.

In the literature, the question is still open as to whether it is better to use the ventral or dorsal placement of the graft in one-stage bulbar urethroplasty [15,17]. In 2005, using buccal mucosa grafts placed on the ventral, dorsal or lateral surface of the urethra, we investigated if the results were affected by the surgical technique [27]. The results

of our study showed that the placement of buccal mucosa grafts on the ventral, dorsal or lateral surface of the urethra showed the same success rates (83–85%), the outcome was not affected by the surgical technique and the stricture recurrences were uniformly distributed in all patients [27]. In conclusion, the choice should be based only on the surgeon preference and background [17].

The dorsal onlay graft urethroplasty using buccal mucosa represents a valid option in the treatment of long non-obliterative strictures located in the bulbar urethra. The use of glue and the sparing approach may render this technique easier to be performed. This technique should also be suggested for the repair of panurethral strictures located in the bulbar urethra, also extending into the penile tract.

Conclusions

The technique we describe here is simple, reliable, and reproducible in the hands of any surgeon to repair atraumatic distal bulbar urethral strictures of 3–7 cm or more. The use of atraumatic, appropriate surgical instruments and suture material, and the careful and meticulous haemostasis are fundamental steps to avoid post-operative complications and sequelae.

Conflict of interest

None of the contributing authors has any conflict of interest, including specific financial interests or relationships and affiliations relevant to the subject matter or materials discussed in the manuscript.

References

- [1] Presman D, Greenfield DL. Reconstruction of the perineal urethra with a free full-thickness skin graft from the prepuce. *J Urol* 1953;69:677–80.
- [2] Devine PC, Horton CE, Devine Sr CJ, Devine Jr CJ, Crawford HH, Adamson JE. Use of full thickness skin grafts in repair urethral strictures. *J Urol* 1963;90:67–71.
- [3] Devine PC, Wendelken JR, Devine Jr CJ. Free full thickness skin graft urethroplasty. *J Urol* 1976;116:444–6.
- [4] Devine PC, Wendelken JR, Devine Jr CJ. Free full thickness skin graft urethroplasty: current technique. *J Urol* 1979;121:282–5.
- [5] Monseur J. La reconstitution du canal de l'urètre au moyen des lames sus-urétrales et de l'gouttière sous-caverneuse. *J Urol Néphrol* 1968;74:755–68.
- [6] Monseur J. L'élargissement de l'urètre au moyen du plan sus urétral. *J Urol* 1980;86:439–49.
- [7] Duplay S. Sur le traitement chirurgical de l'hypospadias et de l'epispadias. *Arch Gen Méd* 1880;145:257–74.
- [8] Browne D. An operation for hypospadias. *Proc R Soc Med* 1949;42:466–8 [*J Urol* 1980;86:439–49].
- [9] Barbagli G, Selli C, Tosto A, Palminteri E. Dorsal free graft urethroplasty. *J Urol* 1996;155:123–6.
- [10] Barbagli G, Selli C, di Cello V, Mottola A. A one-stage dorsal free-graft urethroplasty for bulbar urethral strictures. *Br J Urol* 1996;78:929–32.
- [11] Weaver RG, Schulte JW. Experimental and clinical studies of urethral regeneration. *Surg Gynecol Obstet* 1962;115:729–36.
- [12] Weaver RG, Schulte JW. Clinical aspects of urethral regeneration. *J Urol* 1965;93:247–54.
- [13] Moore CA. One-stage repair of stricture of bulbous urethra. *J Urol* 1963;90:203–7.
- [14] Iselin CE, Webster GD. Dorsal onlay urethroplasty for urethral stricture repair. *World J Urol* 1998;16:181–5.

- [15] Andrich DE, Leach CJ, Mundy AR. The Barbagli procedure gives the best results for patch urethroplasty of the bulbar urethra. *BJU Int* 2001;88:385–9.
- [16] Guralnick ML, Webster GD. The augmented anastomotic urethroplasty: indications and outcome in 29 patients. *J Urol* 2001;165:1496–501.
- [17] Granieri MA, Webster GD, Peterson AC. The evolution of urethroplasty for bulbar stricture disease: lesson learned from a single centre experience. *J Urol* 2014;192:1468–72.
- [18] Barbagli G, Montorsi F, Guazzoni G, Larcher A, Fossati N, Sansalone S, et al. Ventral oral mucosal onlay graft urethroplasty in nontraumatic bulbar urethral strictures: surgical technique and multivariable analysis of results in 214 patients. *Eur Urol* 2013;64:440–7.
- [19] Barbagli G, De Stefani S, Sighinolfi MC, Annino F, Micali S, Bianchi G. Bulbar urethroplasty with dorsal onlay buccal mucosal graft and fibrin glue. *Eur Urol* 2006;50:467–74.
- [20] Barbagli G, De Stefani S, Annino F, De Carne C, Bianchi G. Muscle- and nerve sparing bulbar urethroplasty: a new technique. *Eur Urol* 2008;54:335–43.
- [21] Kulkarni S, Barbagli G, Sansalone S, Lazzeri M. One-sided anterior urethroplasty: a new dorsal onlay graft technique. *BJU Int* 2009;104:1150–5.
- [22] Barbagli G, Palminteri E, Rizzo M. Dorsal onlay graft urethroplasty using penile skin or buccal mucosa in adult bulbourethral strictures. *J Urol* 1998;160:1307–9.
- [23] Barbagli G, Palminteri E, Lazzeri M, Guazzoni G, Turini D. Long-term outcome of urethroplasty after failed urethrotomy versus primary repair. *J Urol* 2001;165:1918–9.
- [24] Barbagli G, Palminteri E, Lazzeri M, Turini D. Interim outcome of dorsal skin graft bulbar urethroplasty. *J Urol* 2004;172:1365–71.
- [25] Barbagli G, Morgia G, Lazzeri M. Dorsal onlay skin graft bulbar urethroplasty: long-term follow-up. *Eur Urol* 2008;53:628–34.
- [26] Barbagli G, Kulkarni SB, Fossati N, Larcher A, Sansalone S, Guazzoni G, et al. Long-term followup and deterioration rate of anterior substitution urethroplasty. *J Urol* 2014;192:808–13.
- [27] Barbagli G, Palminteri E, Guazzoni G, Montorsi F, Turini D, Lazzeri M. Bulbar urethroplasty using buccal mucosa grafts placed on the ventral, dorsal or lateral surface of the urethra: are results affected by the surgical technique. *J Urol* 2005;174:955–8.