



African Journal of Urology

Official journal of the Pan African Urological Surgeons' Association
web page of the journal

www.ees.elsevier.com/afju
www.sciencedirect.com



Review

One-stage and two-stage penile buccal mucosa urethroplasty



G. Barbagli^a, S. Balò^a, S. Sansalone^b, M. Lazzeri^{c,*}

^a *Centro Chirurgico Toscano, Arezzo, Italy*

^b *Department of Experimental Medicine and Surgery, University of Tor Vergata, Rome, Italy*

^c *Department of Urology, Istituto Clinico Humanitas IRCCS, Clinical and Research Hospital, Rozzano, Italy*

Received 28 September 2015; accepted 28 September 2015

Available online 2 December 2015

KEYWORDS

Buccal mucosa;
Penile urethra;
Surgical technique;
One-stage urethroplasty;
Two-stage urethroplasty

Abstract

The paper provides the reader with the detailed description of current techniques of one-stage and two-stage penile buccal mucosa urethroplasty. The paper provides the reader with the preoperative patient evaluation paying attention to the use of diagnostic tools. The one-stage penile urethroplasty using buccal mucosa graft with the application of glue is preliminary showed and discussed. Two-stage penile urethroplasty is then reported. A detailed description of first-stage urethroplasty according Johanson technique is reported. A second-stage urethroplasty using buccal mucosa graft and glue is presented. Finally postoperative course and follow-up are addressed.

© 2015 Pan African Urological Surgeons' Association. Production and hosting by Elsevier B.V. All rights reserved.

Introduction

The surgical repair technique for a penile urethral stricture is mainly related to the stricture etiology. A great difference in penile stricture etiology exists between developed and developing countries.

In developed countries, lichen sclerosus (LS) and failed hypospadias repair (FHR) are now reported as the main causes of penile

urethral strictures and there has been a decrease in post-infectious strictures and an increase of instrumentation and catheter related strictures [1–3]. On the contrary, in developing countries recurrent gonococcal urethritis remains an important cause of strictures, but there also seems to be a trend of decreasing urethritis and an increase of instrumentation and catheter related strictures in these countries as well [4–6].

The repair of penile urethral strictures may require one- or two-stage urethroplasty [7–10]. Certainly, sexual function can be placed at risk by any surgery on the penile urethra and the dissection must avoid interference with the neurovascular supply to the penis and the use of flaps or grafts should not compromise penile length, should not cause penile chordee and should not affect penile appearance.

* Corresponding author.

E-mail address: massimo.lazzeri@humanitas.it (M. Lazzeri).

Peer review under responsibility of Pan African Urological Surgeons' Association.

Whenever possible, the repair of penile strictures should be done using a one-stage procedure, saving the patient the discomfort of the two-stage procedure which entails an abnormal site of the external urinary meatus and noticeable changes in esthetic penile appearance. Unfortunately, in some patients the use of a two-stage procedure is mandatory because the meatus and navicularis urethra are almost completely obliterated with marked wood-hard fibrosis extending into the proximal part [9]. Also, the majority of patients with FHR presenting with obliterative strictures associated with fistulae, scarring, chordee, abnormal meatus, small glans and deficiency of the dartos layer may require a two-stage procedure [9].

As far as penile urethral reconstruction there are two main questions still open in the literature: in one-stage repair it is better to use a flap or a graft? And, in two-stage repair, when and how should a buccal mucosa graft be used?

We describe here, step by step, our current techniques of one-stage and two-stage penile buccal mucosa urethroplasty including the preoperative patient evaluation and postoperative course and follow-up. The aim of this study is to make these safe techniques easily reproducible in the hands of any surgeon.

Subjects and methods

Pre-operative evaluation of patient

The clinical history of the patient and etiology of the penile stricture should be fully evaluated. Patients with histological proven LS presenting obliterative meatal, navicularis and distal penile strictures may require complete excision of the diseased urethral segment which should be replaced with buccal mucosa in a 2-stage repair (Fig. 1A–C) [7–10]. In patients with LS, the use of buccal mucosa at the first stage is mandatory because LS does not affect the oral

mucosa [7–10]. Patients with a history of FHR presenting obliterative strictures associated with fistulae, scarred penile skin, chordee, abnormal meatus, small glans and deficiency of the dartos layer may require a two-stage repair, using the buccal mucosa only in the second stage. The majority of patients presenting penile strictures not related to LS or FHR are good candidates for one-stage urethroplasty using a graft or flap. Before planning the surgical approach it is mandatory to perform a retrograde and voiding urethrography and to perform a calibration of the external urinary meatus by the progressive insertion of 10, 12, 14, 16 F Nelaton catheters. It is very important to establish before the surgery if the stricture involves the meatus and the navicularis tract.

Preparation of patient for surgery

Three days prior to surgery, the patient should begin using chlorhexidine bidet for genitalia cleansing twice a day. The day before surgery the patient receives intravenous prophylactic antibiotics.

Surgical techniques

One-stage penile urethroplasty using buccal mucosa graft and glue

The patient is intubated through the nose, allowing the mouth to be completely free. The patient is operated by 2 surgical teams working simultaneously, each having its own set of surgical instruments. The oral mucosa graft is harvested from the cheek according to our standard technique used with more than 553 patients [11]. The graft is tailored according to the site, length and characteristics of the stricture. The patient is placed in a simple supine position. A suture is placed in the glans to stretch the penis. In strictures involving the external urinary meatus and extending into the distal part of the penis, the penile urethra is approached by circular sub-coronal incision and penile degloving. In more proximal

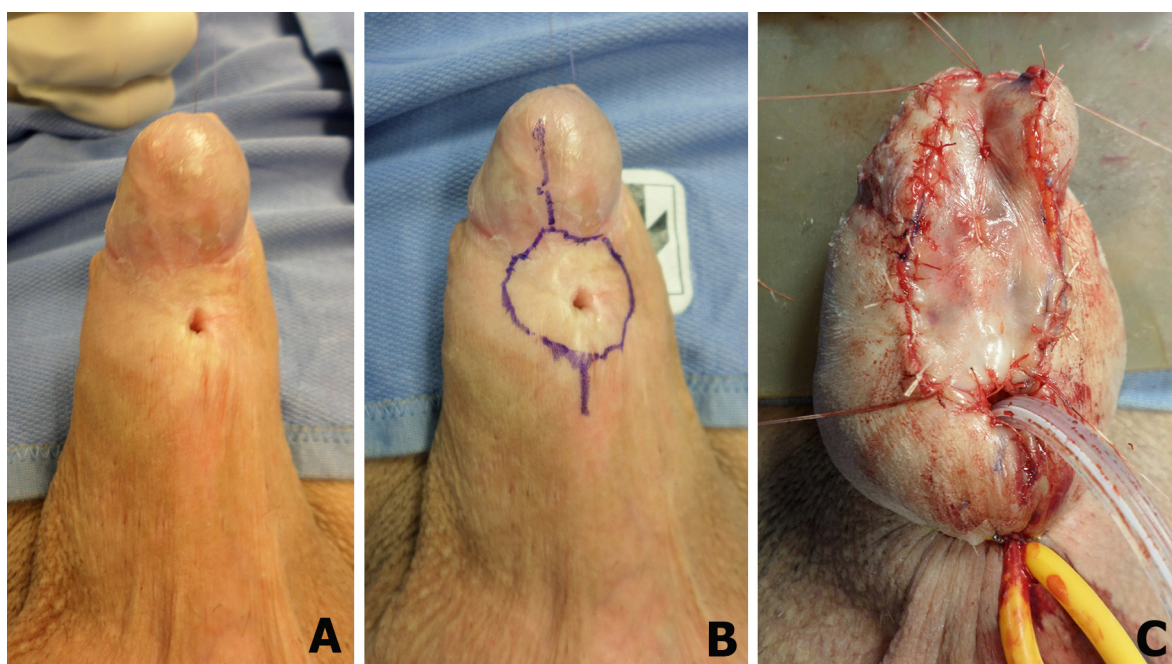


Figure 1 (A) Patient with lichen sclerosus recurrent after repeated meatotomy. (B) Margins of tissue to be removed. (C) Appearance of the penis after the first stage of buccal mucosa graft urethroplasty.

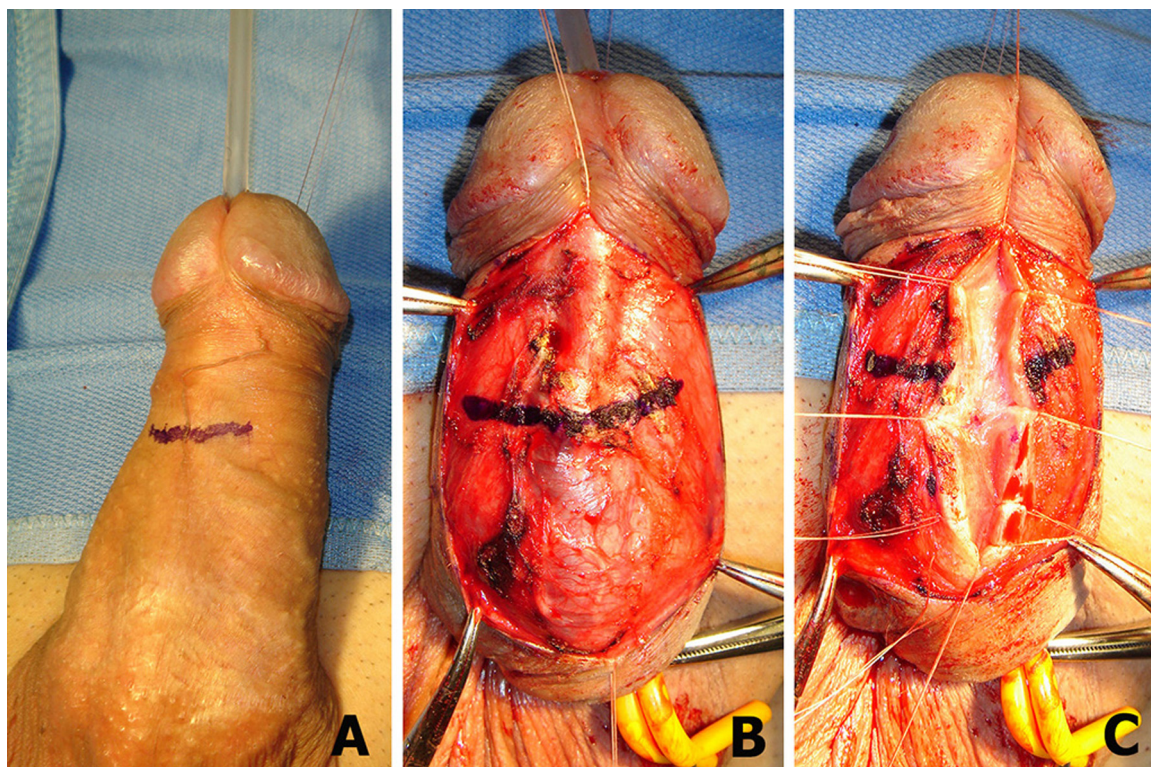


Figure 2 (A) The stricture is identified by the catheter. (B) The urethra is left adherent to the corpora cavernosa and the distal part of stricture is again identified. (C) The urethra is longitudinally opened extending for 2 cm in the distal and proximal healthy urethra.

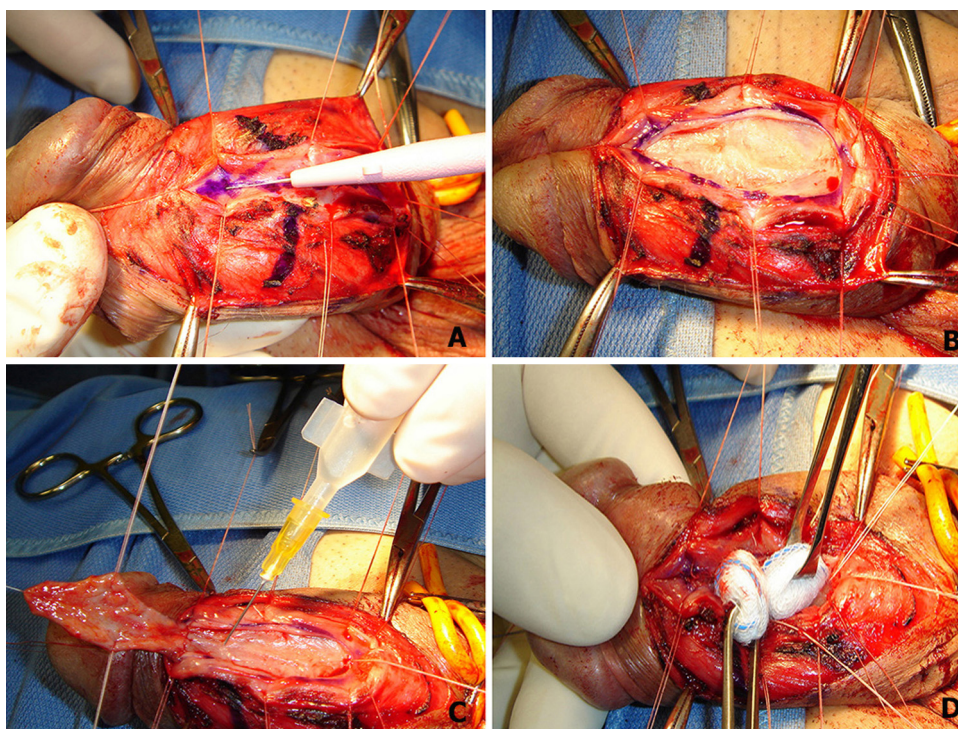


Figure 3 (A) The urethral plate is incised. (B) Longitudinal opening incision of the urethral plate. (C) Two ml of glue are injected onto the urethral plate. (D) The graft is moved over the glue bed and pressed for 45 s.

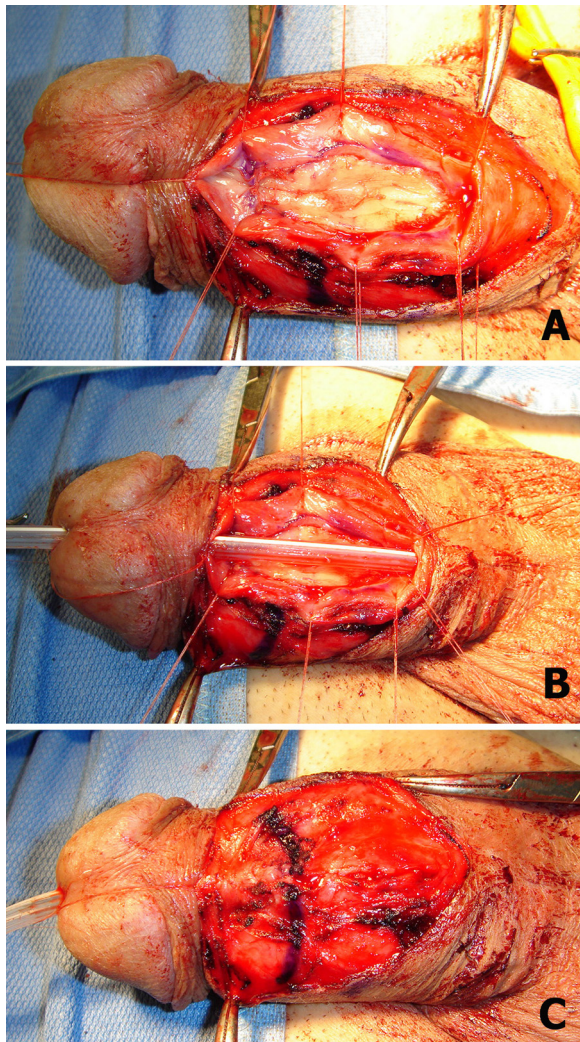


Figure 4 (A) The graft is fixed at the margins of the urethral plate. (B) A Foley 12 F catheter is inserted. (C) The urethra and dartos fascia are closed.

strictures, the penile urethra is approached by a midline longitudinal incision of the penile skin. We used, with some important changes, the technique described in 2001 by Asopa et al. [12].

The distal site of the stricture is identified by a Nelaton 16 F catheter through the meatus (Fig. 2A). The urethra is left adherent to the corpora cavernosa and the distal part of stricture is again identified (Fig. 2B). The urethra is longitudinally opened extending for 2 cm in the distal and proximal healthy urethra (Fig. 2C). The urethral mucosal plate is longitudinally incised (Fig. 3A). The longitudinal incision of the urethral plate is transformed into a wide window (Fig. 3B). Two ml of glue (Glubran 2®) are injected onto the urethral plate (Fig. 3C). The graft is moved over the glue bed and pressed using two small swabs for 45 s (Fig. 3D). The graft is fixed by 6/0 polyglactin stitches at the margins of the urethral plate, and no quilted sutures over the graft are used (Fig. 4A). A Foley 12 F silicone grooved catheter is inserted (Fig. 4B). The urethra is closed in a single layer over it using 5/0 polyglactin sutures, and the dartos fascia is closed over the suture line (Fig. 4C). The penile skin is closed meticulously and a soft dressing is applied.

Postoperative course and follow-up

Ice-bags are placed on the cheek and genital area for 24 h to reduce pain and hematoma formation. Patients are discharged from the hospital 3 days after surgery and voiding cystourethrography is performed 2 weeks later. The clinical outcome is considered a failure when any postoperative instrumentation is required, including dilation. Uroflowmetry and urine cultures are repeated every 4 months in the first year and annually thereafter. When symptoms of decreased force of stream are present and uroflowmetry is less than 14 ml per second, the urethrography, urethral ultrasound and urethroscopy are repeated.

Two-stage penile urethroplasty

First-stage urethroplasty

This technique was described by Johanson in 1953 [13]. The patient is placed in a simple supine position. A suture is placed in the glans to stretch the penis. The urethra is fully longitudinally opened along its ventral surface, leaving a wide open meatus proximally to void through. The penile skin margins are sutured to the margins of the urethral plate and the new urinary meatus is located in the healthy urethral mucosa 2 cm proximally to the stricture. A Foley 12 F silicone catheter is left in place for 3 days. A soft dressing is applied.

Postoperative course and follow-up

An ice-bag is placed on the genital area for 24 h to reduce pain and hematoma formation. Three days after surgery the dressing and catheter are removed and patients are discharged from the hospital. Every 4 months the patient is requested for a follow-up visit to perform uroflowmetry and a calibration of the new external urinary meatus by progressive insertion of 10, 12, 14, 16 F Nelaton catheters. The clinical outcome is considered a failure when any postoperative instrumentation is required, including dilation. Uroflowmetry and urine cultures are repeated every 4 months in the first year and annually thereafter. When symptoms of decreased force of stream are present and uroflowmetry is less than 14 ml per second, the urethrography, urethral ultrasound and urethroscopy are repeated. Six months after the first stage the patient is evaluated for closure of the urethra by second-stage urethroplasty (Fig. 5A).

Second-stage urethroplasty using buccal mucosa graft and glue

The patient is intubated through the nose, allowing the mouth to be completely free. The patient is operated by 2 surgical teams work simultaneously, each having its own set of surgical instruments. The oral mucosa graft is harvested from the cheek according to our standard technique used with more than 553 patients [11]. The graft is tailored according to the length and characteristics of the stricture. The patient is placed in a simple supine position. A suture is placed in the glans to stretch the penis. Before starting the urethra reconstruction the new meatus is again calibrated by progressive insertion of 10, 12, 14, 16 F Nelaton catheters. If the new meatus is well calibrated to 16 F, we begin the second stage. If the meatus do not accept the 16 F Nelaton catheter, we perform meatotomy and the second stage reconstruction is delayed for 6 more months. The lateral skin incisions and the midline incision of the urethral plate are outlined (Fig. 5B). The urethral plate is fully longitudinally incised and opened (Fig. 5C). Two ml of glue (Glubran 2®) are injected onto the window of the urethral plate (Fig. 5D). The graft is moved over

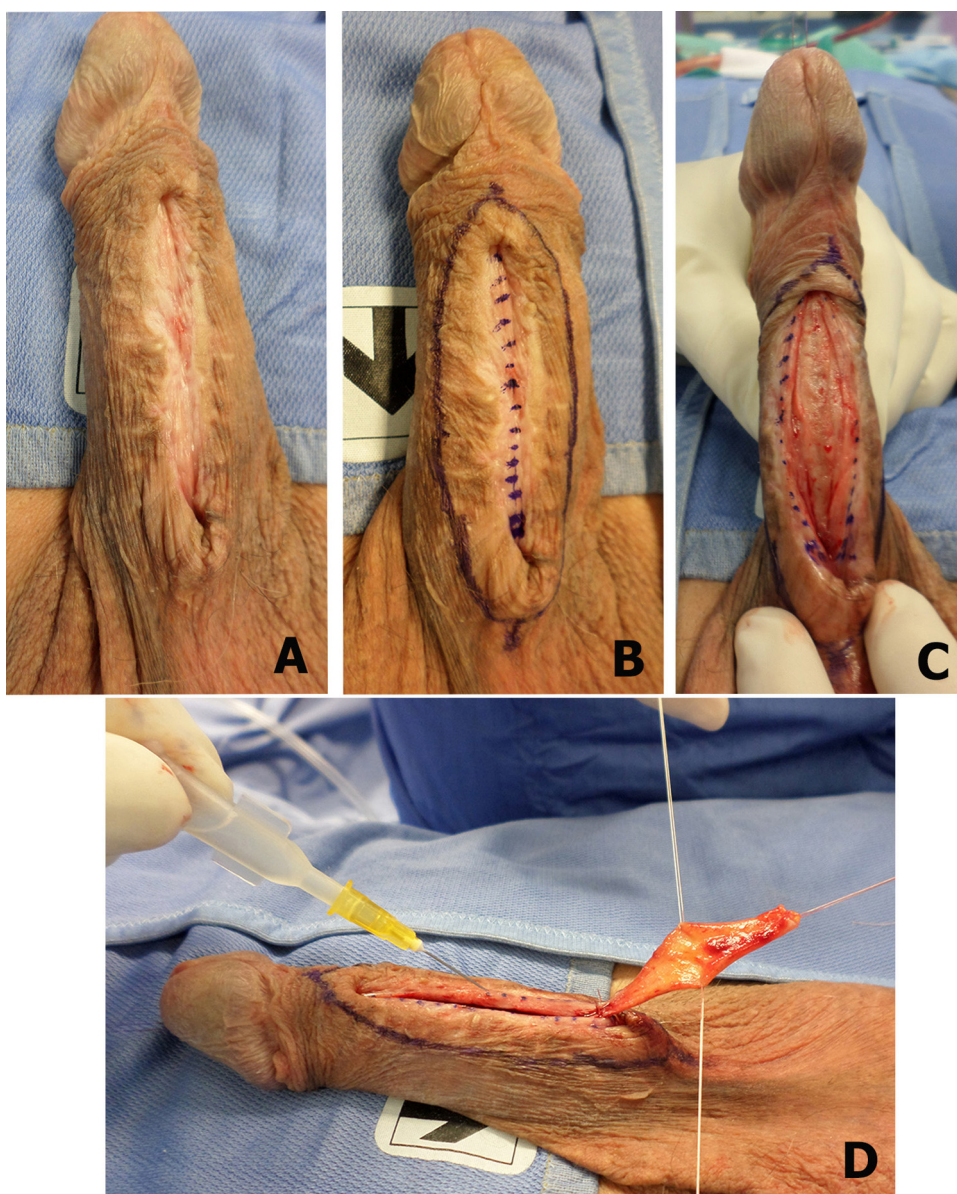


Figure 5 (A) Six months after the first stage the patient is evaluated for closure of the urethra. (B) The lateral skin incisions and the midline incision of the urethral plate are outlined. (C) The urethral plate is incised and opened. (D) Two ml of glue are injected onto the window of the urethral plate.

the glue bed and pressed using two small swabs for 45 s (Fig. 6A). The graft is fixed by two 6/0 polyglactin stitches at the extremities of the urethral plate incision and the lateral margins of the penile skin are incised (Fig. 6B). A Foley 12 F silicone grooved catheter is inserted (Fig. 6C). The urethra is closed in a single layer over it using 5/0 polyglactin sutures and the dartos fascia is closed over the suture line (Fig. 6D). The penile skin is closed meticulously and a soft dressing is applied.

Postoperative course and follow-up

Ice-bags are placed on the cheek and genital area for 24 h to reduce pain and hematoma formation. Patients are discharged from the hospital 3 days after surgery and voiding cystourethrography is

performed 2 weeks later. The clinical outcome is considered a failure when any postoperative instrumentation is required, including dilation. Uroflowmetry and urine cultures are repeated every 4 months in the first year and annually thereafter. When symptoms of decreased force of stream are present and uroflowmetry is less than 14 ml per second, the urethrography, urethral ultrasound and urethroscopy are repeated.

Discussion

We present here one- and two-stage techniques for penile urethral stricture repair. Using these three techniques, we are able to repair, in our center, the majority of penile strictures. In our experience,

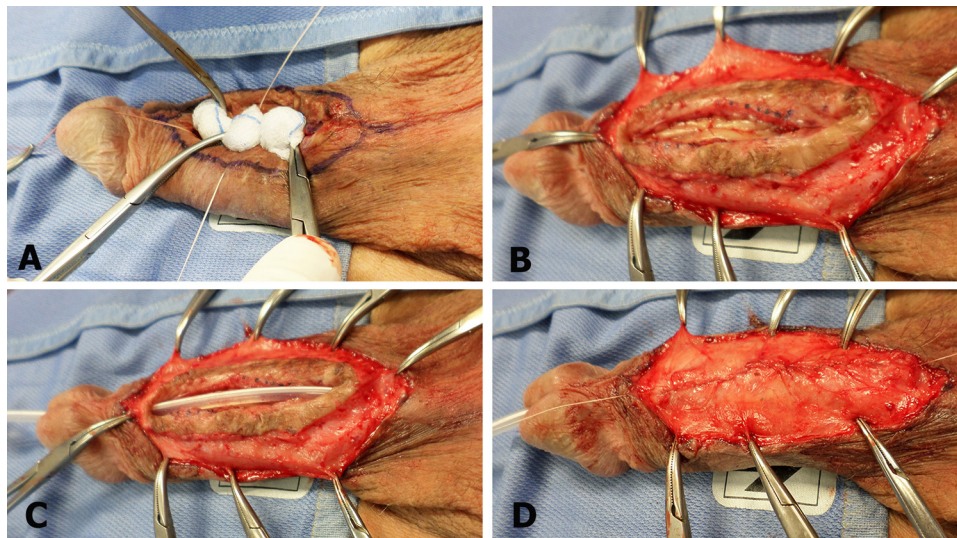


Figure 6 (A) The graft is moved over the glue bed and pressed for 45 s. (B) The graft is fixed at the urethral plate incision. (C) A Foley 12 F catheter is inserted. (D) The urethra and dartos fascia are closed.

the use of a buccal mucosa graft to repair penile strictures using a one-stage technique provides a higher success rate compared to the use of penile skin flaps [14]. Although, whether the use of a flap or graft is better during 1-stage repair is currently debated, the current literature does not offer any evidence for graft vs. flap and we believe that the choice should be based on stricture characteristics, surgeon background and preference [7–10,15]. We prefer the use of a buccal mucosa graft as the primary choice for one-stage penile urethroplasty and we choose to use a vascularized pedicled skin flap in failure redo-cases. The use of the graft entails a non-invasive surgery which better preserves all penile components (foreskin, dartos) greatly reducing the risk of complications (penile/glans torsion, hematoma, infection, skin necrosis, fistula, diverticulum).

In patients with penile strictures related to LS or FHR the rationale for the use of 2-stage repair using oral mucosa is well documented in the literature [7–10,16–19]. However, we have recently changed our practice to now use a two-stage penile urethroplasty, and we suggest using the buccal mucosa at the first stage only in patients with LS. In any patient with FHR or obliterative scarred penile strictures requiring two-stage repair, we do not use the oral graft in the first stage. This is due to the fact that in our previous experience the use of oral mucosa in the first stage showed a high incidence of scarring and retraction requiring multiple revisions, as also reported in the literature (Fig. 7) [8,16]. In our experience, the use of Johanson's opening of the penile urethra at the first stage, without using any substitution of oral graft, appears to be more suitable for an anatomical reconstruction at the second stage using an oral Asopa's graft inlay.

Penile urethra reconstruction still remains a challenging problem also in the hands of skilled surgeons, presenting higher complications and sequelae rates compared to bulbar or posterior urethroplasty. The aim of our work is to simplify the surgical techniques and improve the success rate of any type of urethroplasty. We must also consider that penile urethra reconstruction involves not only functional, but also esthetic and sexual aspects, and outcome evaluations may differ greatly between the surgeon-point of view and patient-point of view.

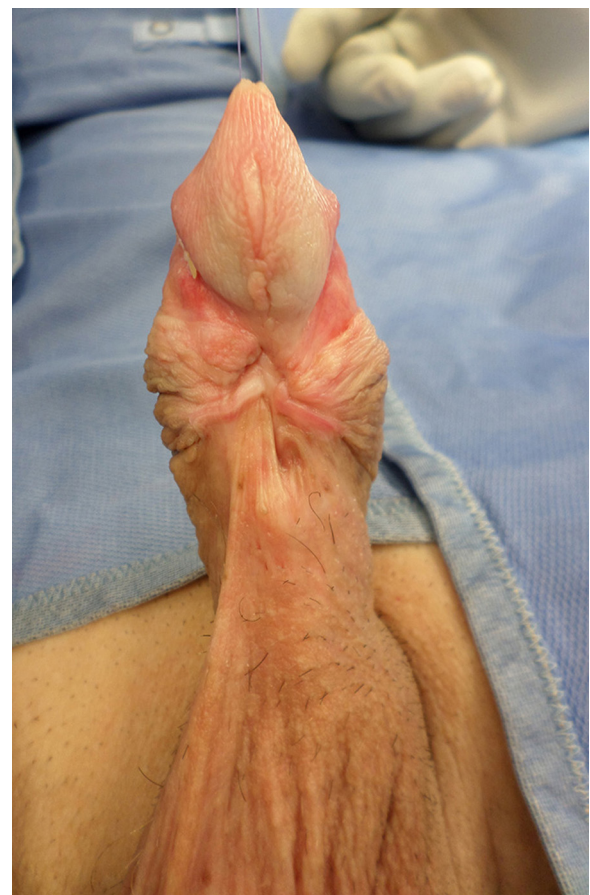

Figure 7 Complete scarring and retraction of buccal mucosa graft implanted 6 months prior in a first stage urethroplasty.

Conclusions

In the recent years, we have greatly changed and improved our techniques for repairing penile strictures. Using the non-invasive

techniques we presented here any surgeon will be able to repair the majority of simple (one-stage repair) or complex (two-stage repair) penile strictures of any etiology.

Conflict of interest

None of the contributing authors has any conflict of interest, including specific financial interests or relationships and affiliations relevant to the subject matter or materials discussed in the manuscript.

References

- [1] Fenton AS, Morey AF, Aviles R, Garcia CR. Anterior urethral strictures: etiology and characteristics. *Urology* 2005;65:1055–8.
- [2] Lumen N, Hoebeke P, Willemsen P, De Troyer B, Pieters R, Oosterlinck W. Etiology of urethral stricture disease in the 21st century. *J Urol* 2009;182:983–7.
- [3] Stein DM, Thum DJ, Barbagli G, Kulkarni S, Sansalone S, Pardeshi A, et al. A geographic analysis of male urethral stricture aetiology and location. *BJU Int* 2013;112:830–4.
- [4] Heyns CF, van der Merwe J, Basson J, van der Merwe A. Etiology of male urethral strictures – evaluation of temporal changes at single centre, and review of the literature. *Afr J Urol* 2012;18:4–9.
- [5] Ahmed A, Kalayi GD. Urethral stricture at Ahmadu Bello University Teaching Hospital, Zaria. *East Afr Med J* 1998;75:582–5.
- [6] Sharfi ARA, Elarabi YE. The “watering-can” perineum: presentation and management. *Br J Urol* 1997;80:933–6.
- [7] Andrich DE, Mundy AR. Surgery for urethral stricture disease. *Contemp Urol* 2001;13:32–44.
- [8] Andrich DE, Greenwell TJ, Mundy AR. The problem of penile urethroplasty with particular reference to 2-stage reconstructions. *J Urol* 2003;170:87–9.
- [9] Andrich DE, Mundy AR. What is the best technique for urethroplasty? *Eur Urol* 2008;54:1031–41.
- [10] Mundy AR, Andrich DE. Urethral strictures. *BJU Int* 2010;107:6–26.
- [11] Barbagli G, Fossati N, Sansalone S, Larcher A, Romano G, Dell’Acqua V, et al. Prediction of early and late complications after oral mucosal graft harvesting: multivariable analysis from a cohort of 553 consecutive patients. *J Urol* 2014;191:688–93.
- [12] Asopa HS, Garg M, Singhal GG, Singh L, Asopa J, Nischal A. Dorsal free graft urethroplasty for urethral stricture by ventral sagittal approach. *Urology* 2001;58:657–9.
- [13] Johanson B. Reconstruction of the male urethra in strictures. Application of the buried intact epithelium technic. *Acta Chir Scand* 1953;176(Suppl. 176):1–89.
- [14] Barbagli G, Morgia G, Lazzeri M. Retrospective outcome analysis of one-stage penile urethroplasty using a flap or graft I a homogeneous series of patients. *BJU Int* 2008;102:853–60.
- [15] Barbagli G, Lazzeri M, Gonzalez C. Opposing views. Penile urethral stricture reconstruction – flap or graft? *J Urol* 2011;186:375–7.
- [16] Barbagli G, De Angelis M, Palminteri E, Lazzeri M. Failed hypospadias repair presenting in adults. *Eur Urol* 2006;49:887–95.
- [17] Kulkarni S, Barbagli G, Kirpekar D, Mirri F, Lazzeri M. Lichen sclerosis of the male genitalia and urethra: surgical options and results in a multicenter international experience with 215 patients. *Eur Urol* 2009;55:945–56.
- [18] Barbagli G, Perovic S, Djinovic R, Sansalone S, Lazzeri M. Retrospective descriptive analysis of 1,176 patients with failed hypospadias repair. *J Urol* 2010;183:207–11.
- [19] Perovic S, Barbagli G, Djinovic R, Sansalone S, Vallascini S. Surgical challenge in patients who underwent failed hypospadias repair: is it time to change? *Urol Int* 2010;85:427–35.