



Pan African Urological Surgeons' Association

African Journal of Urology

[www.ees.elsevier.com/afju](http://www.ees.elsevier.com/afju)  
[www.sciencedirect.com](http://www.sciencedirect.com)



Original article

# A prospective analysis of the presentation and management of penile fracture at the Lagos State University Teaching Hospital (LASUTH), Ikeja, Lagos, Nigeria



O.A. Omisanojo<sup>a,\*</sup>, M.J. Bioku<sup>b</sup>, S.O. Ikuero<sup>a</sup>,  
G.A. Sule<sup>b</sup>, J.O. Esho<sup>a</sup>

<sup>a</sup> Urology Division, Department of Surgery, Lagos State University College of Medicine and Teaching Hospital (LASUCOM/LASUTH), Ikeja, Lagos, Nigeria

<sup>b</sup> Department of Surgery, Lagos State University Teaching Hospital (LASUTH), Ikeja, Lagos, Nigeria

Received 10 June 2014; received in revised form 20 July 2014; accepted 22 July 2014

## KEYWORDS

Fracture of the penis;  
Coitus;  
Late presentation;  
Complications

## Abstract

**Introduction:** Penile fracture though an uncommon urological emergency, can be associated with significant morbidity when it is not properly treated. Its etiology and management vary with geographical location. There are few reports on it in Nigeria.

**Objective:** The aim of our study was to prospectively analyze the aetiological factors, presentation and management of all cases of penile fracture presenting to our hospital over a 5-year period.

**Subjects and methods:** All the patients that presented to our hospital with penile fracture over a 5-year period from October 2008 to September 2013 were studied. The data were collected using a structured proforma documenting patient biodata, presenting complaints, duration of symptoms, aetiological factors, surgery done, intraoperative findings and post-operative complications.

**Results:** There was a total of 15 patients during the study period. The diagnosis was clinical in all cases and confirmed at surgery. The mean age of the patient was 35.2 years. The commonest aetiological factor was vigorous coitus (66.7%). None of the patients presented earlier than 4 h, though most of them (66.7%) presented within 48 h. All the patients (100%) had immediate operative repair. Right sided injuries were

\* Corresponding author at: Urology Division, Department of Surgery, Lagos State University College of Medicine and Teaching Hospital (LASUCOM/LASUTH), 1-5 Oba Akinjobi Road, Ikeja, Lagos, Nigeria.  
E-mail addresses: [sanjofunmi@yahoo.com](mailto:sanjofunmi@yahoo.com), [foluwadamilola@yahoo.com](mailto:foluwadamilola@yahoo.com) (O.A. Omisanojo).

Peer review under responsibility of Pan African Urological Surgeons' Association.

the commonest (53.3%) and overall, there was associated urethral injury in 26.7%. The mean hospital stay was 3.7 days. The identified complications were erectile dysfunction (6.7%) and penile curvature (13.3%). *Conclusion:* Coitus is the commonest aetiological factor for fracture of the penis in our environment. Though the majority of the patient still present late, immediate surgical repair is associated with a low complication rate.

© 2014 Pan African Urological Surgeons' Association. Production and hosting by Elsevier B.V. All rights reserved.

## Introduction

Penile fracture is defined as rupture of the tunica albuginea of the corpus cavernosum. It usually occurs in the tumescent state, and the rupture may extend to the corpus spongiosum surrounding the urethra [1]. In contemporary medical literature, the first penile fracture was recorded in 1924 [2]. However, an earlier report is ascribed to Abdulkasem, an Arab physician, who documented this clinical entity in Cordoba over a thousand years ago [3].

The true incidence of this genito-urinary emergency is unknown. In Africa, where discussions pertaining to sex and its consequences are largely restricted to the bedroom, most cases of penile fracture are under-reported [4–8]. Rather, the majority of recorded cases are predominantly from European and Asian countries [9–12].

There is some geographical variation in the etiologic factors of penile fracture [4,6,13,14]. For instance, in the USA, most cases are due to traumatic coitus [13], whereas masturbation and rolling over in bed onto an erect penis are the main causes of penile fractures in Japan [14].

The most common factors reported by patients from Mediterranean countries are kneading and snapping of the penis during erection to achieve detumescence [6].

While the tear in the tunica albuginea is typically unilateral [15], bilateral cases have also been documented [16]. The injury can be classified as simple or complex. Complex fractures are those that involve both corpora cavernosa or are associated with urethral injury [4,17].

Diagnosis is often clinical. However, in doubtful cases, penile ultrasonography, cavernosography or penile magnetic resonance imaging (MRI) will demonstrate a tear in the tunica albuginea and dissecting hematoma in the penile tissue. Characteristically, the patient hears a “popping” or “clicking” sound followed by immediate loss of erection, intense pain and penile swelling/deformity. Some patients may present in acute urinary retention or with urethral bleeding secondary to urethral injury.

Immediate penile exploration with evacuation of the hematoma, control of bleeders and repair of the rent in the tunica albuginea is the current preferred treatment option [4,6,18]. Conservative treatment has been reported to yield a good outcome in simple injuries [4,19].

There is a dearth of research on this subject in Africa, and the studies available are mostly retrospective [5–8]. Thus, we aim to prospectively analyze the presentation and management of

penile-fracture cases seen at the Lagos State University Teaching Hospital (LASUTH), Ikeja, Lagos, Nigeria over a 5-year period.

## Subjects and methods

All the patients who presented to the urological surgery division over a 5-year period between October 2008 and September 2013 were prospectively included in the study. The data was obtained by using a structured proforma. The clinical and pathologic characteristics studied included: the patients' biodata, presenting complaints, duration of symptoms and etiological factors, surgical procedure, intra-operative findings, post-operative complications and the outcome of the treatment. The diagnosis was made clinically. All cases of penile fracture were confirmed intra-operatively. Surgery entailed a subcoronal circumferential degloving incision, evacuation of clots (noting the site and dimension of the tear in the tunica, the presence or absence of concomitant urethral injury), and repair of the rent in the tunica with 2/0 vicryl sutures. The patients were followed up for 3–12 months. The International Index of Erectile Function (IIEF 5) was used to assess erectile function postoperatively. The data were analyzed using the IBM SPSS 19.0 software.

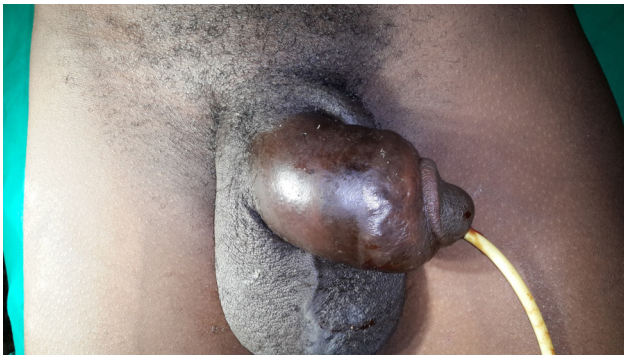## Results

In total, 15 patients were diagnosed with penile fracture within the 5-year study period. The mean age of the patients was 35.2 years with a range of 23–56 years. Eight (53.3%) of the patients were married, while 7 (46.7%) were single. The interval between the injury and presentation ranged from 4 h to 9 days with a mean of 2.5 days. Most of the patients ( $n = 10$ , 66.7%) presented within 48 h of injury. Only one patient reported on the 9th day after the incident.

The chief complaints found in all the cases were the triad of penile pain, swelling and deformity (Fig. 1). Twelve patients (80%) heard a “popping” sound, and there was blood at the external urethral meatus in 4 (26.7%) patients.

We found vigorous sexual intercourse to be the commonest etiological factor, accounting for 66.7% of the cases ( $n = 10$ ). Rolling over an erect penis in bed and masturbation caused the trauma in 3 (20%) and 2 (13.3%) patients, respectively. The injuries in the 7 unmarried patients were related to coitus.

The tear in the tunica was on the right in 8 (53.3%), on the left in 5 (33.3%) and bilateral in 2 patients (13.3%). A concomitant urethral injury was found in 4 patients (26.7%). The mean size of the tear in the tunica was 2.1 cm (range 0.5–4 cm).



**Fig. 1** Penile swelling and deformity - “Aubergine Sign” in a patient with penile fracture.

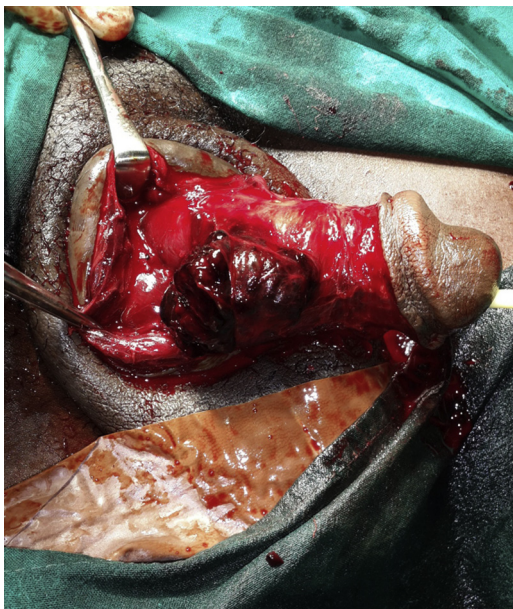
All our patients were subjected to immediate operative intervention with degloving of the penis, evacuation of the hematoma overlying the tear in the tunica (Figs. 2 and 3) and suturing of the tear. The urethral injuries encountered in 4 patients were managed with direct urethral suturing using 4/0 vicryl. A urethral catheter was left in situ for 3–4 weeks.

The mean hospital stay in our study was 3.7 days (range 1–6 days).

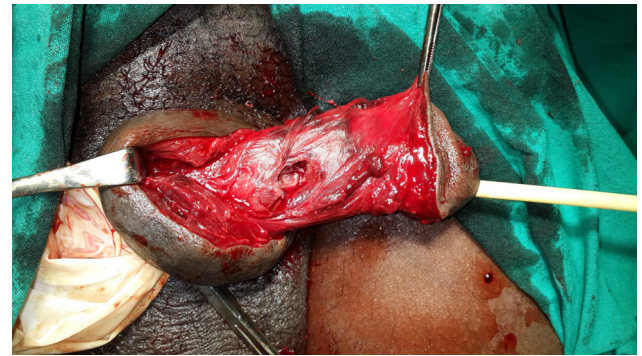
None of the patients had any early post-operative complication (Fig. 4). Over a follow-up period of 3–12 months (mean 7.2 months), one patient (6.7%) developed erectile dysfunction, while 2 (13.3%) had a slight penile curvature which did not preclude penetrative coitus.

## Discussion

Fracture of the penis is a relatively uncommon and rarely reported traumatic genito-urinary emergency [5,20]. While there are cases that remain undiagnosed or mismanaged by the attending general



**Fig. 2** Blood clot overlying the tear in the tunica albuginea after degloving the penis of the patient in Fig. 1.



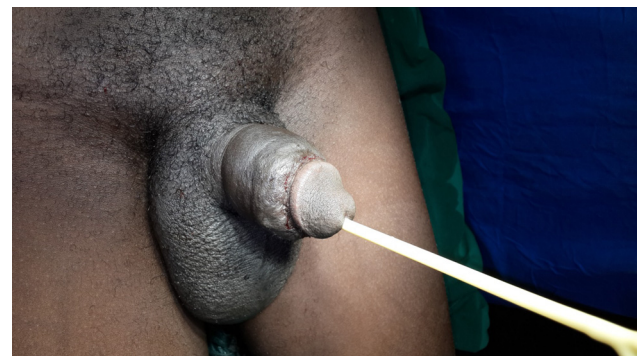**Fig. 3** Obvious defect in the tunica albuginea after evacuation of the overlying blood clot shown in Fig. 2.

medical practitioners [21], a number of patients with penile fracture would just not present to a medical facility because of perceived embarrassment and socio-cultural inhibitions.

In the tumescent state, when fracture usually occurs, the corpora cavernosa become engorged with blood and the tunica albuginea thins from 2 mm to 0.25–0.5 mm. As such, the strain of bulking can generate a pressure of 1500 mmHg and exceed the limit of the thinned tunica [4,22] which leaves the penis prone to fracture.

In our study, the mean age of patients with penile fracture was 35.2 years. This falls within the range reported in earlier series [8,23]. Geographical variations in the etiological factors of penile fracture have been previously documented [4,12,24]. Vigorous sexual intercourse with reverse attitudes (woman-on-top) resulting in an impact of the penis against the female pelvis or perineum is the leading cause in Europe and North America, accounting for 30–50% of cases. However, cases from the Middle East and Japan result mainly from penile manipulations during masturbation or forceful bending to achieve detumescence [9,12]. Overall, we recorded 66.7% of coitus-related fractures. 70% of these patients were unmarried. Being singles, it is not impossible that they were “experimenting” with different sex acts. Other causes seen in our study included rolling-over in bed (20%) and masturbation (13.3%).

The diagnosis of penile fracture was achieved clinically in all (100%) our patients without the use of radiological imaging. The only patient (6.7%) who had ultrasound done was the patient



**Fig. 4** The penis of the same patient shown in the earlier figures after completion of the repair.

who presented to us on the 9th day post-injury after having been subjected to a penile ultrasonography at the referring hospital.

The clinical features were characteristic with sudden penile pain and deformity and detumescence of the erect penis with most of the patients also hearing a “popping” sound. Local examination showed penile swelling and angulation previously described as “eggplant deformity” [9,25,26] or “aubergine sign” [4,17,27]. The point of maximum tenderness in the shaft appeared as a gap or depression underneath the clots, over which penile skin can be gently rolled (rolling sign) [28].

Although penile ultrasonography, cavernosography or MRI were done in doubtful cases in other studies, they were not found to be considerably superior to clinical evaluation, with some authors reporting that standard ultrasounds do not rule out the diagnosis of penile fracture [9,29].

Patients with associated urethral injury present with blood at the external meatus, gross hematuria or urinary retention. Four (26.7%) of our patients had concomitant urethral injury.

This finding is in keeping with reports from the USA and Europe where up to 20–38% of such cases were documented, but it contrasts with the figure of 0–3% of cases reported in series from the Middle East and Japan [30]. Some researchers [12] attributed the low incidence of associated urethral involvement in their series to the high incidence of non-intercourse related fractures. Curiously, however, other researchers also found a low incidence of concomitant urethral injury among intercourse-related fractures in their studies [31]. Thus, the main factor predisposing to urethral injury in penile fracture is as yet unclear.

All our patients were subjected to immediate operative intervention regardless of the timing of presentation. This is in accordance with the WHO recommendations [32]. Since the Fetter and Gartmen’s description of operative repair of penile fracture in 1936 [33], several approaches have been used. These include longitudinal incision over the hematoma [34], suprapubic incision [35], inguinoscrotal incision [36], high scrotal midline incision on the raphe [37] and penile degloving [38,39]. We favor the sub-coronal circumferential incision to deglove the penile shaft as advocated by McAninch et al. [9,40,41].

There was a right-sided bias in our series, comparable to other reports [3,11,28] where right-sided injuries also predominated. In complex cases, urethroplasty was done before apposing the rent in the tunica with inverted vicryl sutures. Routinely, an indwelling Foley catheter was left in situ for only 24 h in all but complex fractures in which it was left for a longer time. Our relatively long mean hospital stay of 3.7 days was due to the fact that most patients preferred complete resolution of the penile swelling before discharge.

None of our patients was managed conservatively. Currently, non-operative care is becoming uncommon, as immediate surgical repair has been found to be associated with fewer complications and increased patient satisfaction as well as a shorter hospital stay [1,7,18,42].

There is no consensus as to when sexual activity can be resumed after the repair of penile fracture. Patients with simple injuries were counseled to resume intercourse at one month as prescribed by Shittu

et al. [5]. However, the patients with complex fractures were advised to be abstinent for 3 months in order to prevent refracture [27].

The patients were followed up in our outpatient clinic for a mean period of 7.2 months (range 3–12 months). The penile deviation recorded in 13.3% of the patients was attributed to previous fibrosis at the site of the trauma [22,31].

## Conclusion

Though reports on penile fracture have increased in our region in recent years [5–8,43,44], there are still few.

A coitus-related cause is the leading etiological factor in our environment. There is still a significant delay in presentation, probably as a result of embarrassment or socio-cultural inhibition. Most patients in our study presented with the triad of penile pain, deformity and loss of erection, making clinical diagnosis straightforward. We found immediate surgical repair to be associated with a good outcome, regardless of the timing of presentation.

## Conflict of interest

The authors have no conflicts of interest to declare.

## References

- [1] Muentener M, Suter S, Hauri D, Sulser T. Long-term experience with surgical and conservative treatment of penile fracture. *Journal of Urology* 2001;172(2):576–9.
- [2] Malis J, Zur K. Der fractura penis. *Arch Klin Chir* 1924;129:651.
- [3] Al-Shaiji TF, Amann J, Brock GB. Fractured penis. *Journal of Sexual Medicine* 2009;6:3231–40.
- [4] Eke N. Fracture of the penis. *British Journal of Surgery* 2002;89(5):555–65.
- [5] Shittu OB. Urologic trauma in Nigeria. *African Journal of Trauma* 2003;1:30–4.
- [6] Mbonu OO, Aghaji AE. Fracture of the penis in Enugu, Nigeria. *Journal of the Royal College of Surgeons of Edinburgh* 1992;37(5):309–10.
- [7] Aderounmu AO, Salako AA, Olatoko SA, Eziyi AK, Agodinrin O. Penile fracture at LAUTECH Teaching Hospital, Osogbo. *Nigerian Journal of Clinical Practice* 2009;12(3):330–2.
- [8] Ugwu BT, Ylltok ST, Uba AF, Abduinrajid UF. Fracture of the penis: a rare injury on the Jos Plateau, Nigeria. *The Central African Journal of Medicine* 1998;44:107–9.
- [9] Zargooshi J. Penile fracture in Kermanshah, Iran: report of 172 cases. *Journal of Urology* 2000;164:364–6.
- [10] Hirasawa S, Tsuboi N, Abe H, Kanamori S, Okumura S, Nishimura T, et al. Fracture of the penis: report of 10 cases and a review of 231 cases in Japan. *Hinyokika Kyo* 1983;29:1047–50.
- [11] Ibrahim EI, El-Tholoth HS, Mohsen T, Hekal IA, El-Assmy A. Penile fracture: long-term outcome of immediate surgical intervention. *Urology* 2010;75:108–11.
- [12] El-Sherif AE, Dauleh M, Allowneh N, Vijayan P. Management of fracture of the penis in Qatar. *British Journal of Urology* 1991;68:622–5.
- [13] Nicoliasen GS, Melamud A, McAninch JW. Rupture of the corpus cavernosum: surgical management. *Journal of Urology* 1983;130:917–9.
- [14] Ishikawa T, Fujisawa M, Tamada H, Inove T, Shimatani N. Fracture of the penis: nine cases with evaluation of reported cases in Japan. *International Journal of Urology* 2003;10:257–60.
- [15] De Rose AF, Giglio M, Carmignani G. Traumatic rupture of corpora cavernosa: new physio-pathologic acquisitions. *Urology* 2001;57:319–22.

- [16] Tiwary SK, Singh MK, Khanna R, Khanna AK. Penile fracture presenting as eggplant deformity. *Kathmandu University Medical Journal* 2006;2(14):249–50.
- [17] De Stefani S, Subinski R, Ferneti F, Simonato A, Carmignani G. Penile fracture and associated urethral injury. *Scientific World Journal* 2004;4(Suppl 1):92–9.
- [18] Gamal WM, Osman MM, Hammady A, Aldahshoury MZ, Hussein MM, Saleem M. Penile fracture: long-term results of surgical and conservative management. *Journal of Trauma* 2011;71(2):491–3.
- [19] Mydlo JH, Gershbein AB, Macchia RJ. Nonoperative treatment of patients with presumed penile fracture. *Journal of Urology* 2001;166(2):633.
- [20] Khinev A. Penile fracture. *Khirurgiia (Sofia)* 2004;60(1):32–41.
- [21] El Atat R, Sfaki M, Benslama MR, Amine D, Ayed M, Mouelli SB, et al. Fracture of the penis: management and long-term results of surgical treatment, experience in 300 cases. *Journal of Trauma* 2008;64:121–5.
- [22] Asgari MA, Hosseini SY, Safarinejad MR, Samadzadeh B, Bardideh AR. Penile fractures: evaluation, therapeutic approaches and long-term results. *Journal of Urology* 1996;155(1):148–9.
- [23] Dincel C, Caskurlu T, Resim S. Fracture of the penis. *International Urology and Nephrology* 1998;30(6):761–5.
- [24] Grima F, Paparel P, Devonec M, Perrin P, Caillot JL, Ruffion A. Management of corpus cavernosum trauma. *Progrès en Urologie* 2006;16:12–8 [in French].
- [25] Ozcan S, Akpınar E. Diagnosis of penile fracture in primary care: a case report. *Cases Journal* 2009;2:8065. <http://dx.doi.org/10.4076/1757-1626-2-8065>.
- [26] Khan RM, Malik MA, Jamil M, Khan D, Shah IH. Penile fracture: experience at Ayub Teaching Hospital. *Journal of Ayub Medical College* 2008;20(4):49–50.
- [27] Bejelloum M, Rabil R, Bennani S, Querfani B, Joual A. Fracture of the corpus cavernosum: report of 123 cases. *African Journal of Urology* 2003;9(2).
- [28] Jack GS, Garraway I, Reznicek R, Rajfer J. Current treatment options for penile fractures. *Reviews in Urology* 2004;6(3):114–20.
- [29] Michael M, Stefan S, Dieter H, Tullio S. Long term experience with surgical and conservative treatment of penile fracture. *Journal of Urology* 2004;172:576–9.
- [30] McDougal WS. Methods of care and special considerations of perineal genital wounds. In: *Libertino JA, editor. Reconstructive urologic surgery*. 3rd ed. St. Louis, MO: Mosby; 1998. p. 653.
- [31] Tan LB, Chaing CP, Huang CH, Chou YH, Wang CJ. Traumatic rupture of the corpus cavernosum. *British Journal of Urology* 1991;68:626–8.
- [32] Van Der Horst C, Martinez Portillo FJ, Bannowsky A, Seif C, Juenemann KP. Penile fractures: controversy over surgical or conservative treatment. *BJU International* 2003;92:349–50.
- [33] Fetter TR, Gartmen E. Traumatic rupture of penis. Case report. *American Journal of Surgery* 1936;13:371–2.
- [34] Ozen HA, Erkan I, Alkibay T, Kendi S, Remzi D. Fracture of the penis and long-term results of surgical treatment. *British Journal of Urology* 1986;58(5):551–2.
- [35] Konnak JW, Ohl DA. Microsurgical penile revascularization using the central corporeal penile artery. *Journal of Urology* 1989;142(2 Pt 1):305–8.
- [36] Seftel AD, Haas CA, Vafa A, Brown SL. Inguinal scrotal incision for penile fracture. *Journal of Urology* 1998;159(1):182–4.
- [37] Su LM, Sutaria PM, Eid JF. Repair of penile rupture through a high-scrotal midline raphe incision. *Urology* 1998;52(4):717–9.
- [38] Uygur MC, Gülerkaya B, Altug U, Germiyanoglu C, Erol D. 13 years' experience of penile fracture. *Scandinavian Journal of Urology and Nephrology* 1997;31(3):265–6.
- [39] Zargooshi J. Penile fracture in Kermanshah, Iran: the long-term results of surgical treatment. *BJU International* 2002;89(9):890–4.
- [40] Miller S, McAninch JW. Penile fracture and soft tissue injury. In: *McAninch JW, editor. Traumatic and reconstructive urology*. Philadelphia: W.B. Saunders; 1996. p. 693–8.
- [41] Mydlo JH. Surgeon experience with penile fracture. *Journal of Urology* 2001;166:526–9.
- [42] Nawaz H, Khan M, Tareem FM, Khan S. Penile fracture: presentation and management. *Journal of the College of Physicians and Surgeons–Pakistan* 2010;20(5):331–4.
- [43] Salako AA, Aderounmu AOA, Olatoke SA, Oyedeji SA. Fractured penis while turning over in bed: a case report and review of the literature. *Journal of Surgical Sciences* 2008;3(1):11–4.
- [44] Badmus TA, Adesunkanmi ARK, Ogunrombi AO. Penile fracture in a patient with stuttering priapism. *West African Journal of Medicine* 2004;23(3):270–2.