



Pan African Urological Surgeons' Association

African Journal of Urology

[www.ees.elsevier.com/afju](http://www.ees.elsevier.com/afju)  
[www.sciencedirect.com](http://www.sciencedirect.com)



## Editorial

# Mesoblastic nephroma: Pathological features<sup>☆</sup>



### Abstract

This correspondence is an editorial comment on the previously published article entitled “Trois observations de néphrome mésoblastique avant l’âge de 6 mois” in AFJU Vol. 20, No. 3 Pages 161–164”. Since the authors of that article focused mainly on the clinical and radiological aspects of the tumor with only very brief reference to its pathological features, and since the variable behavior of mesoblastic nephroma is determined mainly by its histologic type, we found it worthwhile to elaborate more on the gross and microscopic features of that tumor.

© 2014 Pan African Urological Surgeons' Association. Production and hosting by Elsevier B.V. All rights reserved.

We had the privilege of reviewing the manuscript submitted for publication in this journal, reporting three cases of mesoblastic nephroma. Since the authors of the manuscript focused mainly on the clinical and radiological aspects of the tumor with only very brief reference to its pathological features, and since the variable behavior of mesoblastic nephroma is determined mainly by its histologic type, we found it worthwhile to elaborate more on the gross and microscopic features of that tumor in an editorial comment.

Mesoblastic nephroma (also called fetal, mesenchymal, or leiomyomatous hamartoma) was first described by Bolande et al. in 1967 [1]. Although rare with an incidence of 8 per million in children under the age of 15 years [2], it is the commonest renal tumor in infancy, that is mostly diagnosed within the first three months of life and may even present in utero with associated hydramnios due to excessive fetal urine production [3].

**On gross examination**, the tumor is solid, yellowish gray to tan, with a whorled cut surface reminiscent of uterine leiomyoma. Most tumors are located near the hilus of the kidney. The tumor is usually well circumscribed, but it may be seen infiltrating the renal

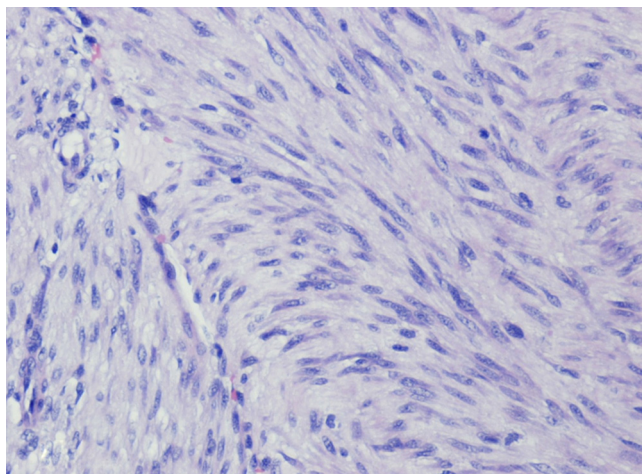
parenchyma and even the perirenal fat. Cysts are occasionally present. There may be also hemorrhage and necrosis. Mesoblastic nephromas may extensively involve the renal sinus. Therefore, careful examination of the medial aspect of the nephrectomy specimen by the surgeon and the pathologist is extremely important [4].

Mesoblastic nephroma is **classified into** classic and cellular types on basis of **microscopic appearance** [4]. The **classic type** consists of fascicles and whorls of spindly cells (Fig. 1). These cells have the features of secondary mesenchyme, which, in contrast with those of primary mesenchyme (mesoblast), lack the capacity to form epithelial structures. Instead, the proliferating cells acquire the features of fibroblasts, myofibroblasts, or smooth muscle cells. As such, they contain vimentin, fibronectin, and sometimes actin, but not keratin or laminin. The tumor has irregular borders, with bands of tumor extending into surrounding soft tissue. It also permeates the adjacent renal parenchyma to encircle groups of tubules and glomeruli (Fig. 2). Metaplastic tissues are usually found at the tumor-kidney interface or near entrapped renal tubules and glomeruli, most commonly cartilage (Fig. 3). Extramedullary hematopoiesis and cuboidal metaplasia may also be present. Mitotic figures may be encountered, but frequent mitoses are more characteristically seen in cellular mesoblastic nephroma.

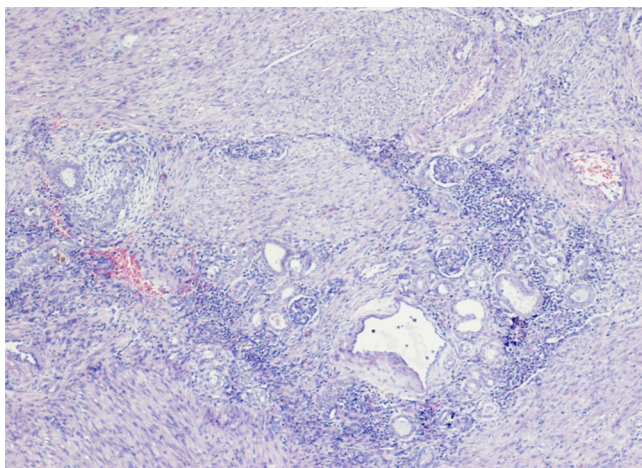
**Cellular mesoblastic nephroma** is more cellular than the classical type and has a sarcomatous appearance consisting of tightly packed cells with frequent mitoses (25–30/10 HPF). Data from the National Wilms Tumor Study show that cellular mesoblastic nephroma is

<sup>☆</sup> This is an editorial comment on the previously published French article entitled “Trois observations de néphrome mésoblastique avant l’âge de 6 mois” in AFJU Vol. 20, No. 3 Pages 161–164”.

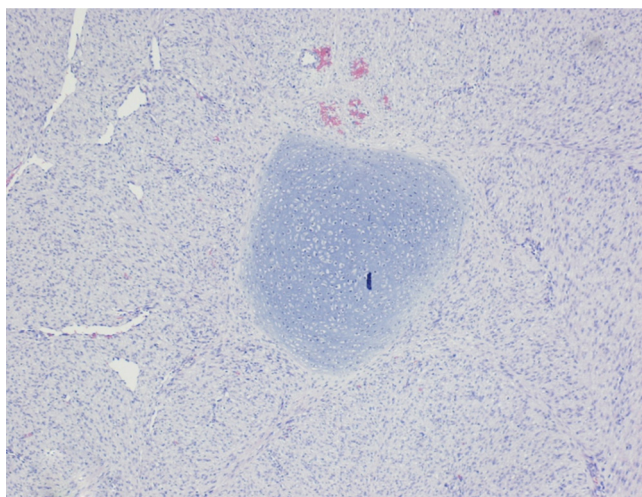
Peer review under responsibility of Pan African Urological Surgeons' Association.



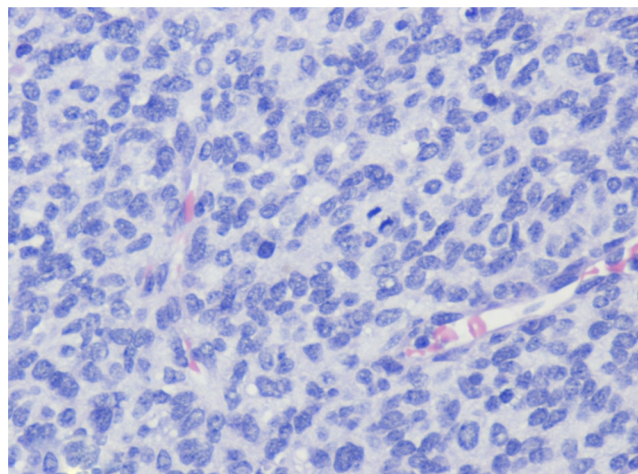
**Fig. 1** Classical mesoblastic nephroma. Note fascicles of bland spindly cells (H&E  $\times 200$ ).



**Fig. 2** Classical mesoblastic nephroma. Note entrapped glomeruli & tubules (H&E  $\times 50$ ).



**Fig. 3** Classical mesoblastic nephroma. Note metaplastic cartilage (H&E  $\times 100$ ).



**Fig. 4** Cellular mesoblastic nephroma. Note closely packed plump cells & mitotic figures (H&E  $\times 400$ ).

commoner than classic mesoblastic nephroma with a ratio of 3:1, and that the former presents a few months later in life than the latter [5]. Unlike the classic type, cellular mesoblastic nephroma may reach a huge size and can weigh more than 1 kg. Histologically, two types of cells are seen. The more common cell type is a plump cell with ample cytoplasm and a vesicular nucleus (Fig. 4). The less common type is a blue cell, which shows less cytoplasm and resembles cells of infantile fibrosarcoma. Recently, both cellular mesoblastic nephroma and infantile fibrosarcoma were found to harbor the *t*(12;15)(p13;q25) translocation, resulting in an *ETV6-NTRK3* gene fusion [6]. It is currently thought that cellular mesoblastic nephroma is actually a renal variant of infantile fibrosarcoma.

The histologic **differential diagnosis** for mesoblastic nephroma includes mainly Wilms tumor, clear cell sarcoma, rhabdoid tumor and metanephric stromal tumor [7].

Cartilage may be present in both mesoblastic nephroma and Wilms tumor. The presence of skeletal muscle and blastema, age older than 1 year, bilateral tumors, and nephrogenic rests favor the diagnosis of Wilms tumor over mesoblastic nephroma.

Mesoblastic nephroma and clear cell sarcoma are both tumors of early infancy. The observation of tumor tissue encircling islands of renal parenchyma rather than isolating single nephrons favors a diagnosis of mesoblastic nephroma over clear cell sarcoma. Mesoblastic nephroma also shows positive immunostaining for smooth muscle actin.

The plump cells of cellular mesoblastic nephroma may suggest a diagnosis of rhabdoid tumor. However, rhabdoid tumor usually presents with extensive metastatic disease and also shows characteristic inclusions in the cytoplasm of the neoplastic cells, which are not seen in mesoblastic nephroma.

Metanephric stromal tumor may also closely simulate mesoblastic nephroma. However, it exhibits a nodular growth pattern at low-power examination, along with onion-skin cuffing around entrapped renal tubules, heterologous differentiation and positive

immunostaining for CD34. It also occurs at an older age than mesoblastic nephroma.

Complete surgical excision including the entire capsule is considered adequate therapy for mesoblastic nephroma. Patients at increased risk of recurrence and/or metastasis are those showing incomplete resection with positive resection margins, cellular type, and age at diagnosis of more than 3 months [8].

#### Conflicts of interest

The authors declare there are no conflicts of interest.

#### References

- [1] Bolande PP, Brough AJ, Izant RJ. Congenital mesoblastic nephroma of infancy. *Pediatrics* 1967;40:272–9.
- [2] Khashu M, Osiovich H, Sargent M. Congenital mesoblastic nephroma presenting with neonatal hypertension. *J Perinatol* 2005;25:433–5.
- [3] Ohmichi M, Tasaka K, Sugita N, Kamata S, Hasepwa T, Tanizawa O. Hydramnios associated with congenital mesoblastic nephroma: case report. *Obstet Gynecol* 1989;74:46.
- [4] Ordonez G, Rosai J, editors. Urinary tract in Rosai & Ackerman's surgical pathology, vol. I, 10th ed. St. Louis: Mosby; 2011 [chapter 17].
- [5] Zaidie M. Kidney tumors. In: Pathology outlines.com; 2012.
- [6] Argani P, Fritsch M, Kadkol SS, Schuster A, Beckwith JB, Penlman EJ. Detection of the ETV6-NTRK3 chimeric RNA of infantile fibrosarcoma/cellular congenital mesoblastic nephroma in paraffin-embedded tissue: application to challenging pediatric stromal tumors. *Mod Pathol* 2000;13:29–36.
- [7] Argani P, Beckwith JB. Metanephric stromal tumor: report of 31 cases of a distinctive pediatric renal neoplasm. *Am J Surg Pathol* 2000;24:917–26.
- [8] England R, Haider N, Vuganic G, Kelsey A, Stiller CA, Ptchard-Jones K, et al. Mesoblastic nephroma: a report of the United Kingdom Children's Cancer and Leukemia Group(CCLG). *Pediatr Blood Cancer* 2011;56(5):744–8.

N.M. El-Badawy\*

*Pathology Department, Faculty of Medicine, Ain Shams University, Egypt*

M.A. El-Shawarby

*Department of Pathology, College of Medicine, University of Dammam, Kingdom Saudi Arabia*

\* Corresponding author.

E-mail address: [n\\_elbadawy@hotmail.com](mailto:n_elbadawy@hotmail.com) (N.M. El-Badawy)

Received 21 May 2014