



Pan African Urological Surgeons' Association

African Journal of Urology

www.ees.elsevier.com/afju
www.sciencedirect.com



Case report

Near total penile amputation caused by hair tourniquet, managed with the URAGPI procedure



V.K. Dikshit*, R.K. Gupta, P.R. Kothari, A.R. Gupta, R.S. Kamble, K.V. Kesan

Department of Pediatric Surgery, LTMMC & LTMGH, Sion Hospital, Mumbai, India

Received 25 September 2014; accepted 18 November 2014
Available online 2 December 2015

KEYWORDS

Penile hair tourniquet;
Penile amputation;
URAGPI

Abstract

The hair tourniquet syndrome is an unusual phenomenon which can cause severe damage to the affected organ, sometimes even its loss. This problem requires urgent attention and prompt management to ensure anatomical and functional preservation. Herein we report a case of penile hair tourniquet which was successfully managed using the urethral advancement and glanuloplasty incorporated procedure (URAGPI).

© 2015 Pan African Urological Surgeons' Association. Production and hosting by Elsevier B.V. All rights reserved.

Case report

A 10-year-old circumcised boy presented to our casualty with swelling in his penile shaft and glans penis which had developed 2 days before (Fig. 1). He was passing urine through an opening on the ventral side of the shaft. Physical examination of the penis revealed an edematous glans with a constriction band at the corona where a line of demarcation had formed. A urethrocutaneous fistula was visible proximal to the constriction. During examination under

anesthesia, a coil of hair, almost invisible, was found embedded deeply in the necrotic tissue encircling the shaft of the penis. The patient was catheterized with an 8Fr Foley catheter, and the coil of hair was carefully removed. Tacking sutures were placed between the glans and the penile shaft to avoid complete amputation (Fig. 2). After removal of the catheter 10 days later, the patient passed urine from urethrocutaneous fistula at the corona. The patient was kept on regular follow-up and scheduled for definitive repair 6 months later.

During surgery the glans was found to be connected to the shaft with only very narrow fibrotic tissue (Fig. 3). Hence, we decided on urethral advancement and glanuloplasty incorporated repair. The penile skin with a small amount of subcutaneous tissue was degloved down to the base, lifting it carefully off the urethra. The urethra itself

* Corresponding author.

E-mail address: kvisheshd@gmail.com (V.K. Dikshit).

Peer review under responsibility of Pan African Urological Surgeons' Association.

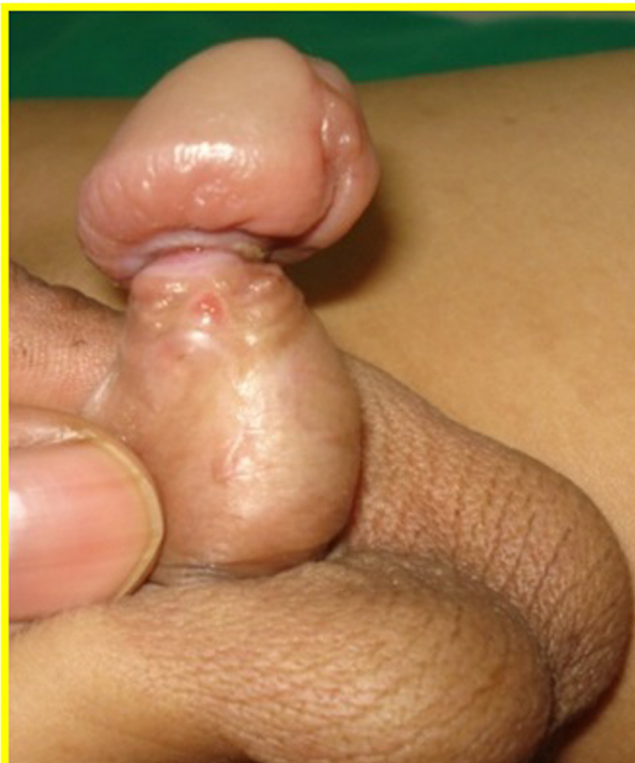

Figure 1 Edematous glans with line of demarcation.

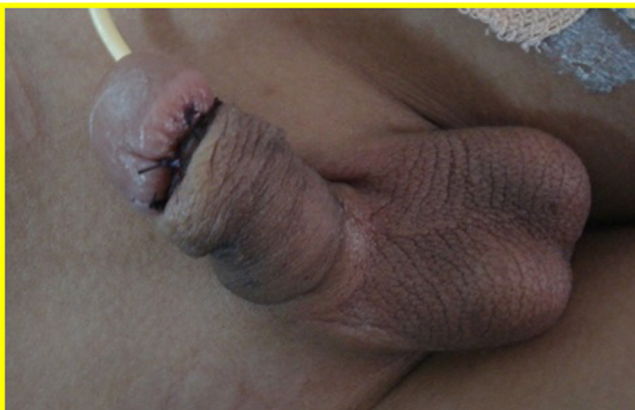

Figure 2 Tacking sutures between glans and shaft.

was mobilized away from the underlying spongiosa until a sufficient length was obtained so as to reach the tip of the glans. Next, the glans wings were raised and the urethra was moved up to the tip of the glans where it was fixed. The glans was closed over the urethra and the degloved skin was repositioned and sutured (Figs. 4-6). The patient tolerated the procedure well, and on removal of the per-urethral stent on the 12th postoperative day he passed urine in a single strong stream from the tip of the penis. Follow up at 6 months showed a good single stream from the tip of the penis.

Discussion

The urethral advancement glanuloplasty incorporated procedure was first described by Keramidas and Soutis in 1995 and is based

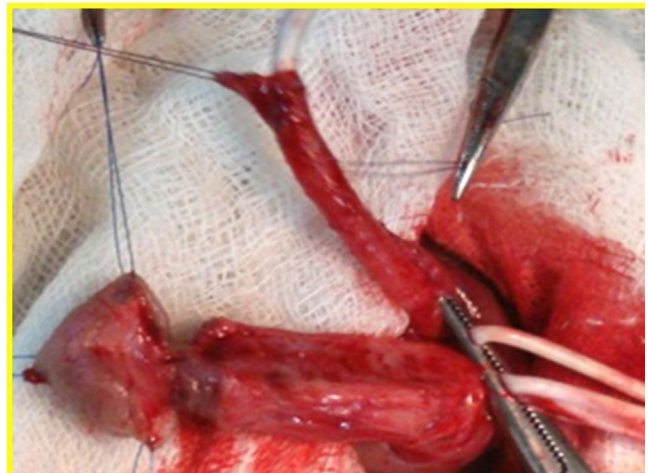


Figure 3 Narrow connection between glans and shaft, seen after degloving.

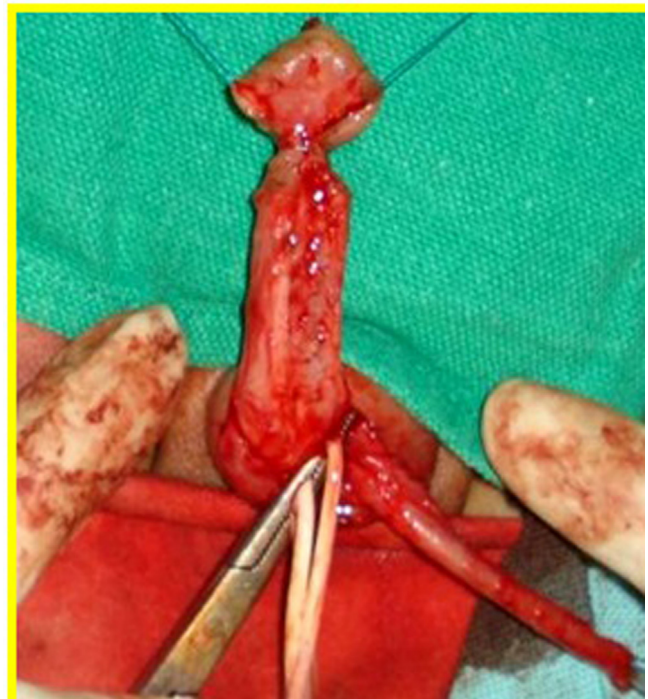

Figure 4 Narrow connection between glans and shaft, seen after degloving.

on the ability and amenability of the urethra to be mobilized and moved up to the tip of the glans in cases of distal hypospadias.

Quinn first used the term hair tourniquet syndrome (HTS) in 1971, but the very first description of the condition dates back to 1832 [1]. A hair tourniquet syndrome is defined as the presence of a strand of hair tightly coiled around an appendage. Body parts usually involved include the fingers, toes, penis, clitoris and vulva. It is a rare condition, and the exact incidence is not known. The etiology is usually described as accidental, but child abuse must be ruled out. Circumcision is the most important predisposing factor as it bares the coronal sulcus around which hair strands may get wrapped [2]. Human hair being very thin, the problem may be easily missed,

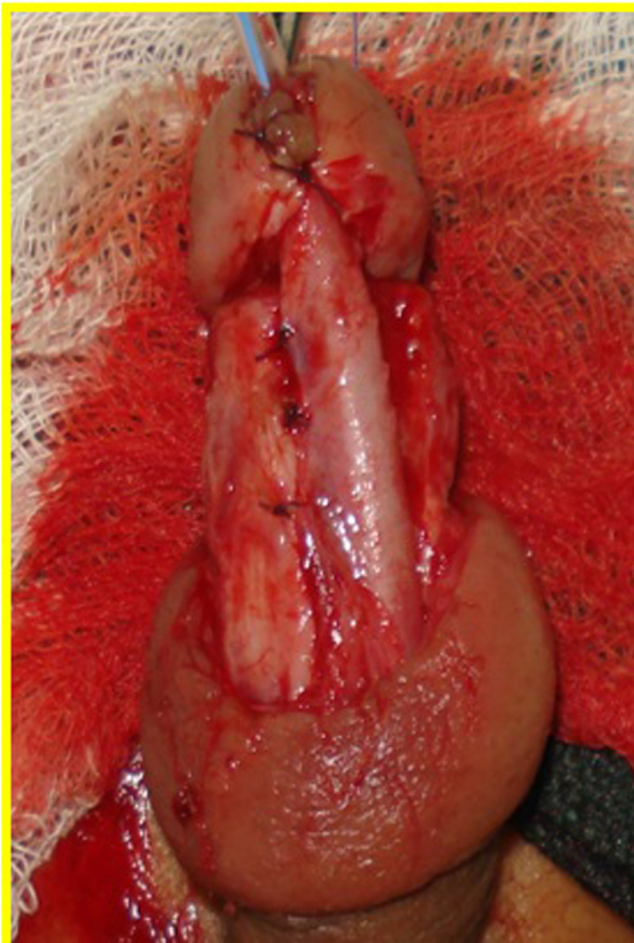


Figure 5 Urethra fixed in position.

especially in the presence of edema and swelling of the tissue. As hair has a very high tensile strength and stretches when wet and contracts while drying, it applies a tightening constriction of the structure it is coiled around and may even lead to amputation [3].

Penile strangulation was graded by Bashir and EL-Barbary [4] as follows:

- Grade 0: Constriction of skin without urethral injury.
- Grade 1: Partial division of the corpus spongiosum with a urethrocutaneous fistula.
- Grade 2: Complete division of the corpus spongiosum and constriction of the corpus cavernosum.
- Grade 3: Gangrene, necrosis and complete amputation of the glans.

Our patient had a grade-2 injury.

Management of HTS requires a high index of suspicion and early intervention. The causative agent (hair) should be removed promptly to avoid further damage. Useful techniques are the unwrapping technique, the blunt probe cutting technique and the incisional approach. Depilatory creams may also be used, if access to the band of hair is limited due to edema. Once the constricting band is removed, attention must be directed toward the urethra and, depending on the severity of the injury, either end-to-end urethroplasty or URAGPI may be utilized. Using URAGPI, the urethra may be mobilized up

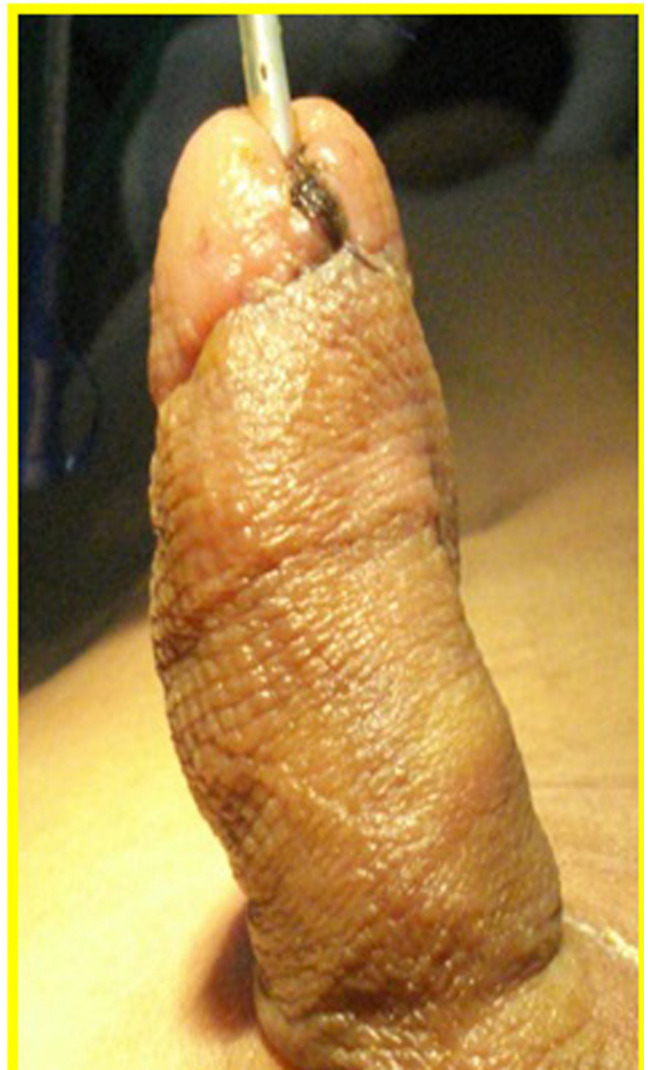

Figure 6 Result on postoperative day 7.

to 3 times the length of the distance between neomeatus and corona. Advantages of URAGPI are a lesser incidence of fistula and diverticula formation and good cosmetic results. Disadvantages of the technique include the development of chordee, glanular disruption, meatal retraction or stenosis. Kirtane and Samuel reported using the technique of urethral mobilization in patients with urethrocutaneous fistula where they discarded the glanular urethra and used the fistula as the final meatus [5].

Conclusion

The hair tourniquet syndrome is an unusual entity and must be considered as a surgical emergency. Early diagnosis and treatment are required to prevent the loss of appendage. The choice of the final procedure depends on the severity of the injury and must be tailored to the requirements of each individual case.

Conflict of interest

The authors have no conflict of interest to declare.

References

- [1] Singh V, Singh P, Sharma A, Sarkar J. Acquired constriction ring syndrome as a cause of inconsolable cry in a child: a case report. *Cases J* 2008;1:92.
- [2] Sotolongo Jr JR, Hoffman S, Gribetz ME. Penile denudation injuries after circumcision. *J Urol* 1985;132:102–3.
- [3] Alpert JJ, Filler R, Glaser HH. Strangulation of an appendage by hair wrapping. *N Engl J Med* 1965;273:866–7.
- [4] Bashir AY, El-Barbary M. Hair coil strangulation of the penis. *J R Coll Surg Edinb* 1980;25:47–51.
- [5] Kirtane JM, Samuel KV. Hair coil strangulation of the penis. *J Pediatr Surg* 1994;29(10):1317–8.