



Pan African Urological Surgeons' Association

African Journal of Urology

[www.ees.elsevier.com/afju](http://www.ees.elsevier.com/afju)  
[www.sciencedirect.com](http://www.sciencedirect.com)



## Case report

# Recurrence of isolated transitional cell carcinoma in an orthotopic ileal neobladder: A case report



A.M. Moeen

Assiut Urology and Nephrology Hospital, Assiut University, Assiut, Egypt

Received 17 February 2015; received in revised form 30 May 2015; accepted 12 June 2015  
Available online 10 November 2015

### KEYWORDS

Ileal;  
Neobladder;  
Recurrent;  
Transitional cell carcinoma (TCC);  
Tumor

### Abstract

Recurrent tumors inside an orthotopic ileal neobladder are rare, and only few cases have been reported in the literature. Herein, we report a case of recurrent transitional cell carcinoma in an orthotopic ileal neobladder discovered one and a half years after the operation.

© 2015 Pan African Urological Surgeons' Association. Production and hosting by Elsevier B.V. All rights reserved.

## Introduction

Secondary malignancies developing inside neobladders following intestinal urinary diversion are not uncommon. According to Stewart et al., tumor growth after colonic diversion may be due to the effect of fecal bacteria on urinary nitrate leading to the development of nitrosamine which is an active carcinogen [1]. Meanwhile, urothelial carcinoma recurrence in an orthotopic ileal neobladder is extremely rare with less than 10 cases reported to date [2,3]. We present the case of a female patient with isolated recurrent transitional cell carcinoma (TCC) in an ileal neobladder, diagnosed 18 months after radical cystectomy and modified Hautmann ileal bladder substitution.

## Case report

In February 2010, a 59-year-old female had been diagnosed with high-grade muscle-invasive TCC of the bladder (pT2) after performing investigations for lower urinary tract symptoms of 3 months' duration. She was subjected to radical cystectomy and creation of a modified Hautmann orthotopic ileal neobladder. All postoperative surgical margins were negative (high grade, stage pT2N0M0). On follow-up 18 months later, the patient reported gross hematuria. Abdominal ultrasound showed an echogenic growth within the neobladder. Multiplanar MRI revealed the presence of a lesion with restricted diffusion, indicative of a neoplastic nature, and absence of lymphadenopathy (Fig. 1).

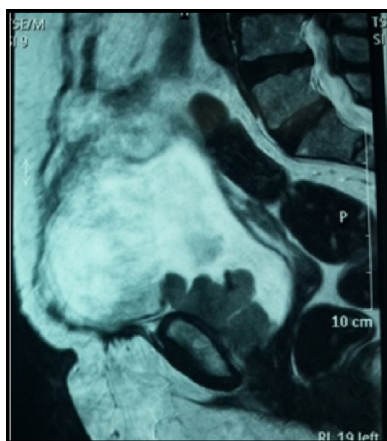Cystoscopic examination revealed multifocal papillary tumors sized about 4 cm × 5 cm and 3 cm × 2 cm in the region of the right and left lateral walls of the pouch, respectively. The urethra and urethroenteric anastomosis were tumor-free. Laboratory work-up revealed normal results (Fig. 2).

E-mail address: [moeen3@yahoo.com](mailto:moeen3@yahoo.com)

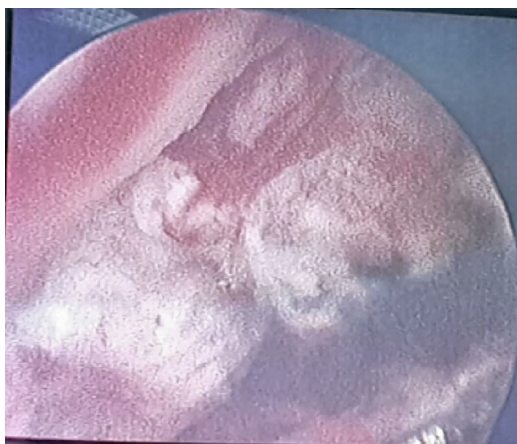
Peer review under responsibility of Pan African Urological Surgeons' Association.

<http://dx.doi.org/10.1016/j.afju.2015.06.004>

1110-5704/© 2015 Pan African Urological Surgeons' Association. Production and hosting by Elsevier B.V. All rights reserved.

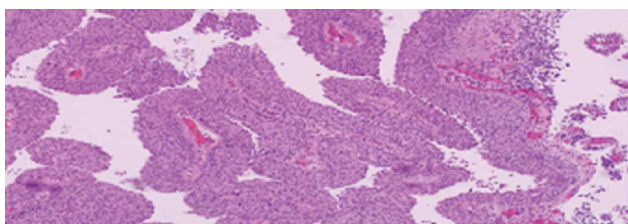


**Figure 1** Multiplanar MRI showing recurrent tumor inside the neobladder.



**Figure 2** Cystoscopic picture of the lesion.

The patient refused to undergo pouchectomy with ileal conduit diversion and preferred to retain her neobladder. Complete transurethral resection of the tumors was performed in two sessions due to their big size and to avoid perforation. The patient was then subjected to postoperative radio-chemotherapy. Postoperative histopathologic examination of the recurrent lesions revealed high-grade invasive TCC (Fig. 3). Follow-up cystoscopy and urine cytology after completion of the adjuvant treatment were performed every 3 months for a year. They revealed absence of any residual lesion and a negative cytology. Upper urinary tract imaging performed at the end of that year showed normal findings. The results



**Figure 3** Histological details of the carcinoma (H&E  $\times 200$ ).

of follow-up investigations including upper urinary tract imaging have been normal since then.

## Discussion

Tumor recurrence after intestinal urinary diversion is not uncommon. However, TCC recurrence or carcinoma in situ (CIS) after radical cystectomy and orthotopic ileal neobladder substitution is extremely rare [4–8]. We herein present a new case of TCC recurrence in an ileal neobladder, diagnosed 18 months after radical cystectomy.

Tumors secondary to urinary diversion using isolated gut segments are mostly adenomas and adenocarcinomas (72.6%), while TCC, squamous cell carcinoma, signet ring cell carcinoma, small cell carcinoma, and leiomyosarcoma altogether represent only 27.4% [9]. The whole urinary tract is at risk of developing new urothelial tumors after treatment of a previous one, as TCC recurrence is either due to field change or implantation [4].

The most common site for recurrence after orthotopic neobladder substitution is the urethra with a reported incidence of 0.7–18% [10]. In our case, the urethra was not affected, as the tumor was located entirely inside the neobladder. Our case also showed the potential of TCC to develop not only in the bladder urothelium, but also in the ileal mucosa of a neobladder as previously described by Herawi and colleagues. They reported urothelial carcinoma recurrence in the peritoneum and on the colonic mucosal surface of a neobladder, which used to be considered unusual sites for recurrence according to the “seed and soil hypothesis” [11].

Although rare, TCC development inside the ileal neobladder should be considered in any patient with a change in voiding habits or hematuria after bladder substitution. The role of conservative surgery in those patients, taking into consideration the patient’s wishes and/or the question, whether the patient is fit for major surgery, should be studied well.

Long-term follow-up of these cases is required to assess the effectiveness of conservative treatment for this uncommon type of recurrent tumor inside the ileal neobladder.

## References

- [1] Stewart M, Hill MJ, Pugh RC. The role of N-nitrosamine in carcinogenesis at the ureterocolic anastomosis. *BJU* 1981;53(2):115–8.
- [2] Fichtner J. Follow-up after urinary diversion. *Urol Int* 1999;63(1):40–5. <http://dx.doi.org/10.1159/000030417>.
- [3] Cakmak O, Tarhan H, Celiuk O, Kucuk U, Ilbey YO. Transitional cell carcinoma in orthotopic ileal neobladder. *Urology* 2014. <http://dx.doi.org/10.1155/2014/218615> (ID 218615).
- [4] Moore CD, Iczkowski KA, Blue KM, Algood CB. Urothelial carcinoma recurrence in ileal orthotopic neobladder: urethrectomy and creation of ileal conduit. *Urology* 2007;69(1):184.e11–3.
- [5] Sánchez Zalabardo D, López Ferrandis J, Arocena García-Tapia J, Sanz Pérez G, Zudaire Bergera J, Berían Polo JM. Recurrent urothelial tumor in orthotopic neobladder. *Actas Urol Esp* 2001;25(8):600–2. [http://dx.doi.org/10.1016/S0210-4806\(01\)72681-2](http://dx.doi.org/10.1016/S0210-4806(01)72681-2).
- [6] Ide H, Kikuchi E, Shinoda K, Mukai M, Murai M. Carcinoma in situ developing in an ileal neobladder. *Urology* 2007;69(3):576.e9–11. <http://dx.doi.org/10.1016/j.urology.2007.01.073>.
- [7] Abad JFB, Eizaguirre ET, Mayans AR, Polo JB. Tumor relapse in orthotopic bladder replacement. A report of two

- cases and literature review. *Actas Urol Esp* 2010;34(3):295–7, <http://dx.doi.org/10.1016/j.acuro.2009.10.002>.
- [8] Hadzi-Djokić J, Pejčić T, Andrejević V, Djurasić L. Transitional cell carcinoma in orthotopic ileal neobladder 12 years after radical cystectomy. *Vojnosanit Pregl* 2013;70(11):1062–4.
- [9] Kälble T, Busse K, Amelung F, Waldherr R, Berger MR, Edler L, et al. Tumor induction and prophylaxis following different forms of intestinal urinary diversion in a rat model. *Urol Res* 1995;23(6):365–70, <http://dx.doi.org/10.1007/BF00698735>.
- [10] Freeman JA, Esrig D, Stein JP, Skinner DG. Management of the patient with bladder cancer: urethral recurrence. *Urol Clin N Am* 1994;21(4):645–51.
- [11] Herawi M, Leppert JT, Thomas GV, de Kernion JB, Epstein JI. Implants of noninvasive papillary urothelial carcinoma in peritoneum and ileocolonic neobladder: support for “seed and soil” hypothesis of bladder recurrence. *Urology* 2006;67(4):746–50, <http://dx.doi.org/10.1016/j.urology.2005.10.023>.