



Pan African Urological Surgeons' Association

African Journal of Urology

www.ees.elsevier.com/afju
www.sciencedirect.com



Case report

An unusual double fungal infection of the bladder due to *Candida* and *Cladosporium*



G.V. KandaSwamy*, B. Viswaroop, A. Elangovan, M. Arul, S.V. Kandasami, G. Gopalakrishnan

Uro-Oncology Fellow, University Hospital of Wales, Cardiff, UK

Received 7 April 2015; received in revised form 16 April 2015; accepted 23 April 2015

KEYWORDS

Fungal cystitis;
Candida;
Cladosporium;
Storage symptoms;
Sterile pyuria;
Contracted bladder;
Reflux;
Duplex kidneys;
Bladder augmentation

Abstract

Fungal cystitis is usually associated with candida species. Most of the cases are asymptomatic and often due to contamination. Following, we describe the case of a young diabetic lady who presented with severe bladder storage symptoms and persistent sterile pyuria. As candida was isolated from the urine, a diagnosis of fungal cystitis was made. Imaging showed a duplex kidney with complete duplication of the ureters on both sides as well as a contracted bladder with small capacity and bilateral grade-3 reflux into the lower-pole moieties. In view of an increasing severity of the symptoms despite an appropriate treatment, it was decided to augment the bladder. The inflamed bladder wall was excised during augmentation. Tissue culture revealed cladosporium.

© 2015 Pan African Urological Surgeons' Association. Production and hosting by Elsevier B.V. All rights reserved.

Introduction

Cladosporium is a dematiaceous (brown-pigmented) mould which is distributed by aerial dissemination of spores and is isolated from decaying food. It contains melanin which gives it its pigmentation. Some species are seen in tropical and subtropical areas

and most do not grow in temperatures below 35 °C [1]. They are rarely pathogenic to humans, but may cause skin lesions, keratitis, onychomycosis, sinusitis and pulmonary infections [2]. Candida infection is synonymous with fungal cystitis, but cladosporium involving the bladder has virtually been unheard of.

Case report

A 37-year-old diabetic female, mother of one child, presented with a history of worsening storage symptoms with occasional hematuria over the past 4 years. She had type-2 diabetes which was well-controlled with oral hypoglycemics. Her HbA1c at presentation was

* Corresponding author at: Uro-Oncology Fellow, University Hospital of Wales, Cardiff, CF14 4XW, UK.

E-mail address: kgvignesh@yahoo.com (G.V. KandaSwamy).

Peer review under responsibility of Pan African Urological Surgeons' Association (PAUSA).

<http://dx.doi.org/10.1016/j.afju.2015.04.005>

1110-5704/© 2015 Pan African Urological Surgeons' Association. Production and hosting by Elsevier B.V. All rights reserved.

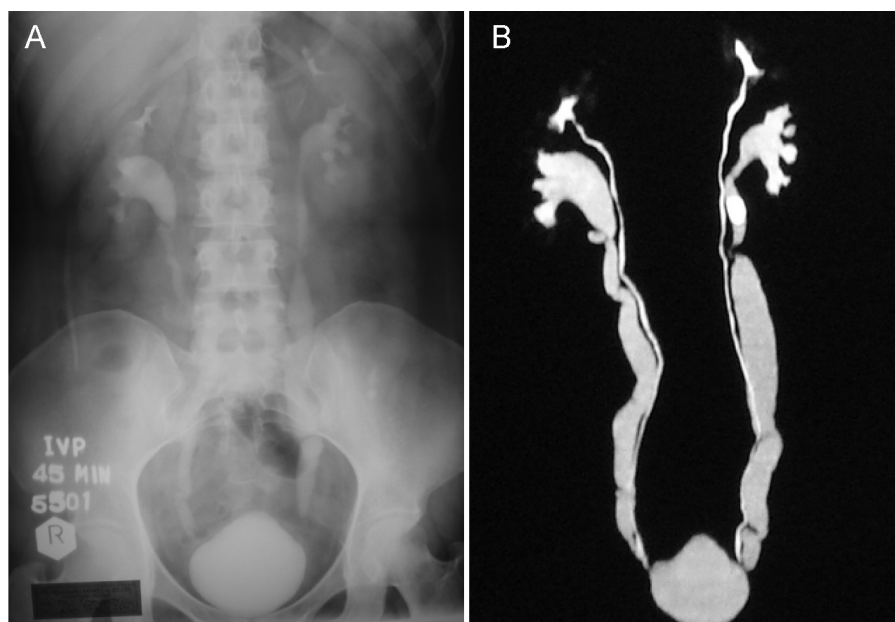


Figure 1 IVP and CT image reconstruction showing filling defect of suspected left upper ureteric stone (A), complete bilateral duplex moiety and a small-capacity bladder (B).

6%. Apart from persistent sterile pyuria, previous examinations elsewhere, including ultrasonography and cystoscopy, had not revealed any other abnormalities. A urine acid-fast bacilli (AFB) culture was negative. Although the patient had never suffered from any documented bacterial or fungal infections, she responded to empirical antibiotics and anticholinergics only in the beginning of the treatment. After a while, the response started to fade away, along with an increase in severity and frequency of the symptoms. Her menstrual cycles were normal.

Upon presentation at our clinic she underwent further investigations. Repeat ultrasound showed a thick-walled, contracted urinary bladder with a duplex kidney and complete duplication of the collecting system of both kidneys, as well as hydronephrosis of the lower-pole moieties. Intravenous pyelography (IVP) confirmed these findings. It revealed normally functioning kidneys and a calculus sized 15 × 10 mm in the upper ureter of the left lower-pole moiety. Micturating cystourethrography (MCUG) showed a bladder with a small capacity (120 ml) and bilateral grade-3 reflux on voiding (Fig. 1A, 2).

Further testing for urine AFB was negative, but fungal culture of the urine revealed candida. After a course of antifungals (fluconazole – 2 weeks), cystoscopy was done which showed a congested small-capacity bladder with glomerulations. Biopsies showed a metaplastic acanthotic squamous mucosa with necrosis and exudates. Tissue culture for fungus showed candida which was resistant to all antifungals (fluconazole, itraconazole and amphotericin B). The bladder diary kept by the patient showed a decrease in the maximum voided volume, by this time to 50 ml.

In view of the increasing severity of the symptoms, it was decided to augment the bladder. Contrast-enhanced computed tomography (CECT) prior to the procedure confirmed the IVP findings and also showed extensive urinary bladder wall thickening with perivesical stranding. At surgery, extensive perivesical adhesions were seen.

The bladder was very thick-walled with an edematous and inflamed mucosa. A generous amount of this inflamed bladder wall was excised in the hope of relieving the symptoms and was sent for tissue histology and both fungal and AFB cultures. The stone was treated endoscopically at the same time. Bladder histology showed ulceration and a severe degree of chronic non-specific cystitis, but

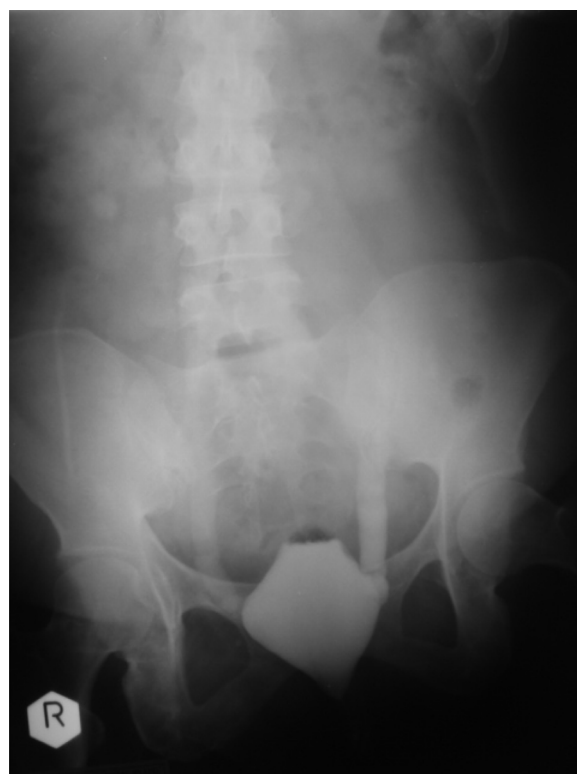

Figure 2 MCUG showing grade III reflux.

no fungal hyphae in the bladder wall. The excised bladder tissue, though negative for AFB in the cultures, grew cladosporium on a further fungal culture.

The patient's postoperative course was uneventful and she has remained symptom-free for the last five years. Regular reviews of her bladder diary show a stable functional volume of 350 ml. She has no pain or bothersome symptoms of postvoid residual urine. Her urine has remained sterile, with cultures showing leucocytes (post augmentation) but no fungal or bacterial colonies. The patient voids without any difficulty, and upper tract dilatation has resolved as proved by ultrasound.

Discussion

Apart from microscopic identification, a colony count of 10,000–15,000 cfu/ml is the suggested cut-off value for the diagnosis of fungal urinary infection. However, a positive culture of any colony count needs evaluation. Fungal infections of the genitourinary tract commonly occur in immunosuppressive states or as part of a disseminated disease and are associated with predisposing factors like indwelling catheters, antimicrobial therapy, diabetes mellitus and hospitalization.

There is evidence of an increased incidence of asymptomatic bacteriuria in diabetic women, a two-fold increase in funguria, especially candida, in diabetics in general and a sixfold increase of both with antibiotic use [3]. The incidence of symptomatic urinary tract infection is also high in diabetic women which has led some authors to suggest a routine search for yeast in the urine of diabetic patients in order to detect candidiasis, and to perform antifungal susceptibility tests for the detection of candida isolates [4].

The mode of infection of the urinary tract by candida is well documented. Lower tract involvement occurs due to retrograde infection, while renal parenchymal infection is hematogenous [5]. Since cladosporium is spread by dissemination of spores, an involvement of the bladder postulates a new hypothesis. It could be part of a disseminated systemic infection involving the bladder or a retrograde or ascending infection or a spread by modes other than airborne dissemination. Infection of the upper tract by cladosporium has never been reported before, and the only association described is that of isolation of specific antibodies to cladosporium, apart from many other fungi, in a case of eosinophilic food-induced cystitis [6].

Our patient had chronic interstitial cystitis with squamous metaplasia with necrosis and exudates, resulting in a small-capacity bladder with bilateral secondary VUR. The cause of this is unknown. She is a healthy individual with fairly well-controlled diabetes and a long duration of urinary symptoms who underwent on and off treatment

for vaginal candidiasis in the past. Whether the repeated courses of various antimicrobials given empirically for relief of her urinary symptoms had led to fungal infection of the bladder is not clear. No significant association between the histologic features and candida infection has been reported in the literature which raises the possibility that cladosporium might behave aggressively when it infects the bladder.

Since two different fungal organisms were isolated in the two different cultures, the possibility of concomitant infection, which has been described before, or a change of the colonising organism cannot be ruled out. It may also be argued that a more common pathogenic organism is likely to have caused the events, in this case candida, with the possibility of secondary concomitant infection with cladosporium. One should also note that contamination is more likely in body fluids than it is in tissue. Cladosporium may also have been introduced during the initial bladder biopsy which would indicate a iatrogenic infection.

This case is reported not just for its rarity. It reiterates the importance of considering fungal cystitis in patients with persistent sterile pyuria with chronic and, especially, with worsening urinary symptoms, irrespective of the immunologic status. It also reiterates the importance of CECT in evaluating complex cases to give more anatomical details and reveal possible functional changes of the genitourinary tract.

Conflict of interest

The authors declare that there is no conflict of interest.

References

- [1] Dixon DM, Polak-Wyss A. The medically important dematiaceous fungi and their identification. *Mycoses* 1991;34(January–February (1–2)):1–18.
- [2] Collier L, Balows A, Sussman M. Topley & Wilson's microbiology and microbial infections, vol. 4, 9th ed. London, Sydney, Auckland, New York: Arnold; 1998.
- [3] Guler S, Ural O, Findik D, Arslan U. Risk factors for nosocomial candiduria. *Saudi Med J* 2006;27(November (11)):1706–10.
- [4] Manzano-Gayosso P, Hernández-Hernández F, Zavala-Velásquez N, et al. Candiduria in type 2 diabetes mellitus patients and its clinical significance. *Candida spp. antifungal susceptibility. Rev Med Inst Mex Seguro Soc* 2008;46(November–December (6)):603–10.
- [5] Fisher JF, Chew WH, Shadomy S, Duma RJ, Mayhall CG, House WC. Urinary tract infections due to *Candida albicans*. *Rev Infect Dis* 1982;4(November–December (6)):1107–18.
- [6] Sánchez Palacios A, Quintero de Juana A, Martínez Sagarra J, Aparicio Duque R. Eosinophilic food-induced cystitis. *Allergol Immunopathol (Madr)* 1984;12(November–December (6)):463–9.